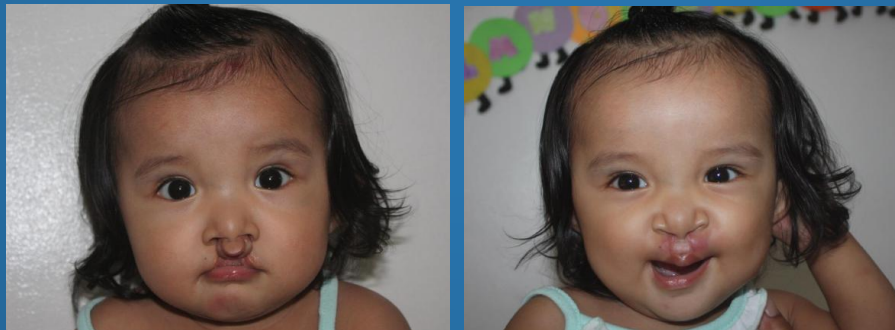



LEADERSPROJECT
TEACHERS COLLEGE • COLUMBIA UNIVERSITY

Cleft Palate Speech and Feeding

Train the Trainer

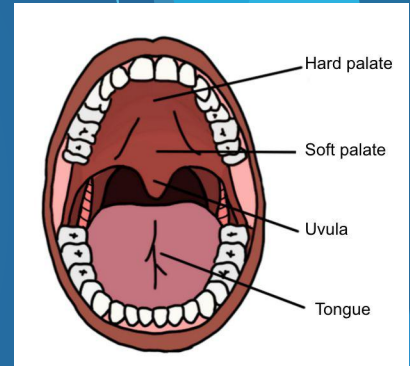




LEADERSPROJECT
TEACHERS COLLEGE • COLUMBIA UNIVERSITY

Module 1.1:

- Anatomy & Physiology
- Why is Speech Therapy Important?
- Embryological Development



Written by:

Catherine (Cate) J. Crowley, J.D., Ph.D., CCC-SLP

Miriam Baigorri Ph.D., CCC-SLP

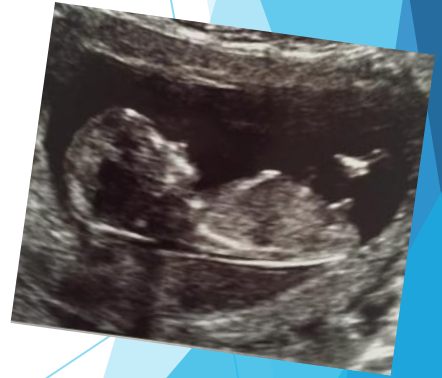Chelsea Sommer M.S., CF-SLP

With contributions by:

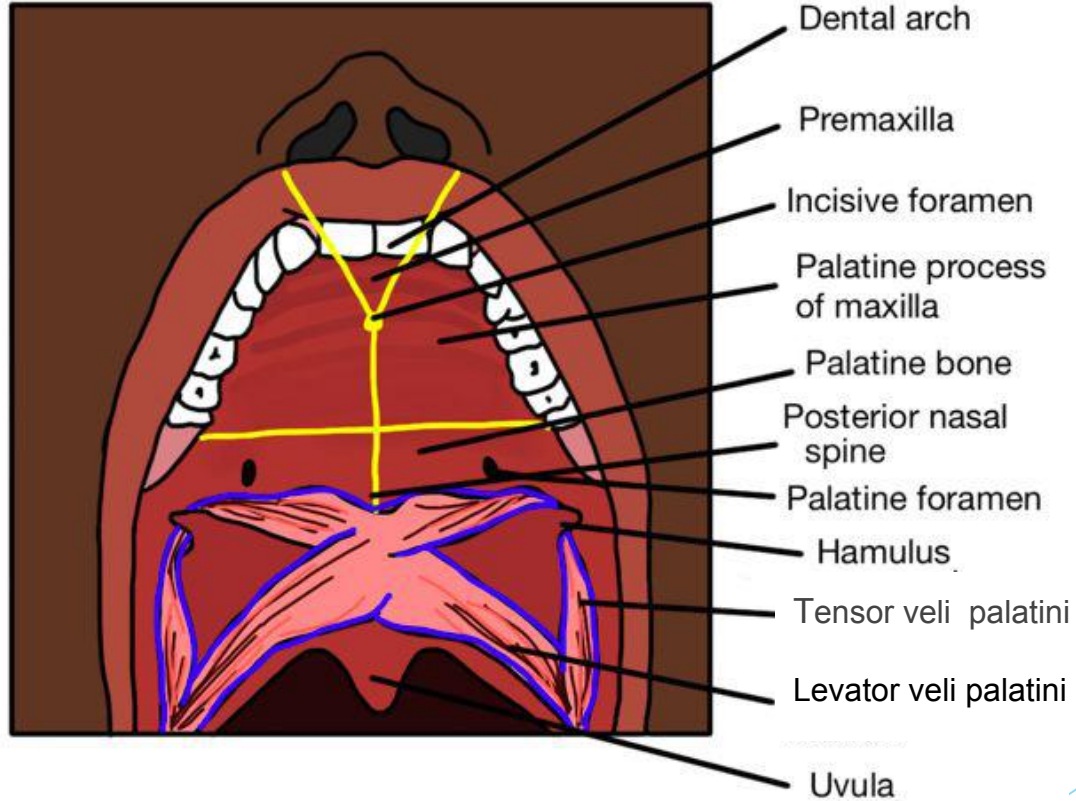
Casey Sheren, Sara Horne, Marcos Sastre, Grace Frutos, & Julie Smith

Typical Embryological Development

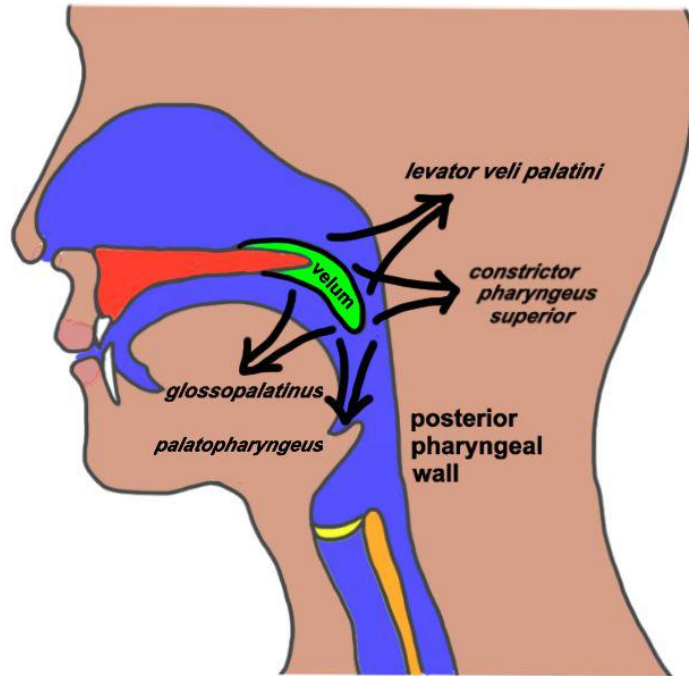
- **Lips and alveolus**
 - Begins around 6-7 weeks of gestation
 - Starts at incisive foramen
- **Hard palate**
 - Begins at 8-9 weeks of gestation
- **Velum and uvula**
 - Complete at 12 weeks of gestation



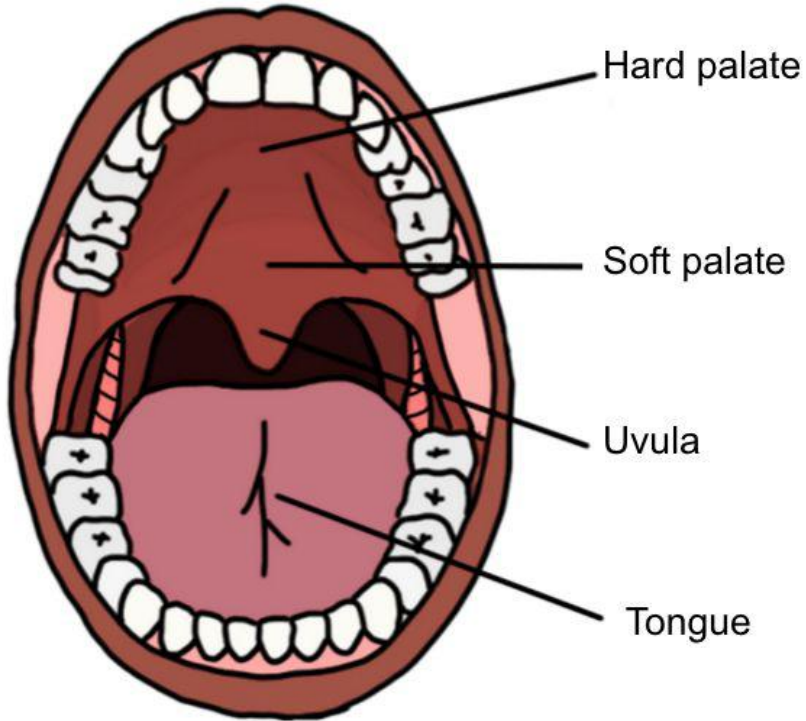
What does typical anatomy of the oral structures look like?



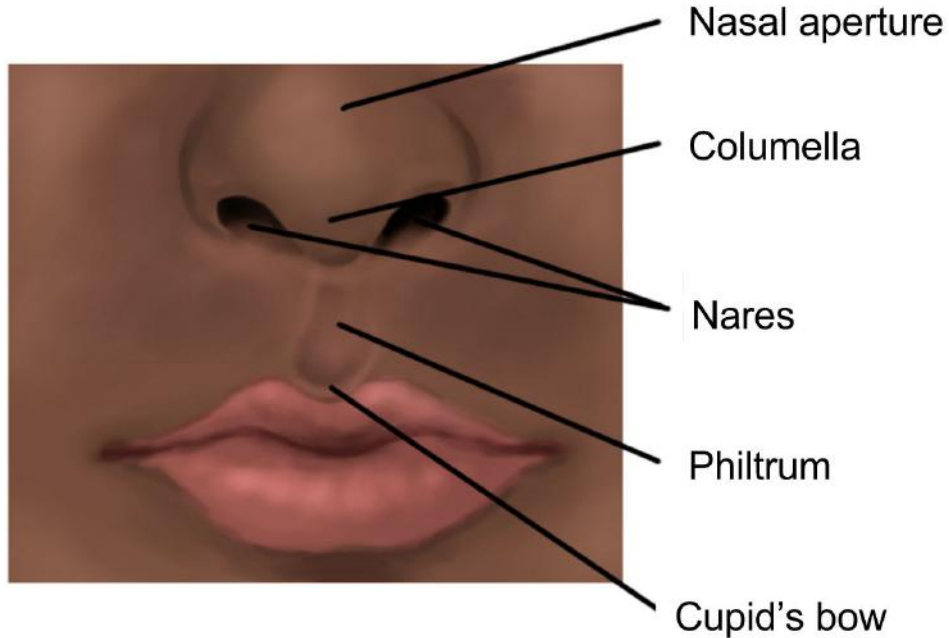
An illustration of the muscles involved in velopharyngeal closure



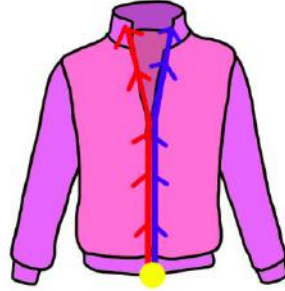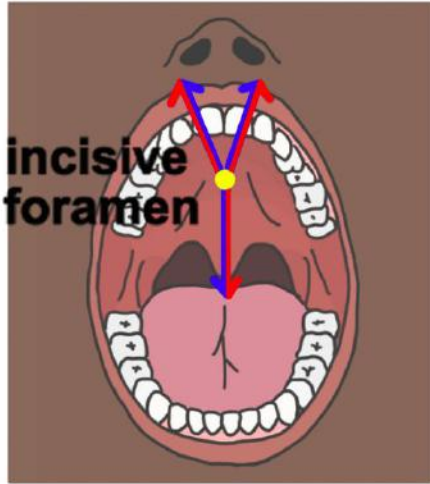
What does typical anatomy of the oral structures look like?



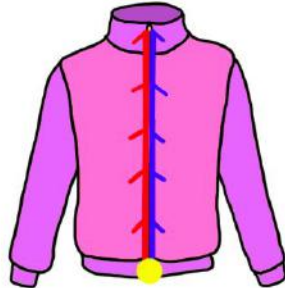What does typical anatomy of the oral structures look like?



How do the oral structures develop?



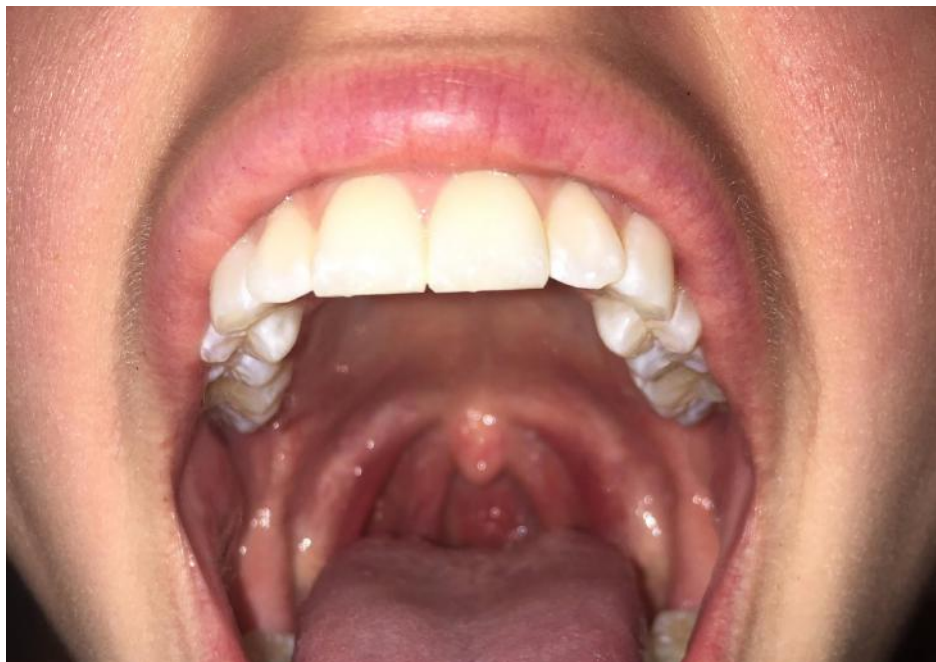An analogy for the development of a cleft



An analogy for typical development

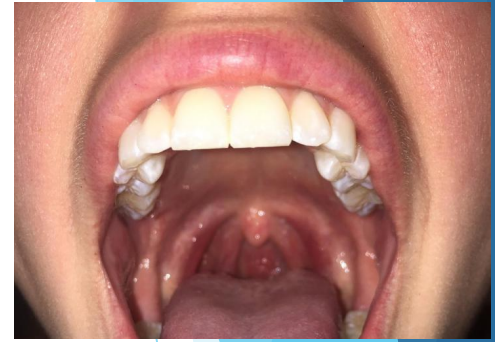The incisive foramen is a point of embryological development. From this location the premaxilla closes on the right side and left side forward to the lip. The palate then closes from the incisive foramen back to the uvula. When one point of development does not close, this results in the cleft.

Typical hard and soft palate





Your turn!



Turn to your partner and, with a flashlight, examine his/her oral structures.

Check the color of the oral tissues, and be sure to identify the:

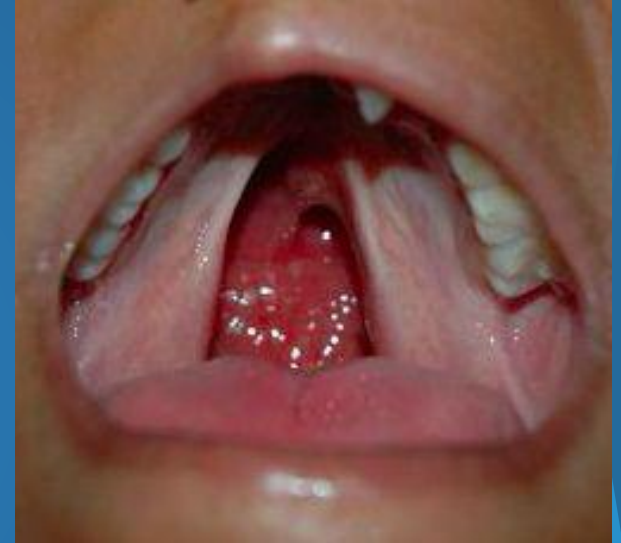- Hard palate
- Soft palate
- Uvula



LEADERSPROJECT
TEACHERS COLLEGE • COLUMBIA UNIVERSITY

Module 1.2:

- **Anatomy & Physiology of Different Types of Clefts**



Written by:

Catherine (Cate) J. Crowley, J.D., Ph.D., CCC-SLP

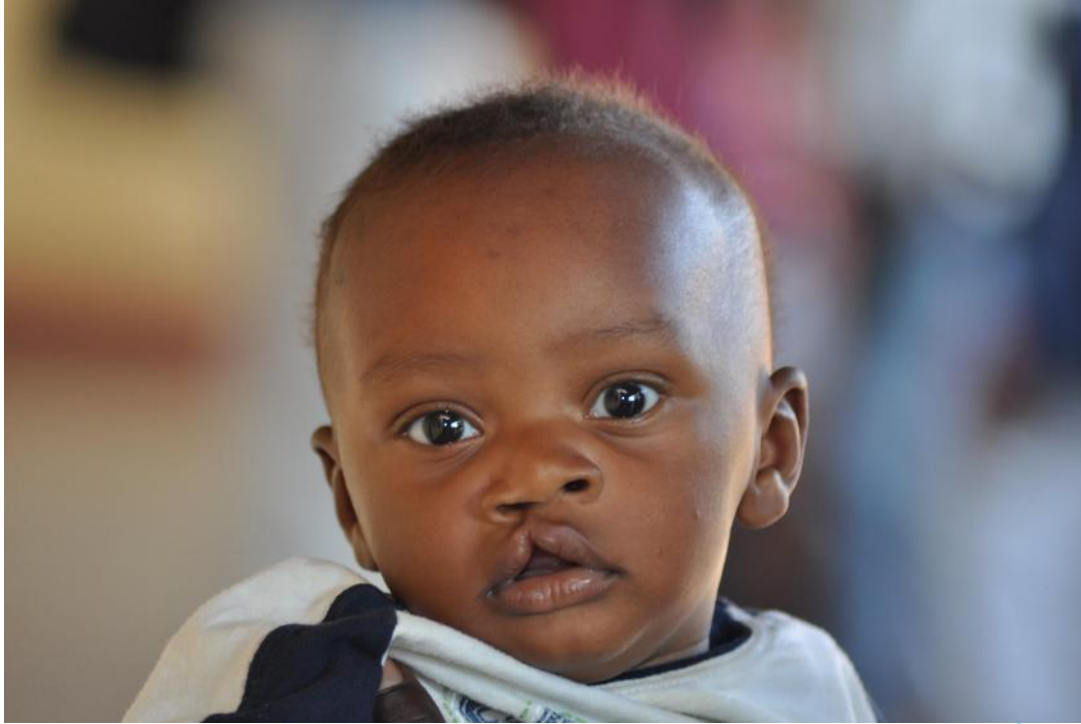Miriam Baigorri Ph.D., CCC-SLP

Chelsea Sommer M.S., CF-SLP

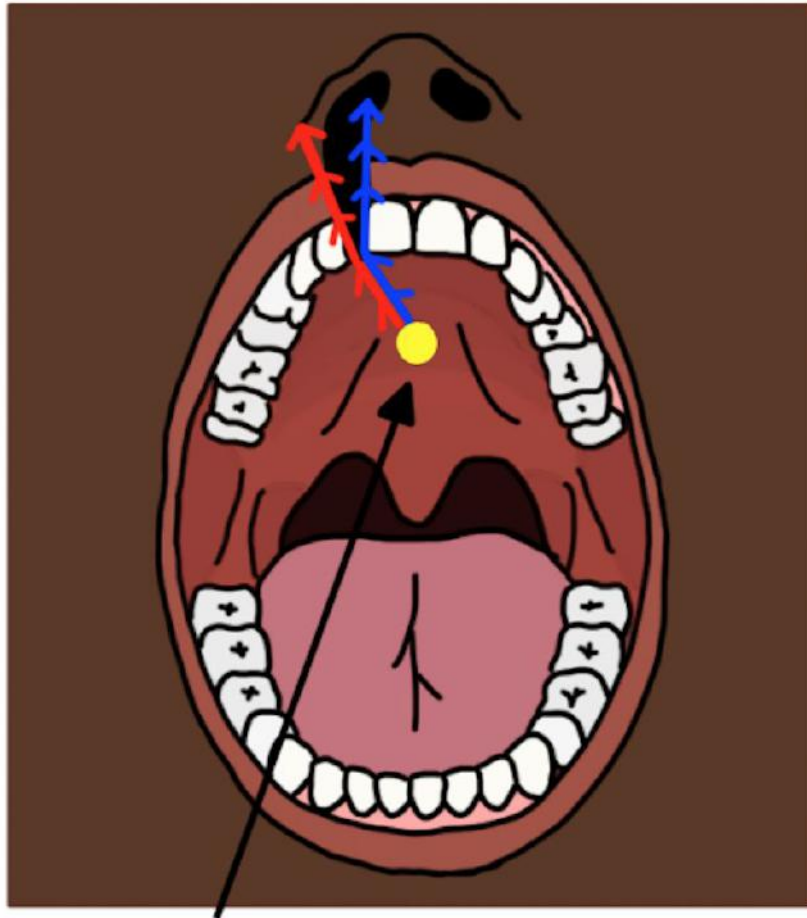
With contributions by:

Casey Sheren, Sara Horne, Marcos Sastre, Grace Frutos, & Julie Smith

Unilateral Cleft Lip




Mugisha, a child with a unilateral cleft lip from Rwanda.

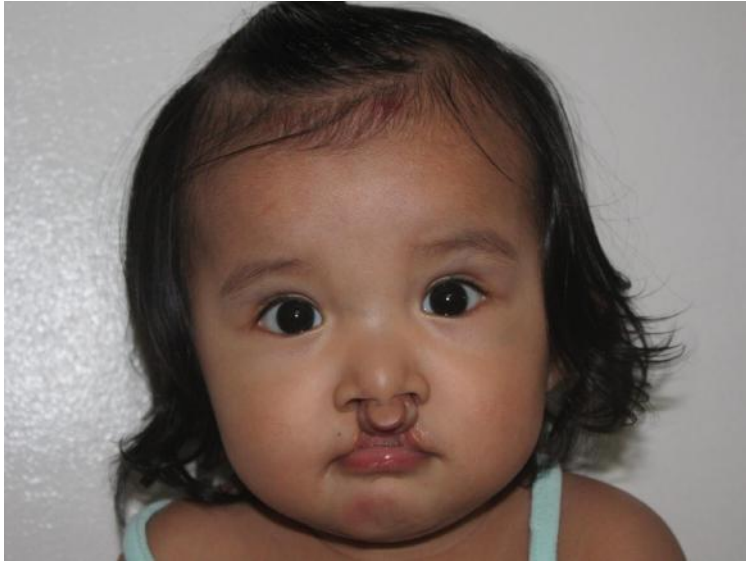

Incisive Foramen

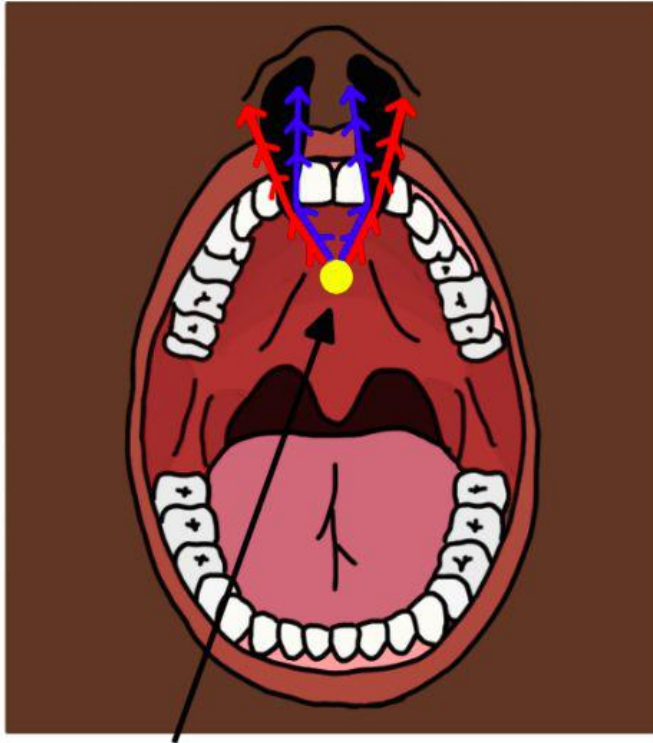
This photo shows that the lip did not finish closing, resulting in a right complete unilateral cleft of the lip. It is complete because it extends into the nostril/nares.



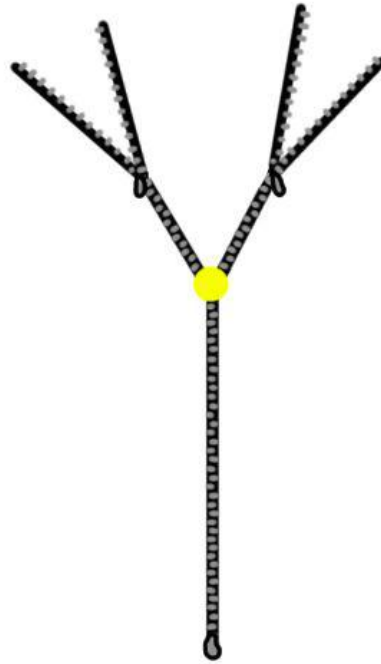Bilateral Cleft Lip



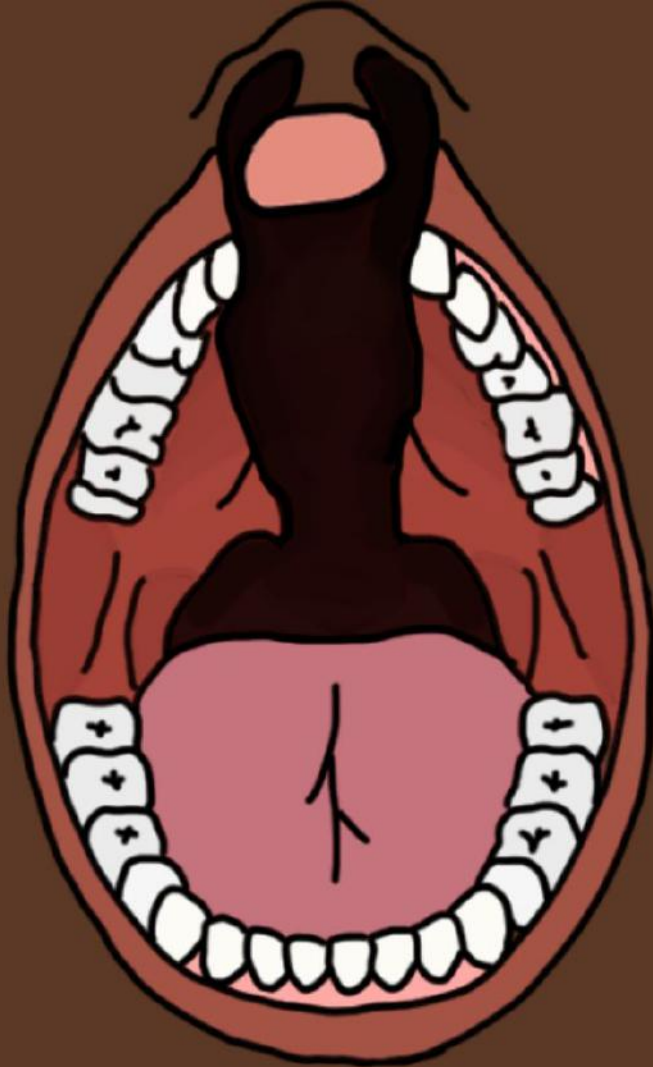Andrea, a child with a bilateral cleft lip. Before and after surgery.



Incisive Foramen

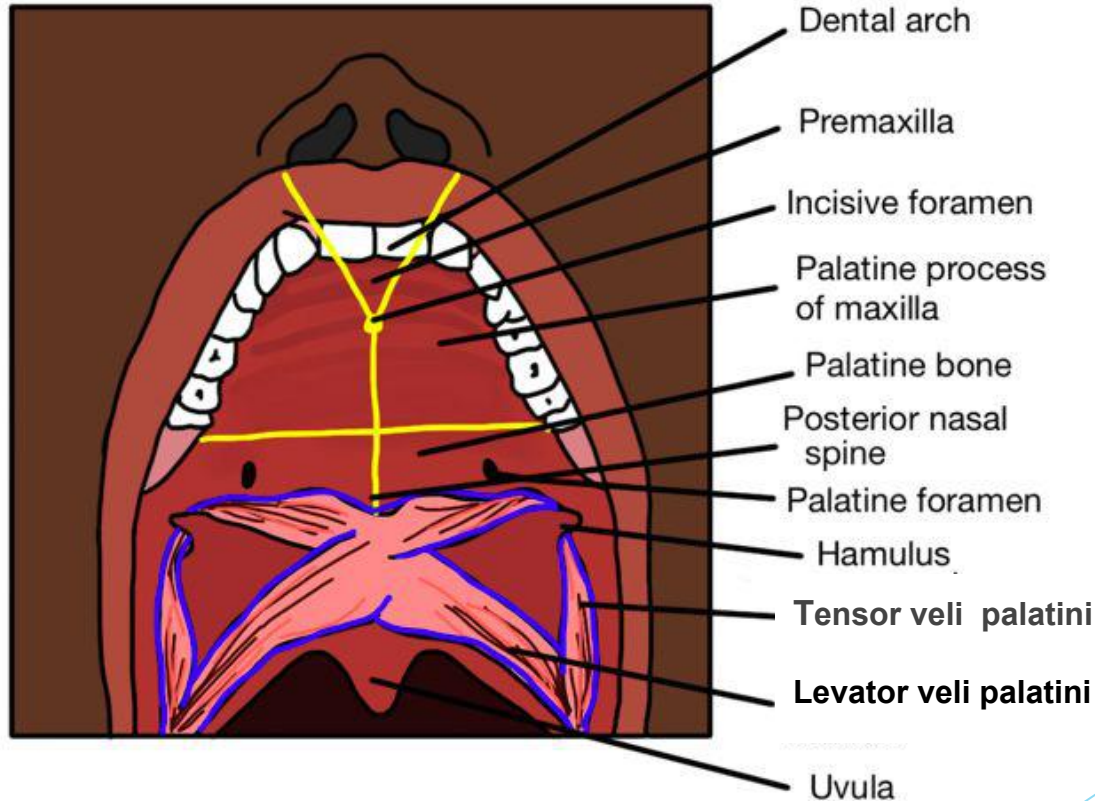


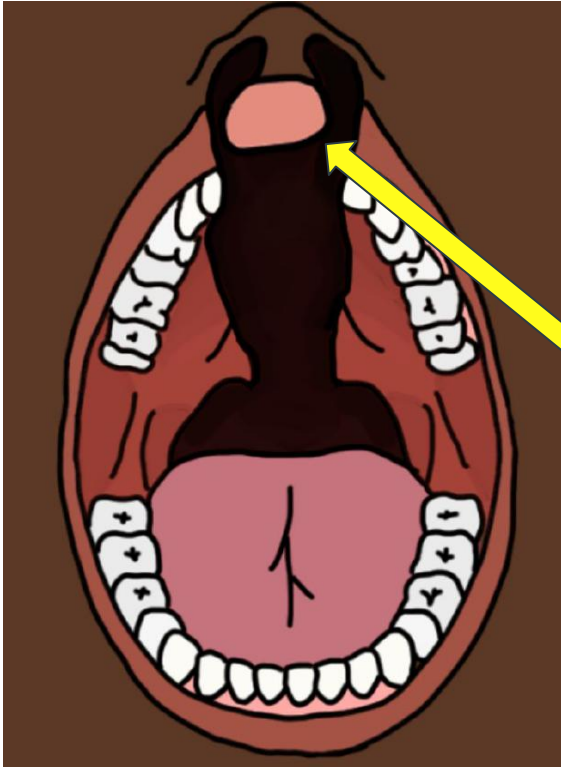
Here we see that both sides did not close, resulting in this bilateral complete cleft of the lip.



One can have both a bilateral complete cleft of the lip and a cleft of the palate as well, meaning that during embryological development no closure occurred.

What does typical anatomy of the oral structures look like?

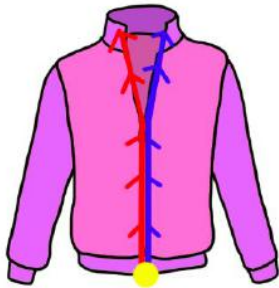



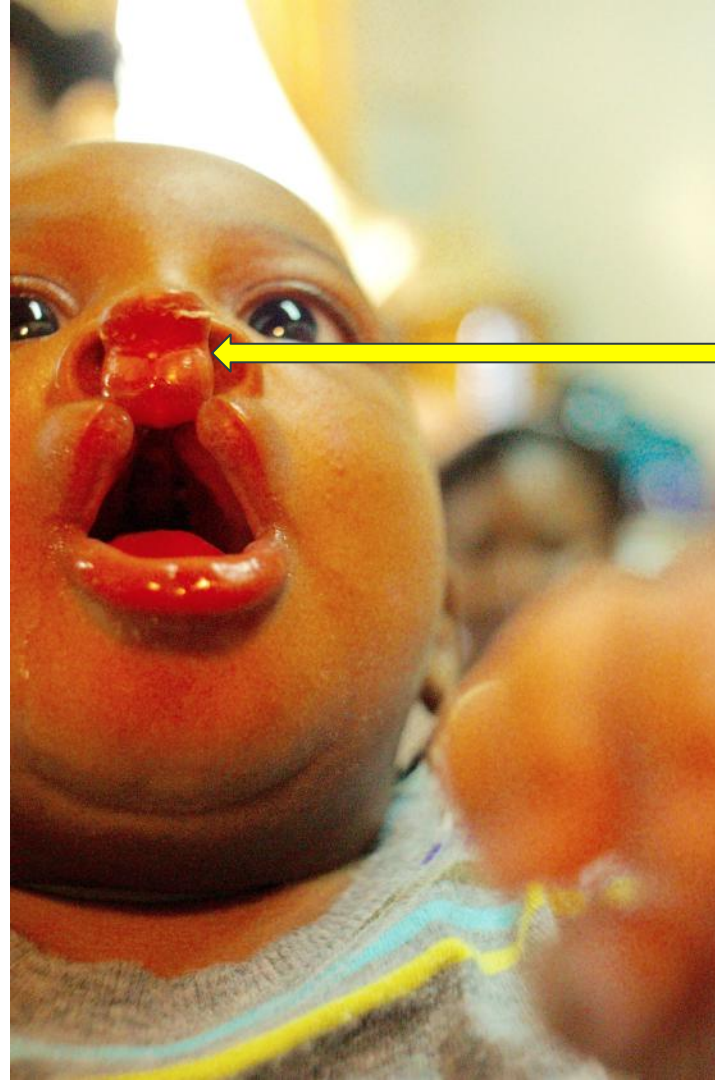
Premaxilla

Here we see that the premaxilla is protruded, which typically contains teeth buds.

The bulging premaxilla results from incomplete closure of the seams anterior to the incisive foramen. If the seams had closed during development, the premaxilla would be correctly placed.



An analogy for the development of a cleft



Premaxilla

Types of Cleft Lip Deformities

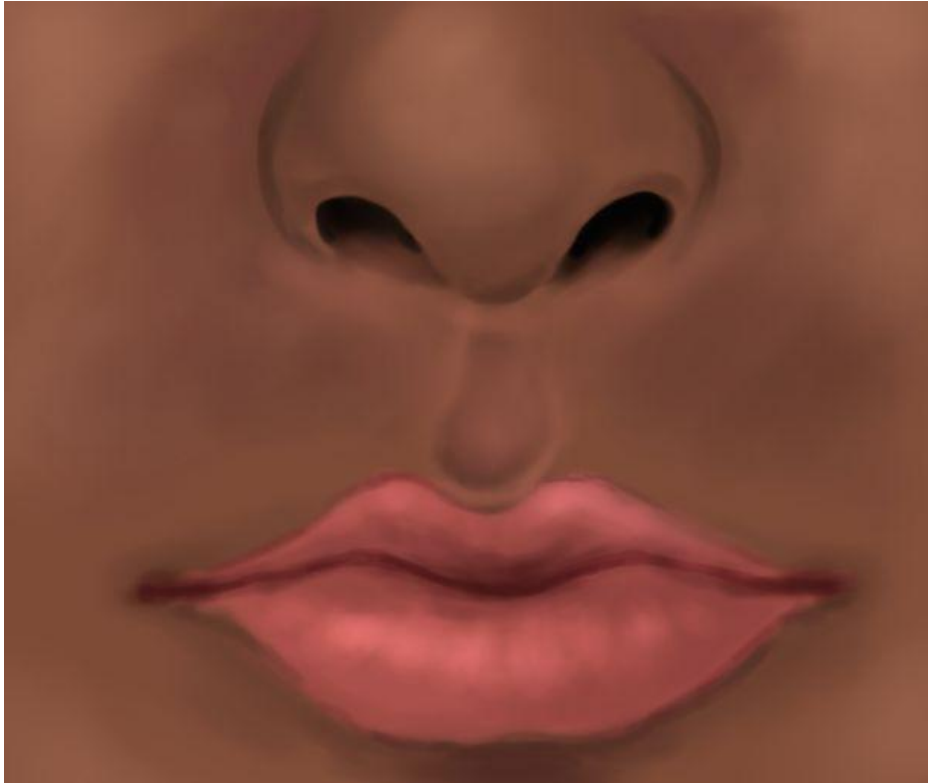- ❖ Unilateral (one side)
- ❖ Bilateral (two sides)
- ❖ Complete (cleft to the nose)
- ❖ Incomplete (Only a cleft of the lip. The nose is not impacted)

Clinical Questions

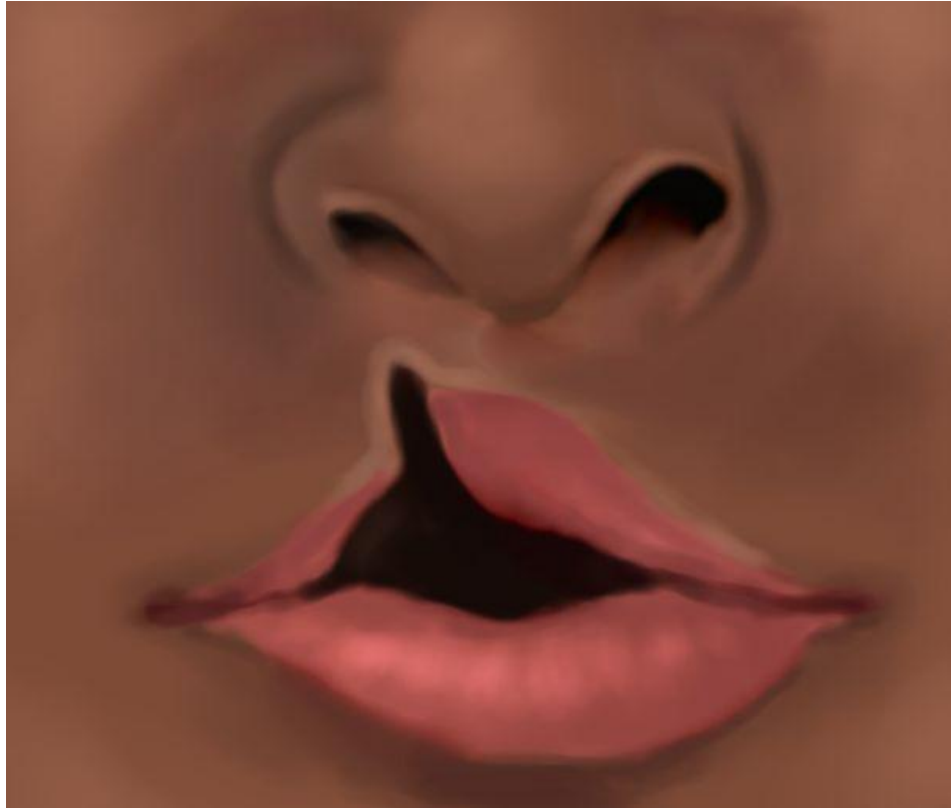Ask yourself: Is one side affected, or both?
(Unilateral or bilateral)

Ask yourself: Does the cleft go up to the nose?
(Complete or incomplete)

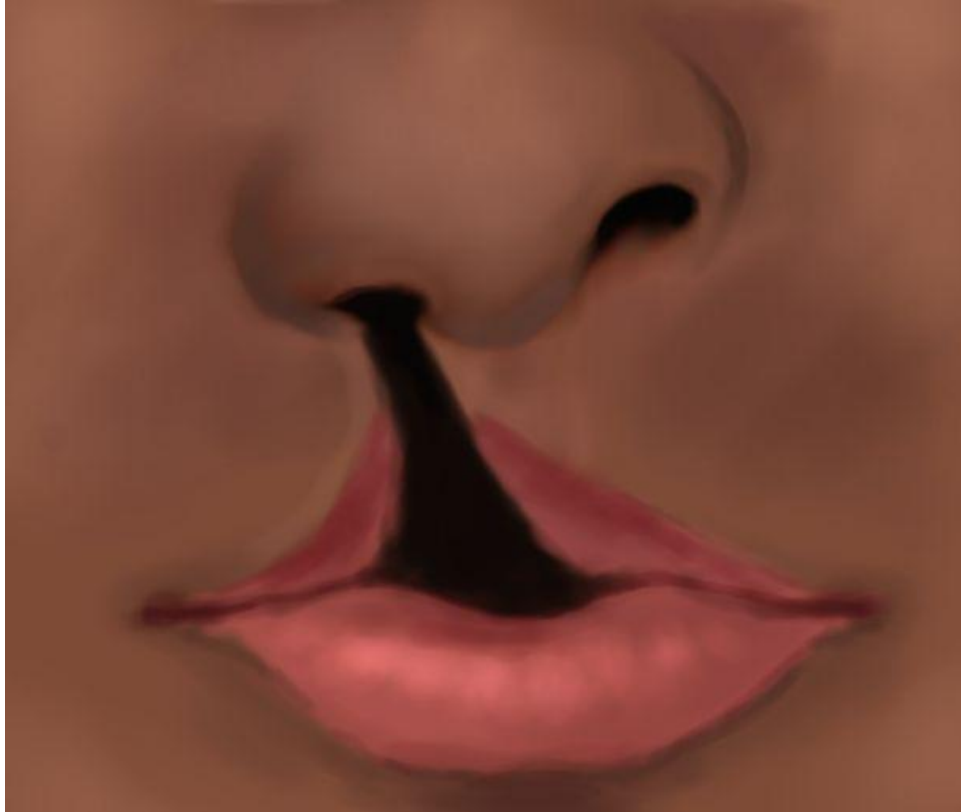Typical Facial Anatomy



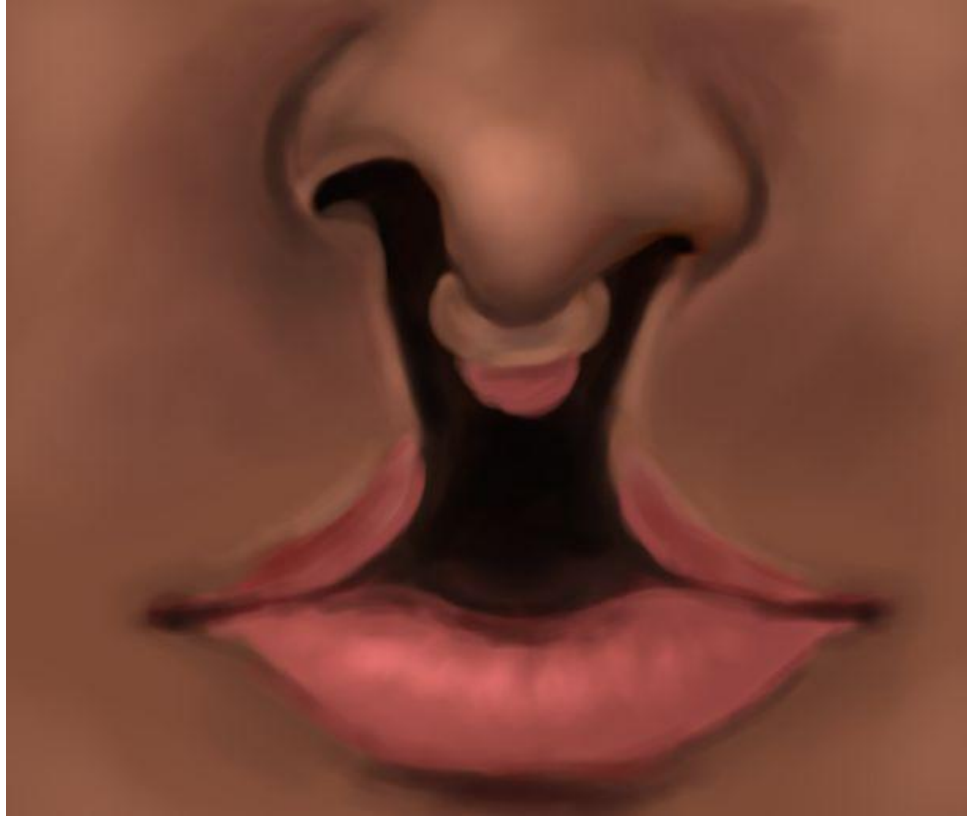
Unilateral Incomplete Cleft Lip



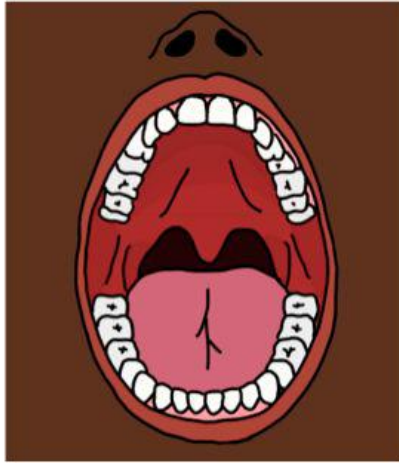
Unilateral Complete Cleft Lip



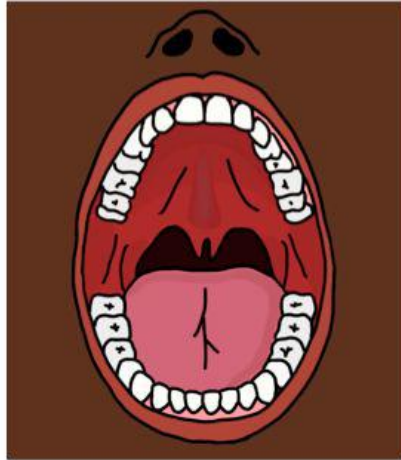
Bilateral Complete Cleft Lip



Cleft Palate Classification

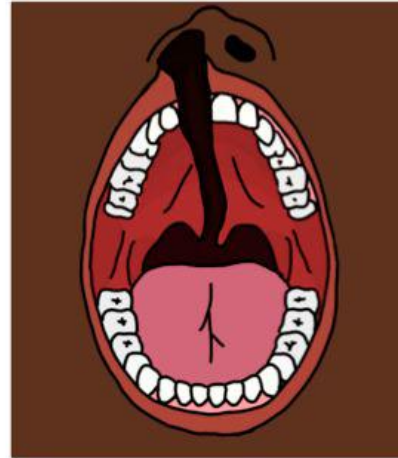

Normal Palate

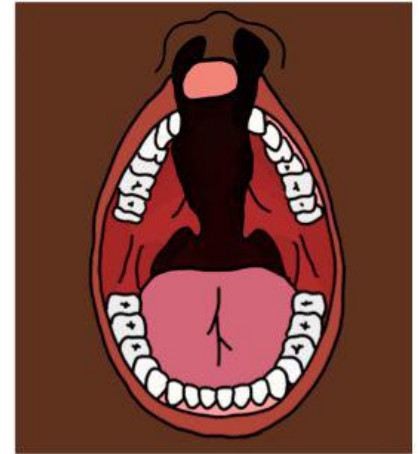


**Submucous
Cleft**

↑
We will discuss
this later!



**Unilateral
Complete**

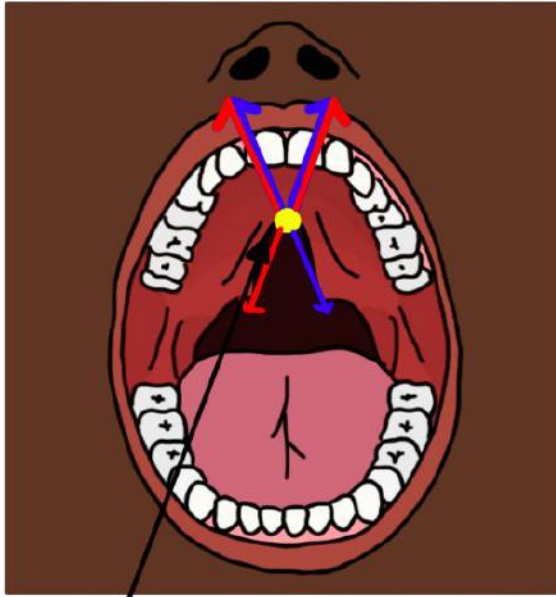


**Bilateral
Complete**



Your turn!

Turn to your partner and discuss:
What happened during embryological development that would result in this kind of a cleft?

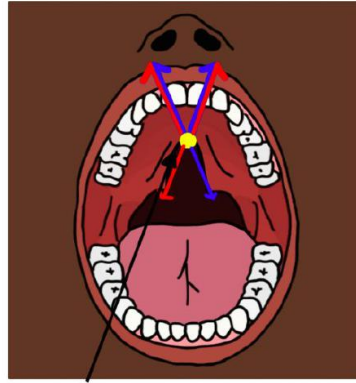


Incisive Foramen





ANSWER



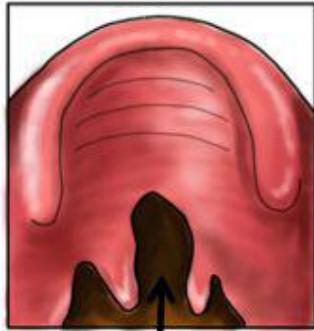
Incisive Foramen



This is a cleft of the hard palate. It formed during embryological development due to an interruption to closure of the palate from the incisive foramen back to the uvula.

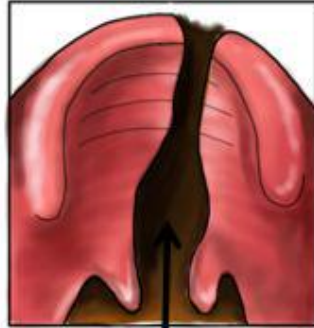
Anatomical Variations in Cleft Palate

**Cleft of Soft
Palate**



cleft

**Cleft of Hard
and Soft Palate**
(& left unilateral cleft lip)



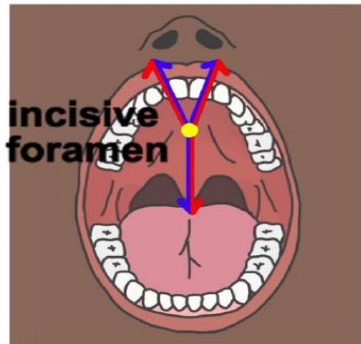
cleft

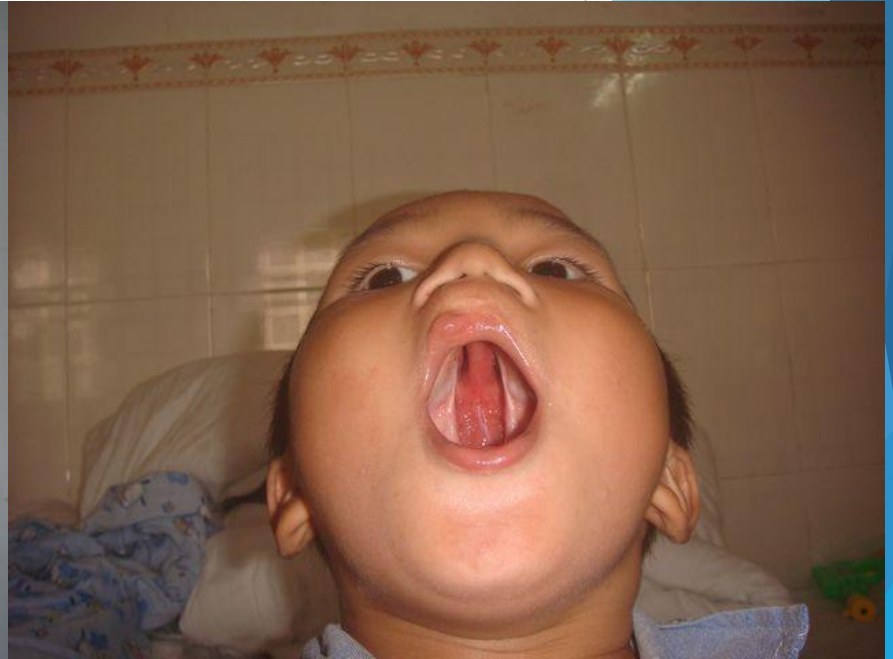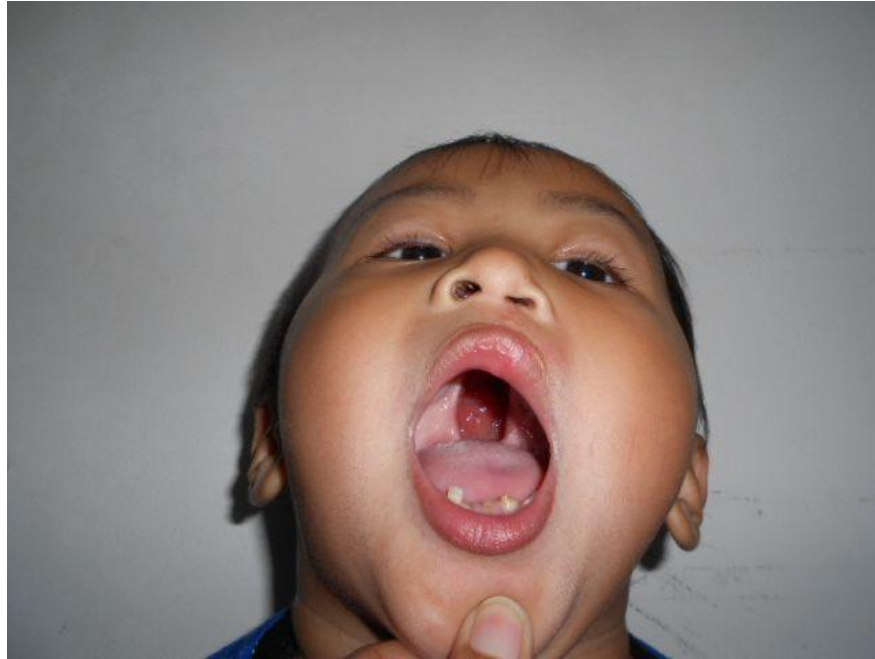We can see a cleft of just the soft palate (left) or a cleft of the hard and soft palate (right), depending on the point at which development is interrupted.

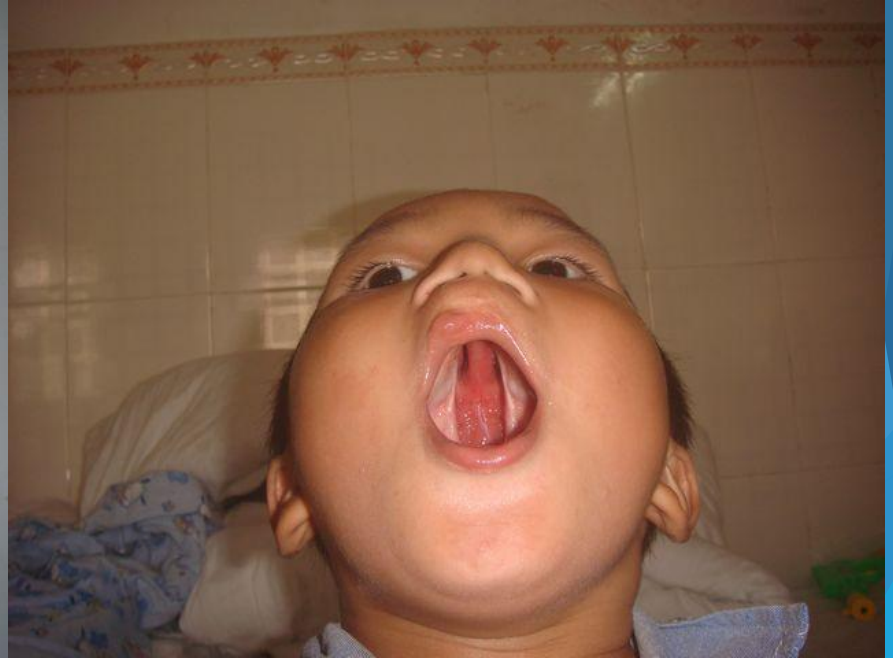
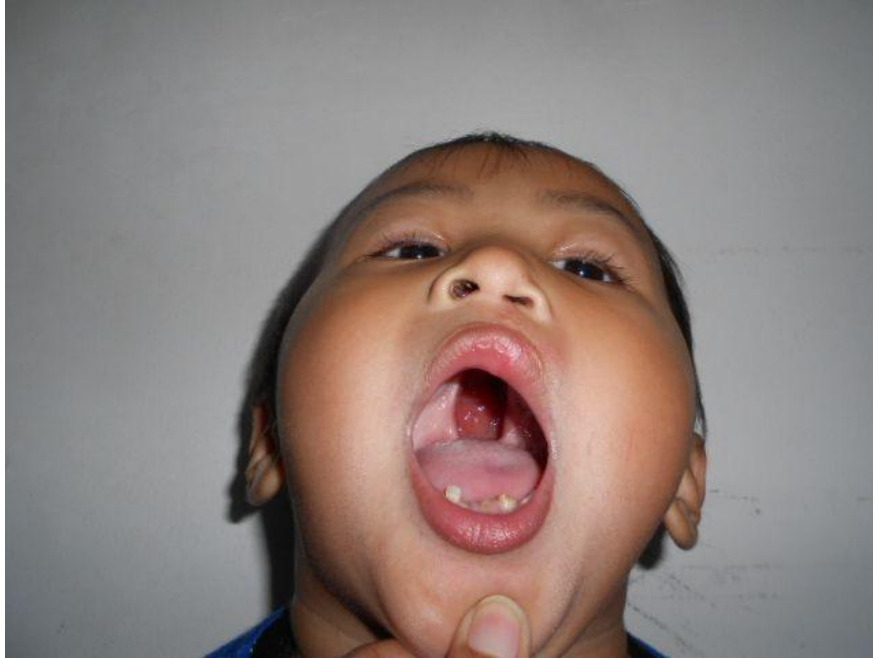
Your turn!

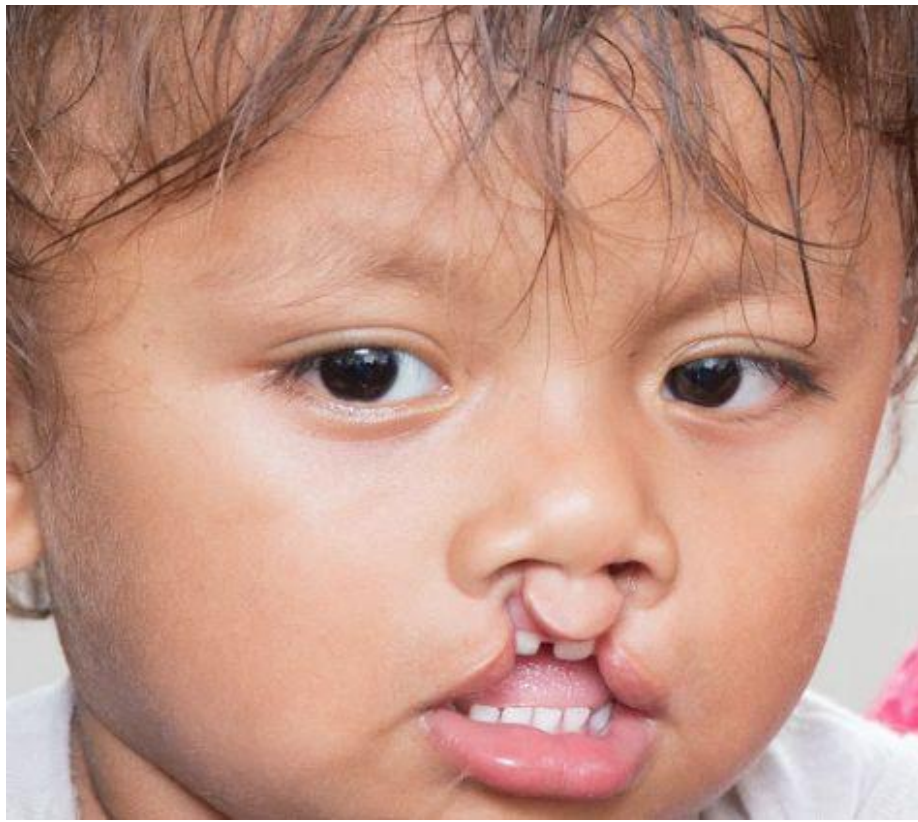Describe the type of cleft you see in the following photos and think about why this might have occurred during development.

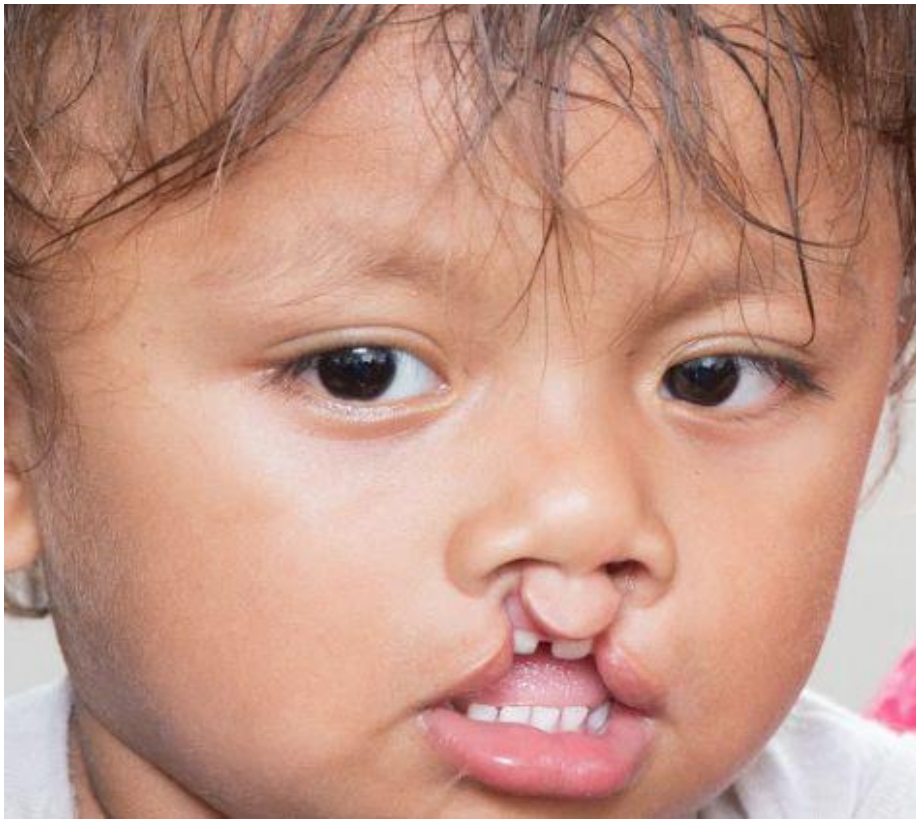




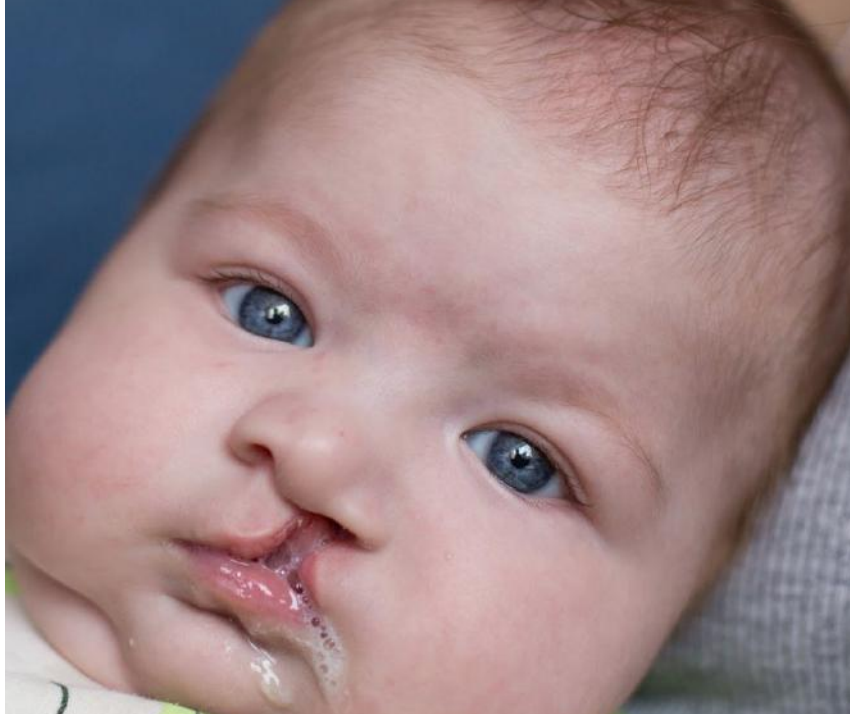
Answer: Cleft of the hard and soft palate



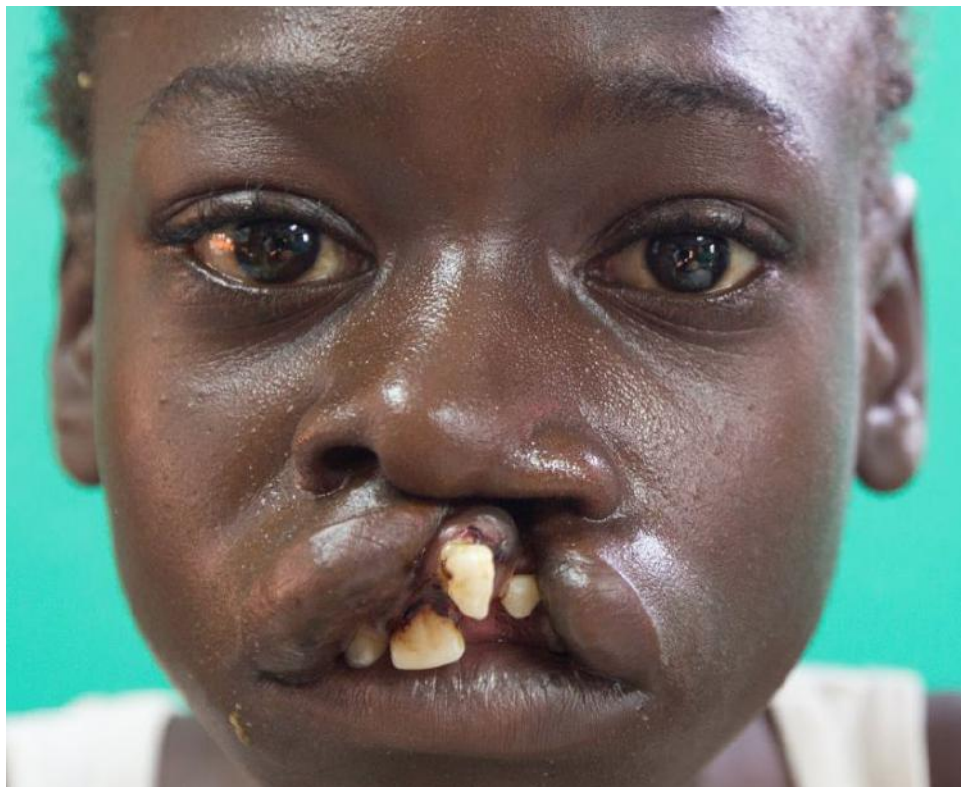


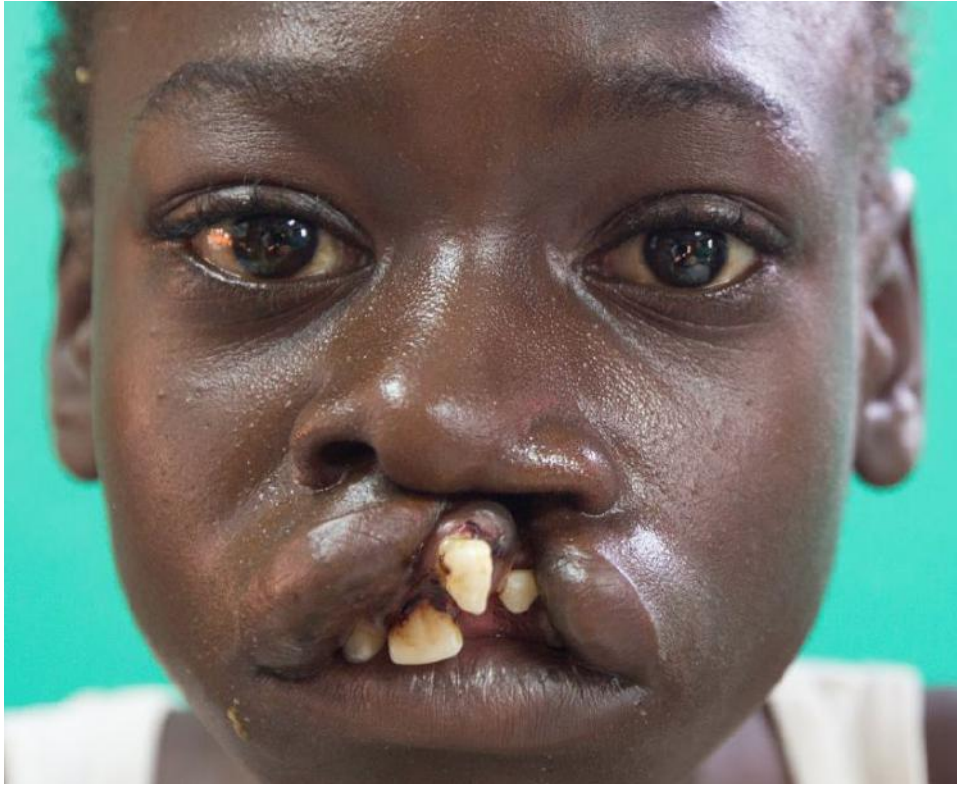Answer: Bilateral cleft of the lip with bulging premaxilla





Answer: Left unilateral complete cleft of the lip





Answer: Unilateral complete cleft lip with a bulging premaxilla and erupted tooth



LEADERSPROJECT
TEACHERS COLLEGE • COLUMBIA UNIVERSITY

Module 1.3:

- **Submucous and Occult Clefts**

Written by:

Catherine (Cate) J. Crowley, J.D., Ph.D., CCC-SLP

Miriam Baigorri Ph.D., CCC-SLP

Chelsea Sommer M.S., CF-SLP

With contributions by:

Casey Sheren, Sara Horne, Marcos Sastre, Grace Frutos, & Julie Smith



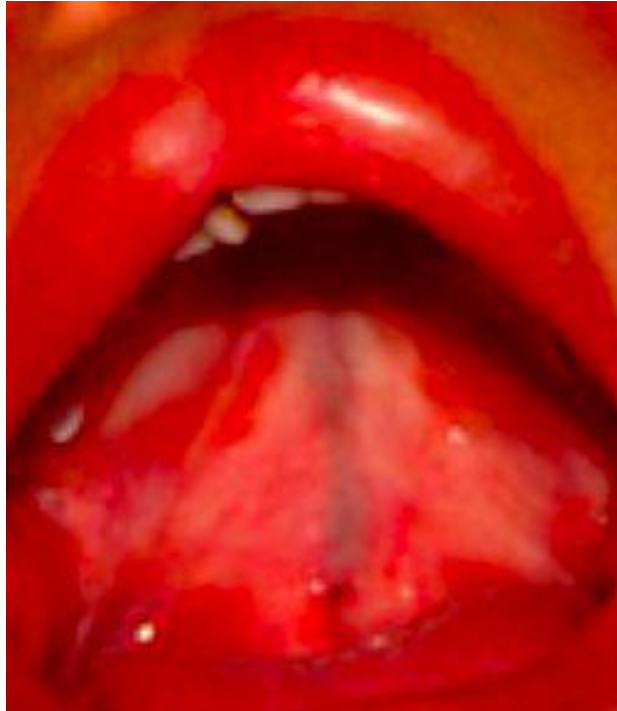Three characteristics of a submucous cleft

- Bifid uvula
- Zona pellucida
- Notch in posterior border of the hard palate

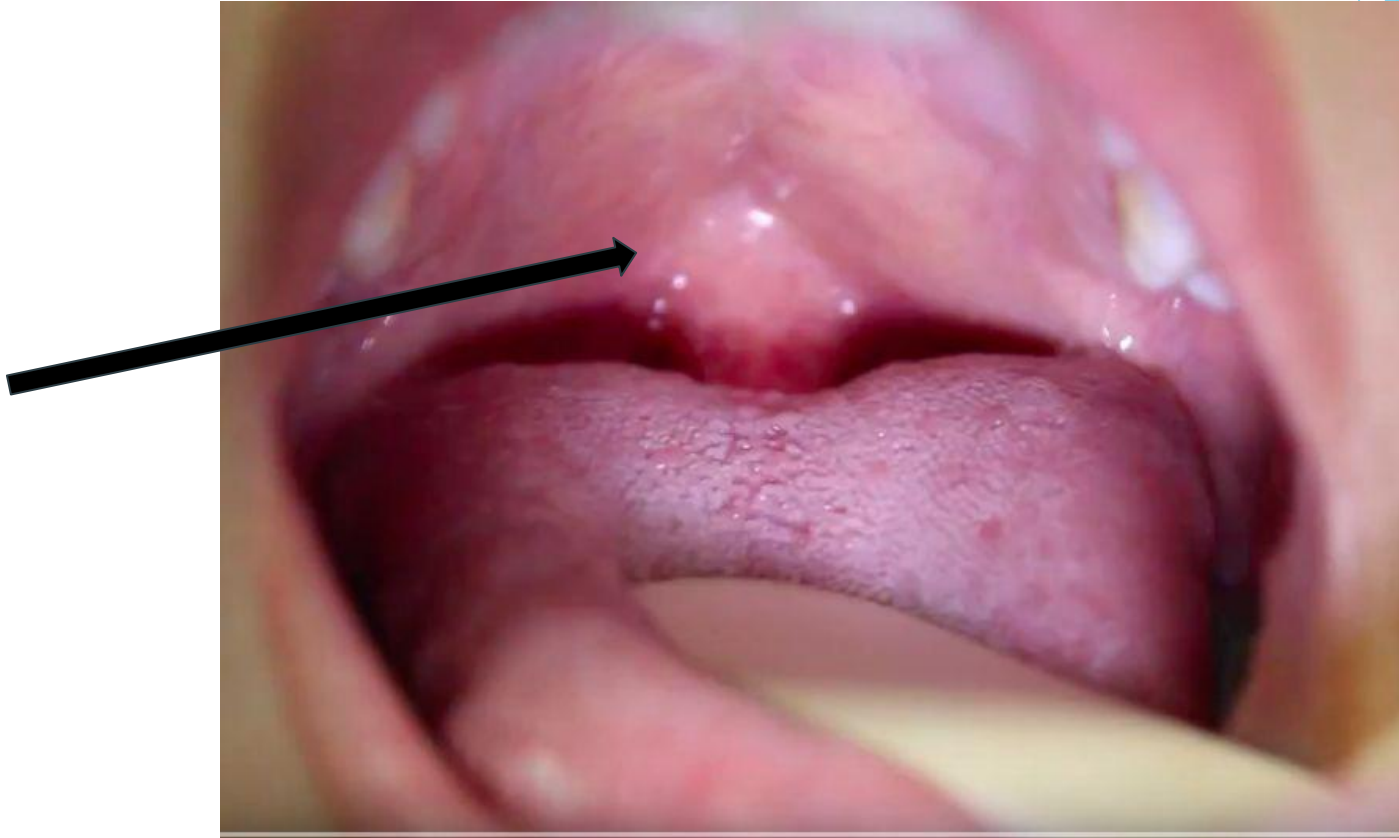
Submucous Cleft

- **Zona pellucida**
- Bluish area in the middle of the velum.
 - Bluish coloring
 - Caused by thin mucosa
 - Lack of normal underlying muscle mass
- Velum may appear to be in an inverted “V”, especially during phonation.
 - “V” shape
 - Abnormal insertion of the veli palatini muscles in the posterior section of the hard palate
 - With phonation, velum appears to “tent up” toward hard palate.

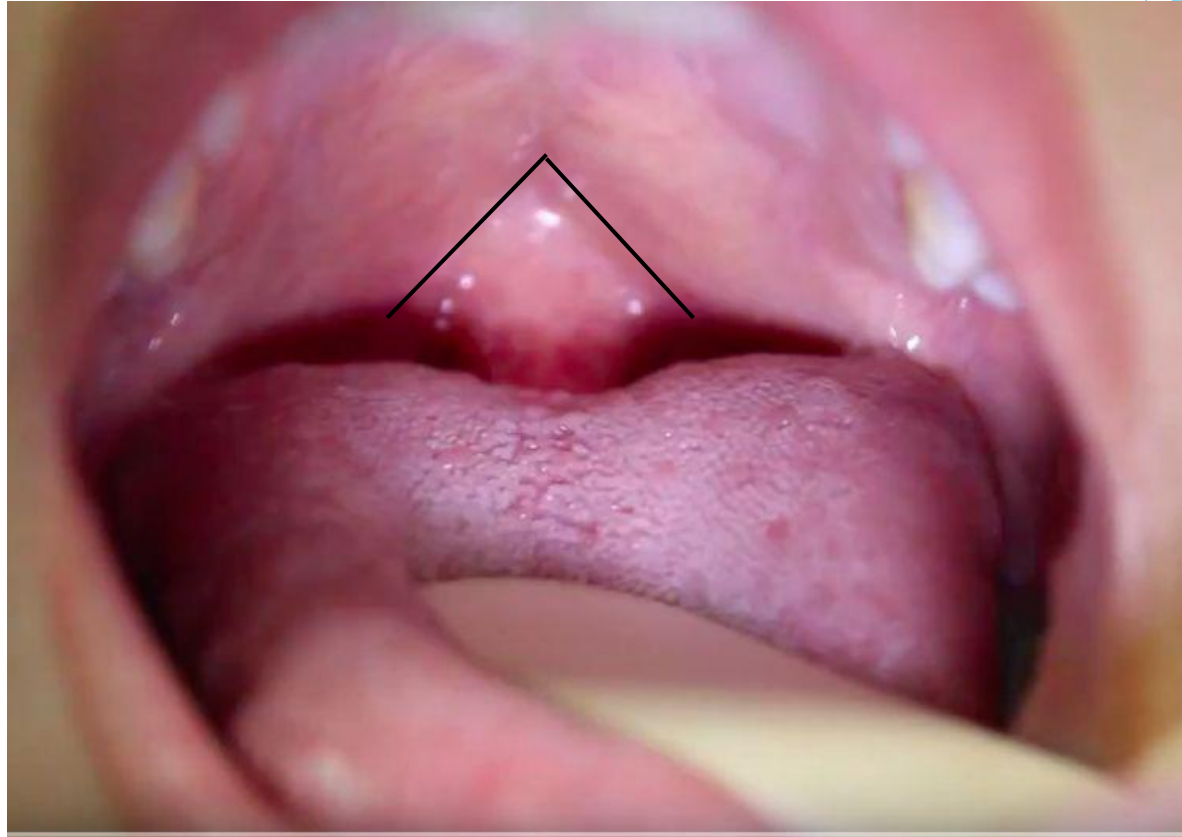
Submucous Cleft - Zona pellucida



Submucous Cleft - "Inverted V"



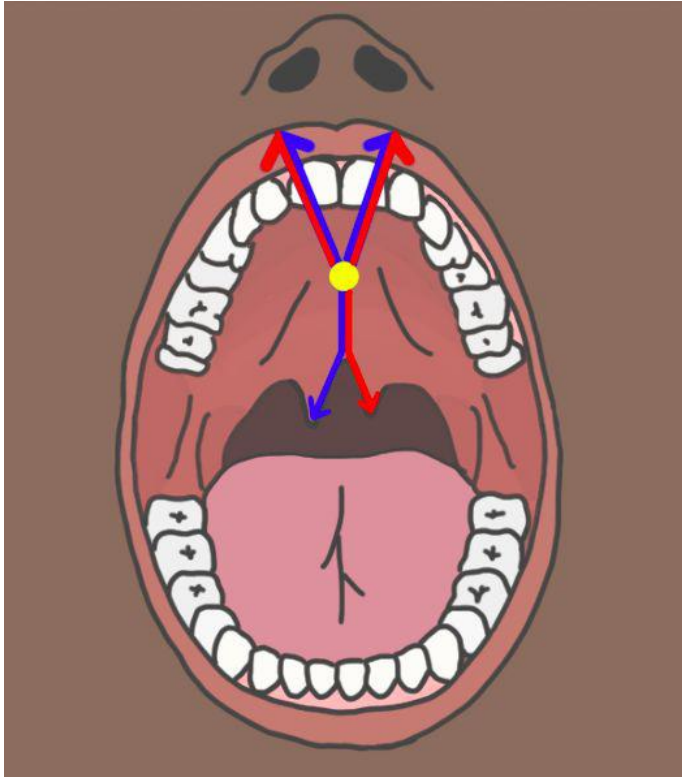
Submucous Cleft - "Inverted V"



Submucous Cleft -- Bifid Uvula

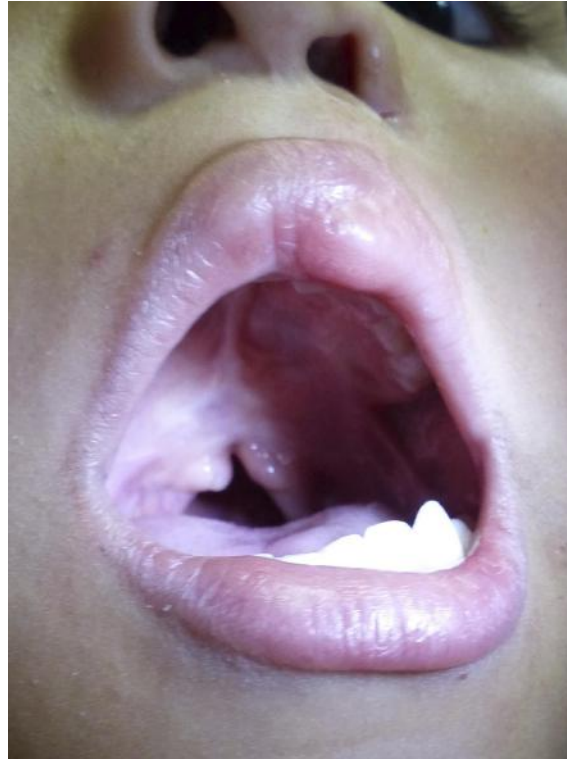
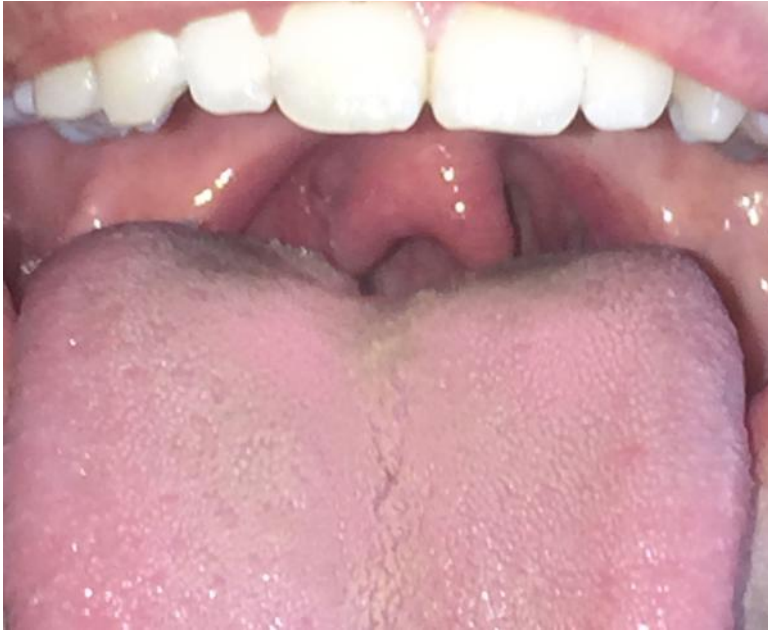- ❖ May be split down the middle with two pendulous structures
- ❖ May appear as one structure with line down the center
- ❖ May have a simple indentation at the posterior border
- ❖ Uvula may appear small and undeveloped--hypoplastic.

Submucous Cleft -- Bifid Uvula



In this photo, we see that there is a submucous cleft with a bifid uvula, as this did not close in development. Submucous cleft is not always identified because patients are not always symptomatic and, even with physical signs of submucous cleft, can have normal speech!

Submucous Cleft -- Bifid Uvula



Submucous Cleft -- Notch in Posterior Border of Hard Palate

- In normal palate, can often feel slight projection of posterior nasal spine.
- If there is an appreciable notch in the posterior border of the hard palate, this indicates the presence of a submucous cleft palate.
- Use gloved examination. Notch can be small and narrow so use pinky finger to feel.



Occult Cleft

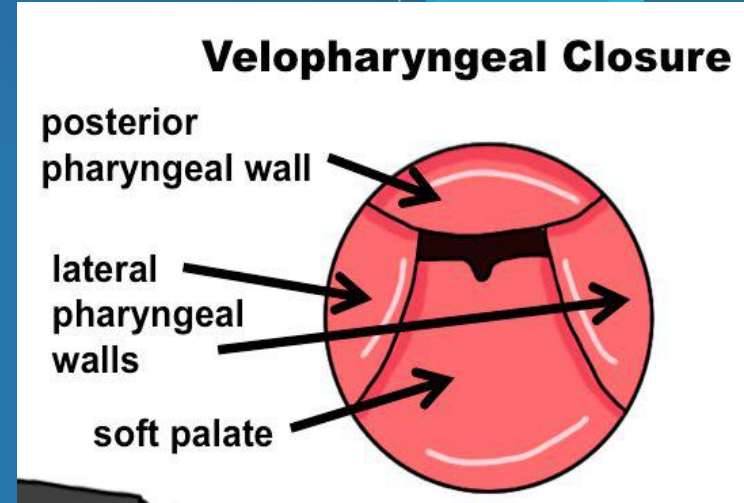
- Sometimes children may seem hypernasal, however, there is no physical abnormality in the palate.
- Occult cleft are diagnosed through nasoendoscopy, which is when a scope with a camera is passed through the nostrils to observe how velopharyngeal structures move during speech.



LEADERSPROJECT
TEACHERS COLLEGE • COLUMBIA UNIVERSITY

Module 1.4:

• Velopharyngeal Closure



Written by:

Catherine (Cate) J. Crowley, J.D., Ph.D., CCC-SLP

Miriam Baigorri Ph.D., CCC-SLP

Chelsea Sommer M.S., CF-SLP

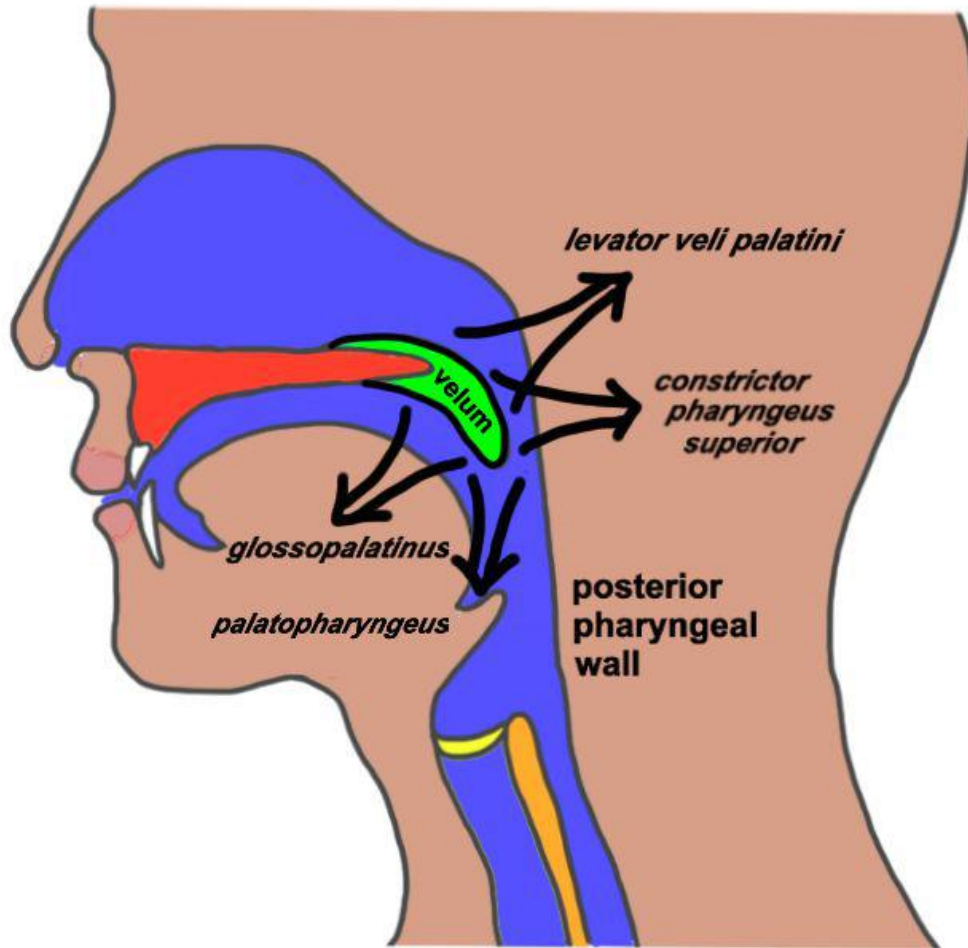
With contributions by:

Casey Sheren, Sara Horne, Marcos Sastre, Grace Frutos, & Julie Smith

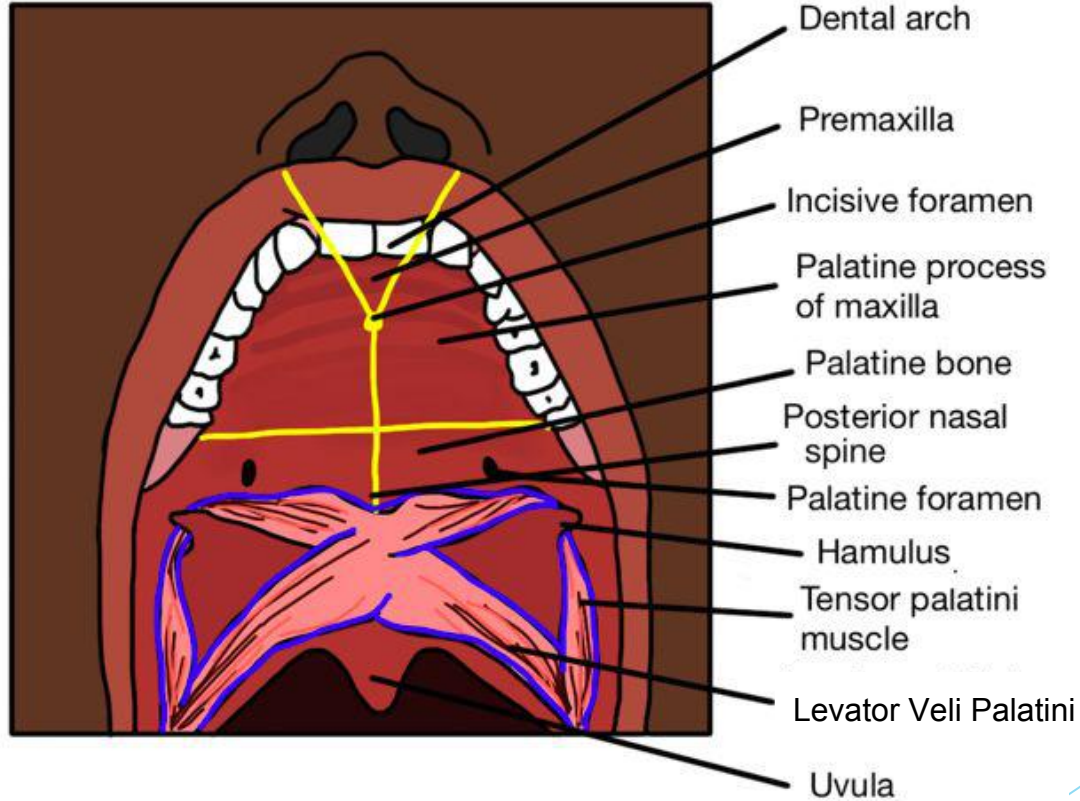
Muscles Involved in Velopharyngeal Closure

- **Levator veli palatini**- main muscle for velar elevation
- **Superior pharyngeal constrictor**- medial displacement of lateral pharyngeal walls
- **Musculus uvulae**- contracts during phonation and create bulge on velum which adds stiffness of velum
- **Palatoglossus muscles**- depresses the velum

*Tensor veli palatini- opens the Eustachian tube for middle ear drainage, contributes little or nothing with velopharyngeal closure.

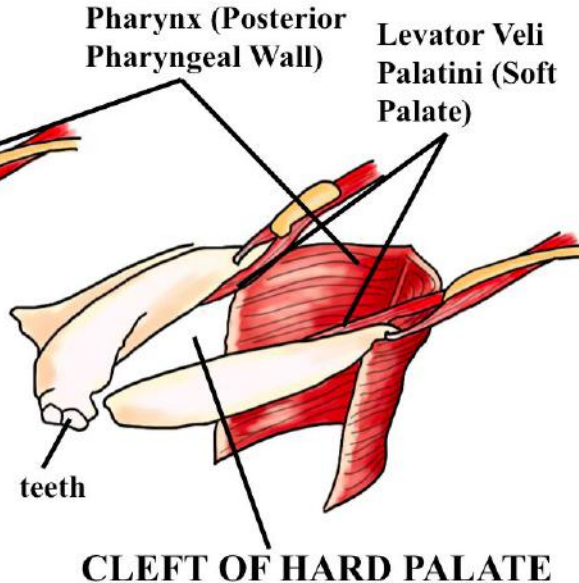
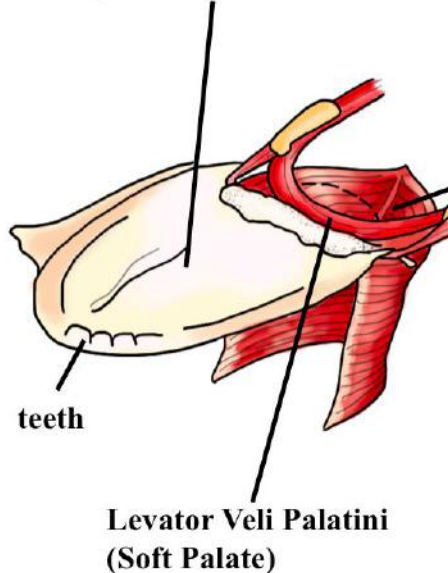


Remember what typical anatomy of the oral structures looks like:



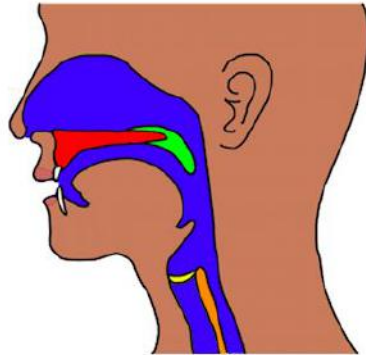
The levator veli palatini muscle cannot connect where there is a cleft palate, meaning that the soft palate cannot raise appropriately to create high pressure oral sounds.

TYPICAL HARD PALATE



The Door Metaphor is an analogy for better understanding cleft palate and why speech errors occur.

Play Video #1 entitled
“Door Metaphor for Velopharyngeal Closure”

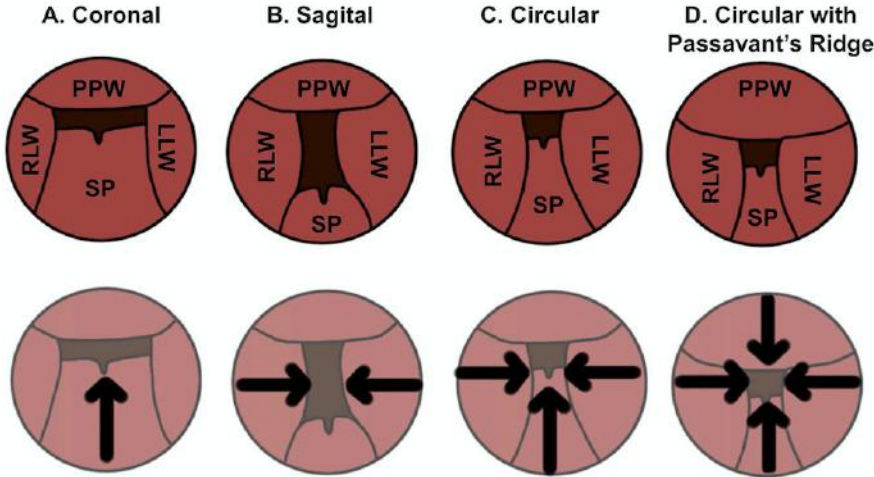




Your turn!

Turn to your partner and practice reciting **The Door Metaphor**. This will be necessary when explaining cleft palate airflow and speech to parents of children with cleft palate.

Velopharyngeal Closure Patterns



With coronal closure pattern, superior movement of the soft palate is the main contributor to VPC

With sagittal closure pattern, movement of the lateral pharyngeal walls is the main contributor to VPC

With circular closure pattern, movement of the lateral pharyngeal walls and SP contribute equally to VPC

“Passavant’s Ridge” is a bulge of tissue on the posterior pharyngeal wall that aids in VPC

There are 4 typical ways velopharyngeal closure can occur. These are different ways in which “the door” can close to create high pressure oral sounds, such as “p”, “b”, “t”, “d”, “k”, “g”, “f”, “s”, “z”, “ch”, “sh”, etc.

PPW = Posterior pharyngeal wall
RLW = Right lateral pharyngeal wall
LLW = Left lateral pharyngeal wall
SP = Soft palate
VPC = velopharyngeal closure

What is *velopharyngeal dysfunction* (VPD)?

Condition where the door--the velopharyngeal closure--does not happen. Why?

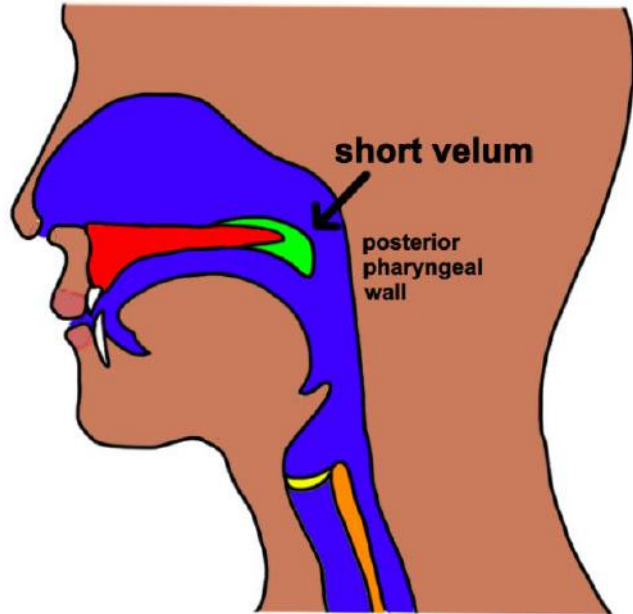
Structural - *"VP insufficiency"*

- Velum too short to reach the posterior pharyngeal wall
- Hole in the palate--a cleft palate--that is a structural reason why the door cannot close

Functional - *"VP incompetency"*

- Physiological: The levator veli palatini does not do its job of lifting the soft palate
- Neurological: Apraxia, dysarthria, brainstem tumor

Illustration of Velopharyngeal Insufficiency



Examples of velopharyngeal insufficiency include a cleft, submucous cleft, or short velum. This picture shows a short velum, which would be a structural deficit resulting in velopharyngeal insufficiency.

What is “velopharyngeal mislearning”?

- Articulation disorder that might *seem* like velopharyngeal dysfunction
 - Normal structure, normal function
- Air exits through the nose for high pressure sounds
 - /p/ /b/ /t/ /d/ /k/ /g/
 - Continuous sounds (e.g. /f/ /sh/ or /s/) are hypernasal



LEADERSPROJECT
TEACHERS COLLEGE • COLUMBIA UNIVERSITY

Module 1.5:

- **Feeding a Baby with Cleft Palate (Abbreviated)**



Written by:

Catherine (Cate) J. Crowley, J.D., Ph.D., CCC-SLP

Miriam Baigorri Ph.D., CCC-SLP

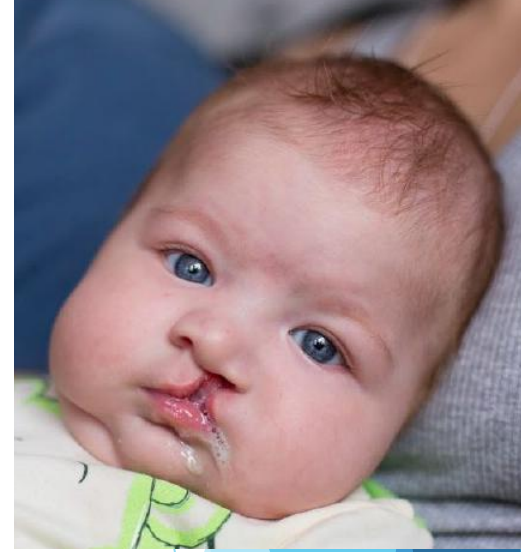
Chelsea Sommer M.S., CF-SLP

With contributions by:

Casey Sheren, Sara Horne, Marcos Sastre, Grace Frutos, & Julie Smith

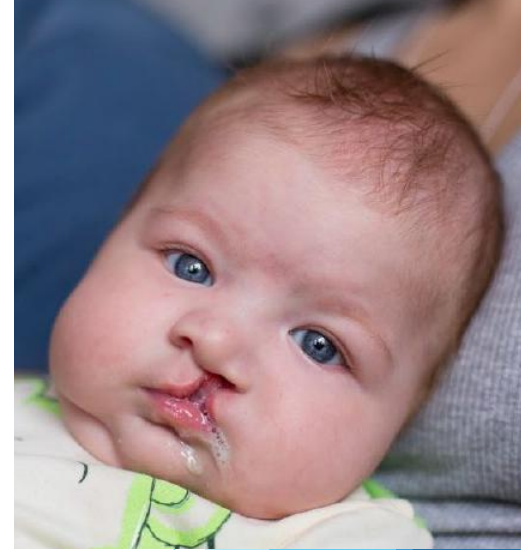
Strategies for feeding a baby with cleft lip or palate

1. Always feed your baby in an upright position, whether it is from the breast or cup.
2. Burp your baby every 5 minutes.
3. Keep your baby upright or seated for 20 – 30 minutes after each meal.



Strategies for feeding a baby with cleft lip or palate

For more information on feeding a baby with cleft lip and palate, see Optional Presentation “Feeding a Baby with a Cleft Lip and/or Palate”



Credits

Catherine (Cate) Crowley, J.D., Ph.D., CCC-SLP

Miriam Baigorri, Ph.D., CCC-SLP

Chelsea Sommer, M.S., CF-SLP



LEADERSPROJECT
TEACHERS COLLEGE • COLUMBIA UNIVERSITY

Credits

Graduate Research Associates and SLP master's students:

Marcos Sastre III, B.S.

Casey Sheren, B.A.

Sara Horne, B.S.

Graduate Research Assistants and SLP master's students:

Johanna Kreishbuch, B.S.

Julie Smith, B.S.

Pam Kotorac, B.S.



LEADERSPROJECT
TEACHERS COLLEGE • COLUMBIA UNIVERSITY

Support and Funding Provided By:

- The Wyncote Foundation
- Smile Train
- Teachers College, Columbia University
- The Crowley Family

Special thanks to the families and children in
these videos



LEADERSPROJECT
TEACHERS COLLEGE • COLUMBIA UNIVERSITY

Cite this as:

Crowley, C., Baigorri, M., & Sommer, C. (2016).
Cleft Palate Speech and Feeding Video
Tutorials.

Available at LEADERSproject.org



Attribution-NonCommercial-NoDerivs
CC BY-NC-ND



LEADERSPROJECT
TEACHERS COLLEGE • COLUMBIA UNIVERSITY

All Cleft Palate Speech Therapy Resources Available for FREE download LEADERSProject.org

Discrimination Clown Picture
Speech Sound Assessment and Stimulability
Acevedo Spoke
Therapy Word Games
Therapy Books for Phrases and Sentences



Attribution-NonCommercial-NoDerivs
CC BY-NC-ND



LEADERSPROJECT
TEACHERS COLLEGE • COLUMBIA UNIVERSITY



LEADERSPROJECT
TEACHERS COLLEGE • COLUMBIA UNIVERSITY

LEADERSproject.org

Teachers College, Columbia University, 2016

All content unless otherwise stated is licensed Creative Commons
Attribution-NonCommercial-NoDerivs

CCC BY-NC-ND

For more information, please contact Dr. Catherine Crowley at
crowley@exchange.tc.columbia.edu



Attribution-NonCommercial-NoDerivs
CC BY-NC-ND

References

Crowley, C. & Baigorri, M. (2014). *Terapia del Habla para Paladar Hendido: Evaluación y Tratamientos (Cleft palate evaluation and treatment modules for professionals)*. Retrived from <http://www.leadersproject.org/2014/05/20/terapia-para-paladar-hendido-evaluacion-en-tratamientos-playlist/>

Crowley, C., Baigorri, M., & Kreisbuch, J. (2016, May). *Diagnostic evaluation and interview for cleft palate*. Retrieved from <http://www.leadersproject.org/2016/05/30/diagnostic-evaluation-and-interview-for-cleft-palate/>

Crowley, C., Baigorri, M., & Miranda, J. (2013, June). *Feeding babies with cleft palate with breast/bottle: Parent handout in English*. Retrieved from: <http://www.leadersproject.org/2013/07/08/feeding-babies-with-cleft-palate-with-breastbottle-parent-handout-in-english/>

References

Crowley, C., Baigorri, M., Sommer, C., & Acevedo, D. (2016, May). *What to do before the cleft palate is repaired to improve speech outcomes after surgery*. Retrieved from

<http://www.leadersproject.org/2016/05/30/strategies-before-the-cleft-palate-is-repaired/>

Crowley, C., Baigorri, M., Yeung, T. (2013, December). *Feeding babies with cleft palate with breast/cup: Parent handout in English*. Retrieved from

<http://www.leadersproject.org/2013/12/30/feeding-babies-with-cleft-palate-with-breastcup-parent-handout-in-english/>

Golding-Kushner, K. (2004). Treatment of sound system disorders associated with cleft palate speech. *SIG 5 Perspectives on Speech Science and Orofacial Disorders*, 14(2), 16-20.

References

Hardin-Jones, M. A., Chapman, K. L., & Scherer, N. J. (2015). *Children with cleft lip and palate: A parent's guide to early speech-language development and treatment*.

Bethesda, MD: Woodbine House.

Kummer, A. (n.d.). Speech therapy for cleft palate or velopharyngeal dysfunction (VPD). *Cincinnati Children's Hospital Medical Center*, 1-6.

Peterson-Falzone, S.J., Hardin-Jones, M.A., Karnell, M.P. (2010). *Cleft Palate Speech* (4th Edition). St. Louis, MO: Mosby Elsevier.

Peterson-Falzone, S., Trost-Cardamone, J., Karnell, M., & Hardin-Jones, M. (2006). *The clinician's guide to treating cleft palate speech*. Philadelphia: Mosby.

References

Sell, D. (2008). Speech therapy delivery and cleft lip and palate in the developing world. *Management of cleft lip and palate in the developing world*. Hoboken, N.J.: John Wiley & Sons, Ltd. (pp. 193-202).

Sommer, C. (2016, May). *English Cleft Palate Speech Therapy Word Lists*. Retrieved from <http://www.leadersproject.org/2016/05/30/english-cleft-palate-speech-therapy-word-lists/>

Sommer, C., Crowley, C., Baigorri, M., & Acevedo, D. (2016, May). *Cleft Palate Speech Therapy Hierarchy*. Retrieved from <http://www.leadersproject.org/2016/05/30/cleft-palate-speech-therapy-hierarchy/>

Watson, A., Sell, D., & Grunwell, P. (2001). *Management of cleft lip and palate*. John Wiley & Sons Incorporated.