



Case Reports

Approaching a Fork in the Road: A Case of Aborting Endoscopy After Discovering a Retained Foreign Object

Natalie Perez-Mendez, MD¹, Michelle Freeman, MD¹, Hasan Ilyas, MD¹, Eduardo Quintero-Nazario, MD², Minesh Patel, MD¹

¹ Schmidt College of Medicine, Florida Atlantic University,

² Gastroenterology, Baptist Health South Florida

Journal of Brown Hospital Medicine

Vol. 3, Issue 2, 2024

Article Information

Keywords: endoscopy, foreign body ingestion, incarceration

<https://doi.org/10.56305/001c.115816>

Submitted: December 01, 2023 EDT

Accepted: March 25, 2024 EDT

Abstract

We describe a case of a 53-year-old female who presented for elective esophagogastroduodenoscopy (EGD) and eventually needed surgical intervention to remove a plastic fork that she accidentally swallowed twenty years prior while in prison. This article highlights approaches to retrieving a foreign object within the stomach via endoscopy, the importance of recognizing the risks of endoscopy, and serves as a reminder that we must be aware of the social determinants of health that pertain to our patients.

BACKGROUND

Foreign body ingestion is commonly seen in clinical practice. Most foreign bodies pass spontaneously. However, approximately 10-20% of cases warrant endoscopic removal, with less than 1% requiring surgery for foreign body extraction or to treat complications.¹ Diagnostic esophagogastroduodenoscopy (EGD) is a remarkably safe procedure, but adverse events occur 0.13% of the time and have an associated mortality of 0.004%.² The risk of complications increases with prolonged procedural time.³

CASE PRESENTATION

A 53-year-old female with a past medical history of opioid use disorder on methadone, anxiety, and a history of incarceration presented to her gastroenterologist at the direction of her primary care physician due to a family history of gastric cancer. On physical exam, the patient appeared healthy, had no abdominal distension, denied early satiety, and had no abdominal tenderness. The gastroenterologist performed an elective EGD and colonoscopy, and upon arriving at the stomach, a foreign body was found ([Figure 1](#)). The foreign body was oriented with the blunt end at the pylorus and the object's sharp end toward the stomach's fundus. The foreign body could not be removed despite multiple attempts using both the single and the double channel endoscope, using one and two snares and graspers for traction. The plastic fork could be manipulated, but on repeated occasions, it was stuck upon retraction through the gastroesophageal junction (GEJ). Due to the risk of perforation and the fork becoming stuck at the GEJ, the decision was

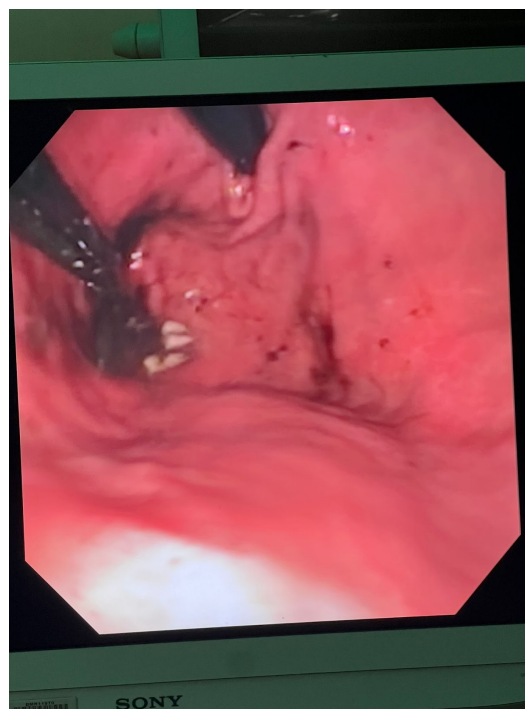


Figure 1. Endoscopic view of the foreign object oriented with the blunt end at the pylorus and the sharp end of the object toward the fundus of the stomach.

made to abort the endoscopy after two hours of procedural time.

The patient was monitored in the post-anesthesia care unit in stable condition and admitted into the inpatient wards after general surgery was consulted for further management. An abdominal x-ray was obtained to ensure there was no evidence of perforation and to evaluate for the presence of any other radiopaque foreign material. The abdominal x-ray and basic laboratory workup were

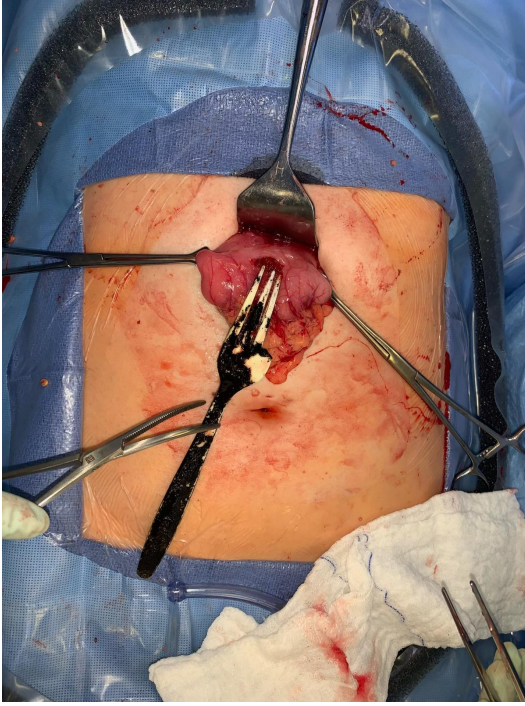

Figure 2. Intraoperative visualization of the foreign object with one prong noted to be missing.

unremarkable and did not demonstrate the fork as seen on EGD.

The patient underwent surgical exploration with a small midline-epigastric incision and a gastrostomy. The blunt end of the fork was easily found, and the fork was removed from the stomach. As seen in [Figure 2](#), a prong was missing; however, the plastic fork was consistent with what was visualized during EGD. After thoroughly investigating the stomach, the prong was felt to have passed, and further surgical investigation was terminated. The stomach was closed in layers, and a nasogastric tube was placed for postoperative gastric decompression. The patient's postoperative course was uncomplicated, with the return of bowel function, and she was able to tolerate a full diet.

DISCUSSION

This case illustrates the importance of recognizing when to abort an upper endoscopy procedure when a foreign object cannot be safely extracted. One case report demonstrated the extraction of a plastic fork with a double-scope technique. However, this was outside the scope of practice for the gastroenterologist.⁴ The fork was also an incidental foreign object. The patient did not disclose her history of plastic fork ingestion twenty years prior while incarcerated at the time of the initial office visit. She presented for medical care at the facility where she was incarcerated; she was asymptomatic, an x-ray did not demonstrate a retained foreign object, and medical staff advised that the fork would “dissolve.” She was monitored for any

signs and symptoms of distress. She remained asymptomatic for the remainder of the time between this event and the presentation to our institution.

Substandard medical care within the US prison system has been well documented.^{5,6} Although the exact circumstances of the initial presentation are unknown, it is evident that our patient was unable to obtain adequate medical intervention initially when she swallowed the plastic fork. This raises concern that she may have been disregarded or denied appropriate health care because of her incarcerated status. In general, objects larger than 2.5 cm in width or 13 cm in length are unlikely to leave the stomach.⁷

Because of the pervasive stigma associated with incarceration, it may be challenging to obtain an accurate social history from this patient population. One approach to eliciting incarceration history in patients, especially in communities with higher rates of incarceration, is by utilizing open-ended questions such as “Some of my patients and their family members have experienced incarceration in the past, and this can affect their health. Has this ever happened to you?”⁸ By opening up the conversation about this social determinant of health non-judgmentally, patients may disclose relevant information that can lead to more individualized care and identify risk factors that otherwise would not have been known.

Emergent EGD is indicated for ingestion of sharp or pointed foreign bodies as well as radiolucent objects.⁹ Per the specimen's postoperative gross measurement and pathology report, the plastic fork our patient swallowed was approximately 18.5 cm by 3 cm ([Figure 3](#)). Urgent surgical intervention was obtained for the patient during this hospitalization; however, this was not the case during her initial workup. Ingested sharp, pointed, caustic objects should be removed to prevent perforation, ulceration, or damage to other surrounding tissues and organs.^{10,11}

In summary, we aim to highlight endoscopic and surgical approaches to retained foreign objects and emphasize the importance of obtaining a thorough social history from patients so that physicians can identify the social determinants of their patients' health and reduce healthcare disparities.

Author contributions

All Authors have reviewed the final manuscript prior to submission. All the authors have contributed significantly to the manuscript, per the ICJME criteria of authorship.

- Substantial contributions to the conception or design of the work; or the acquisition, analysis, or interpretation of data for the work; AND

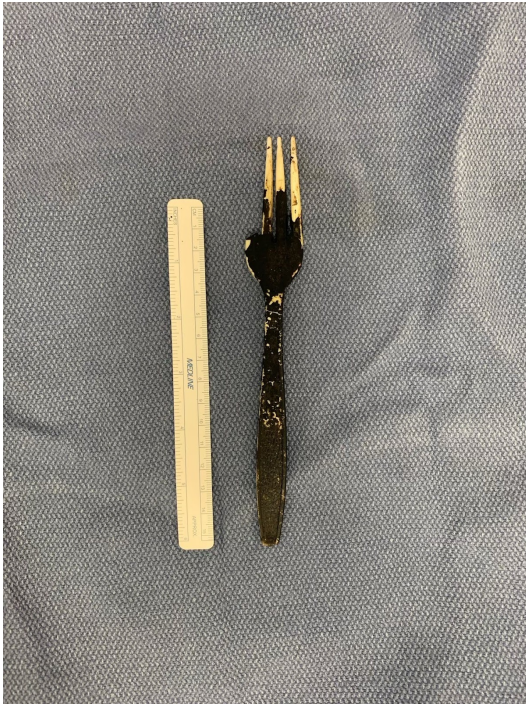

Figure 3. Plastic fork measuring approximately 18.5 cm by 3 cm.

- Drafting the work or revising it critically for important intellectual content; AND
- Final approval of the version to be published; AND
- Agreement to be accountable for all aspects of the work in ensuring that questions related to the accuracy or integrity of any part of the work are appropriately investigated and resolved.

Disclosures

The authors have no conflicts of interest to disclose.

Corresponding author:

Natalie Perez-Mendez, MD
Florida Atlantic University, Schmidt College of Medicine
777 Glades Road, BC-71, Boca Raton, FL 33431
Email: nperezme@health.fau.edu



This is an open-access article distributed under the terms of the Creative Commons Attribution 4.0 International License (CCBY-NC-4.0). View this license's legal deed at <https://creativecommons.org/licenses/by-nc/4.0> and legal code at <https://creativecommons.org/licenses/by-nc/4.0/legalcode> for more information.

REFERENCES

1. Birk M, Bauerfeind P, Deprez P, et al. Removal of foreign bodies in the upper gastrointestinal tract in adults: European Society of Gastrointestinal Endoscopy (ESGE) Clinical Guideline. *Endoscopy*. 2016;48(5):489-496. doi:10.1055/s-0042-100456
2. Levy I, Gralnek IM. Complications of diagnostic colonoscopy, upper endoscopy, and enteroscopy. *Best Pract Res Clin Gastroenterol*. 2016;30(5):705-718. doi:10.1016/j.bpg.2016.09.005
3. ASGE Standards of Practice Committee, Ben-Menachem T, Decker GA, et al. Adverse events of upper GI endoscopy. *Gastrointest Endosc*. 2012;76(4):707-718. doi:10.1016/j.gie.2012.03.252
4. Yonemoto S, Uesato M, Aoyama H, et al. A double-scope technique enabled a patient with an esophageal plastic fork foreign body to avoid surgery: a case report and review of the literature. *Clin J Gastroenterol*. 2021;15(1):66-70. doi:10.1007/s12328-021-01549-6
5. Shalit M, Lewin MR. Medical care of prisoners in the USA. *Lancet*. 2004;364:34-35. doi:10.1016/s0140-6736(04)17633-2
6. Wilper AP, Woolhandler S, Boyd JW, et al. The health and health care of US prisoners: results of a nationwide survey. *Am J Public Health*. 2009;99(4):666-672. doi:10.2105/ajph.2008.144279
7. Elsevier. Gastrointestinal Endoscopy. In: *Goldman-Cecil Medicine*. ; 2020:836-838.
8. Sue K. How to Talk with Patients about Incarceration and Health. *AMA J Ethics*. 2017;19(9):885-893. doi:10.1001/journalofethics.2017.19.9.ecas2-1709
9. Ambe P, Weber SA, Schauer M, Knoefel WT. Swallowed foreign bodies in adults. *Dtsch Arztebl Int*. 2012;Dec;109(50):869-75:869-875. doi:10.3238/arztebl.2012.0869
10. Demiroren K. Management of Gastrointestinal Foreign Bodies with Brief Review of the Guidelines. *Pediatr Gastroenterol Hepatol Nutr*. 2023;26(1):1. doi:10.5223/pghn.2023.26.1.1
11. Yilmaz S, Aydin H, Bolukbasi H. Insidious Onset of Localised Small Intestinal Perforation by Ingested Plastic Fork. *J Coll Physicians Surg Pak*. 2022;32(8):1070-1072. doi:10.29271/jcpsp.2022.08.1070