

Tissue Strain Under the Sacrum & Coccyx

By Supine Posture and Skeletal Morphology

Stephen Sprigle^{1,2}, PhD, PT & Sharon Sonenblum¹, PhD
¹ The George W. Woodruff School of Mechanical Engineering
² College of Design

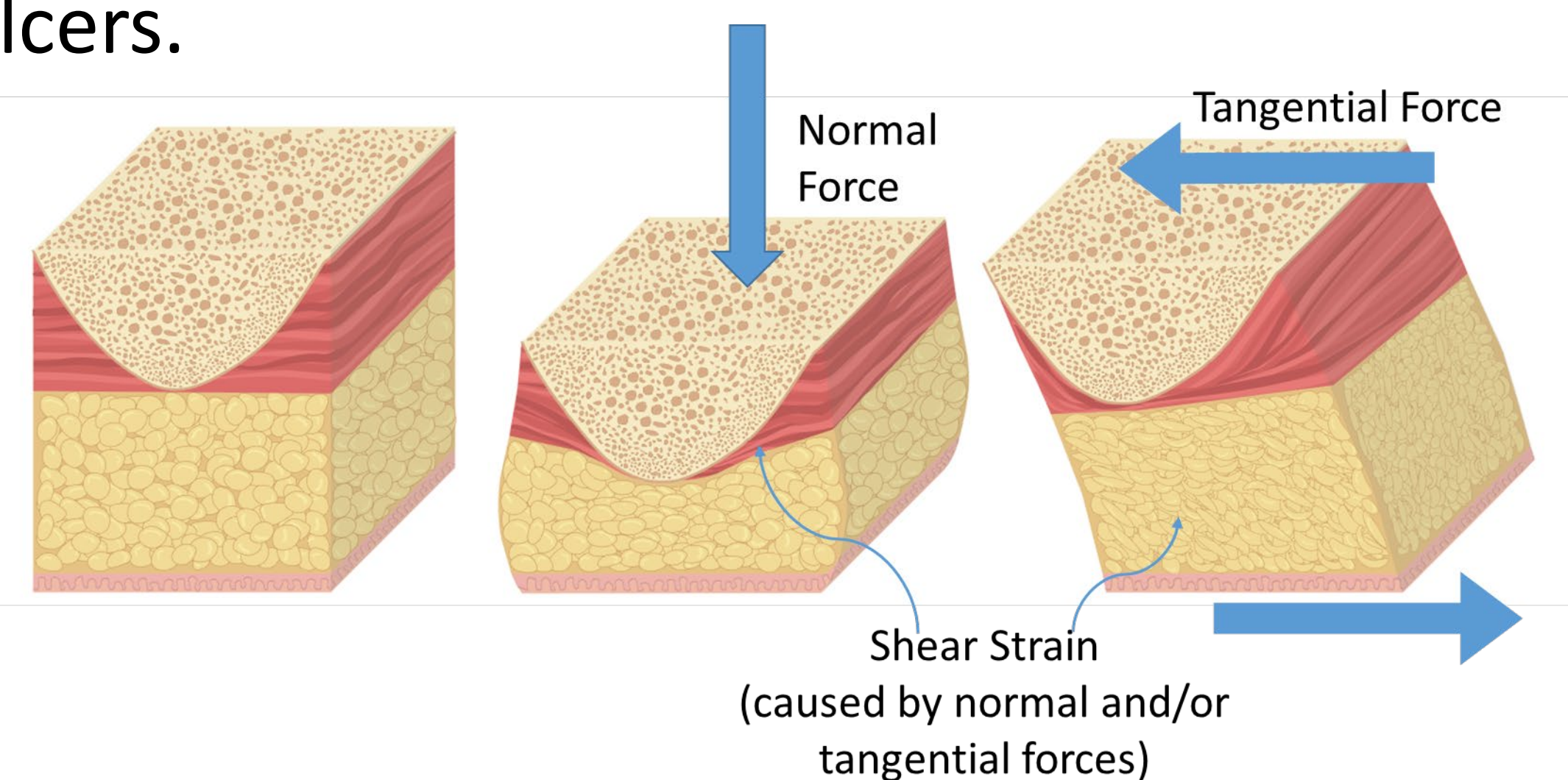
Abstract

The objective was to study the influence of head of bed (HOB) position and sacrum and coccyx anatomy on tissue deformation. We found that, when the HOB is raised to 30°:

- 1) Tissue thickness under the sacrum stays the same or increases
- 2) The spine shifts caudally relative to the skin

Background

External forces by definition cause pressure ulcers.



30° HOB is often not recommended for pressure ulcer prevention, but is for respiration, digestion, comfort and communication.

Methods

- 3 subjects (2 F, 1 M)
 - MRI: T1-weighted Fast Spin Echo protocol
 - Supine, 30° HOB with pelvis on the flat, horizontal segment (n=3), 30° HOB with pelvis on the inclined segment (n=2)
- We measured: 1) Differences in tissue thickness with HOB position, 2) Skeleton displacement relative to the skin with HOB incline, and 3) The differences in sacro-coccygeal morphology

Acknowledgements

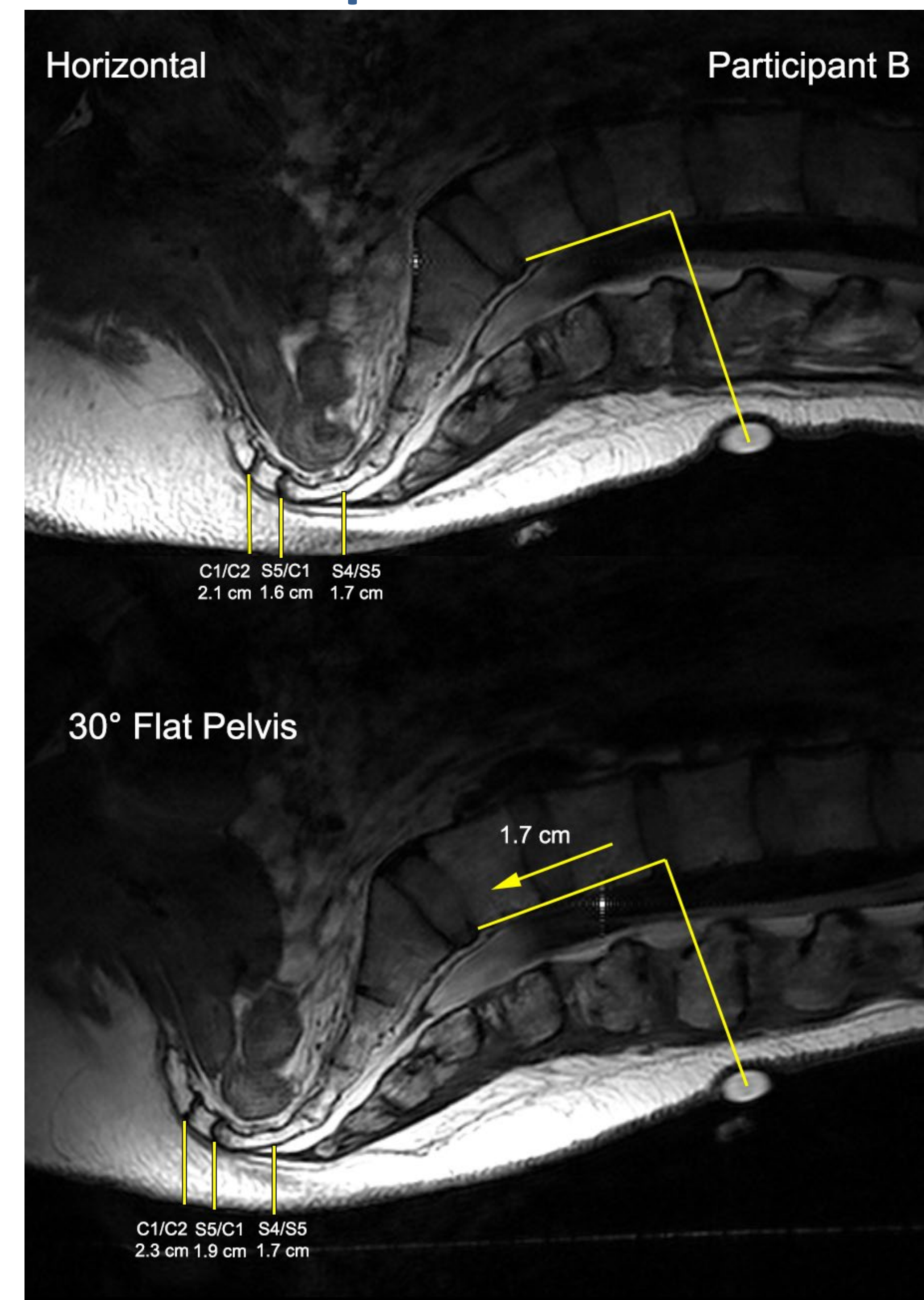
The authors thank Dr. John Greenhalgh and Fonar for his expertise in collecting the MRI images and use of the scanner.

Tissue Thickness

Vertebral Level	Tissue Thickness (mm)	Δ from horizontal to 30° HOB (flat pelvis) (mm)	Δ from horizontal to 30° HOB (inclined pelvis) (mm)
S4/S5	17 – 32	0 – 3	6 – 8
S5/C1	16 – 25	0 – 3	3 – 4
C1/C2	20 – 21	0 – 3	-2 – 3

- With HOB raised, tissue does NOT compress under the sacrum
- The change in lumbo-sacral angle and intercoccygeal angle with HOB angle depends on where the pelvis is placed relative to the chassis articulations

Skeletal Displacement



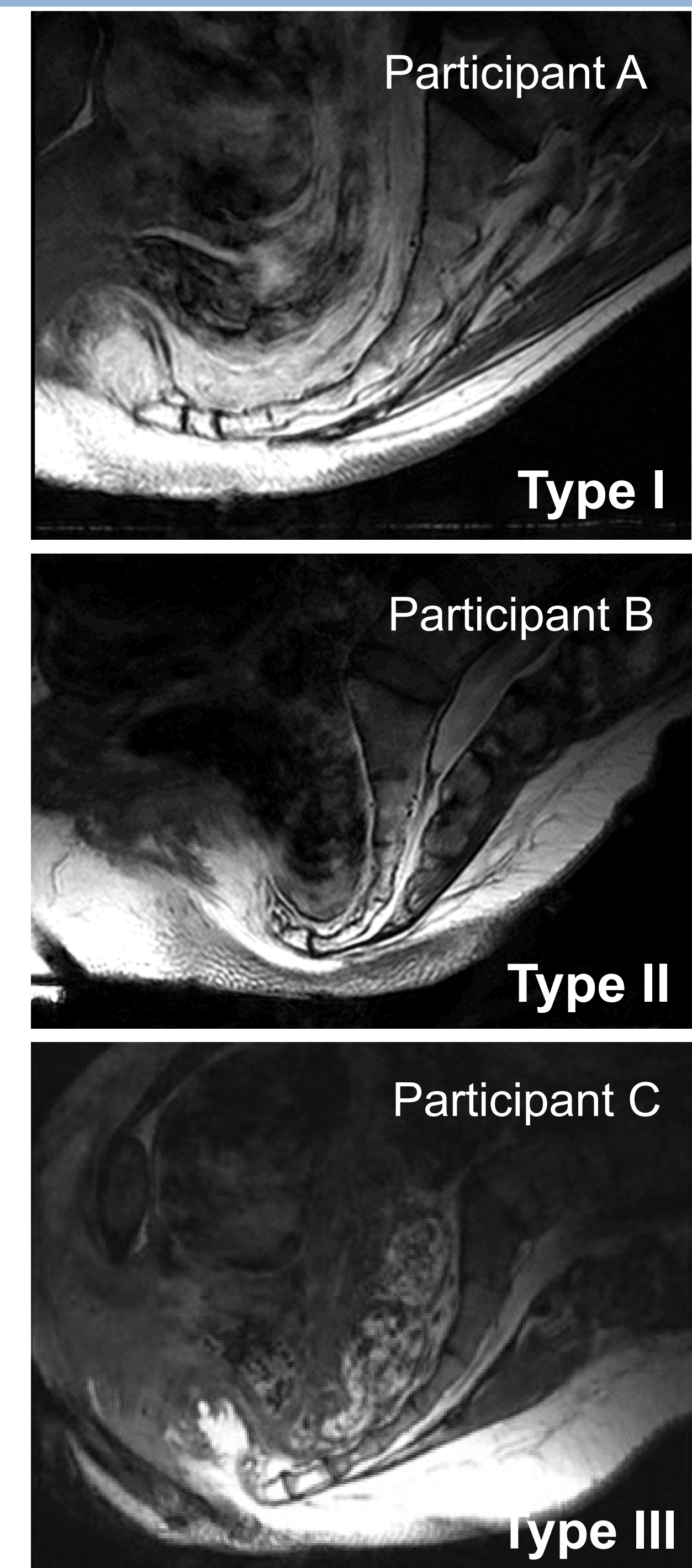
- Skin is held in place by friction, while the skeleton displaced
- Displacement of the skeleton towards the feet (relative to the skin) ranged from 0.8 to 2.3 cm when the HOB was raised to 30°
- The skeleton induced a force which deformed tissue through normal and shear stresses
- Shear strain must occur in the tissue layers in between the skin and bone

Reference

Sprigle, S., & Sonenblum, S. E. (In Press). Visualizing tissue strain under the sacrum and coccyx within different supine postures- a case research report. *Adv Skin Wound Care*.

Morphology

- 3 different coccyx types are shown at 30° HOB with the pelvis inclined
- Skeletal morphology will influence how load is transmitted into tissue
- Participant C appears to be at the greatest Biomechanical Risk.



Discussion

- Raising the HOB does not increase tissue compression, and instead may be more damaging due to increased tangential forces and shear strains
- Friction at the body interface induces stress in tissue that results in shear strain within internal soft tissue
- Further study into appropriate interventions according to the role of skeletal morphology in biomechanical risk is needed