

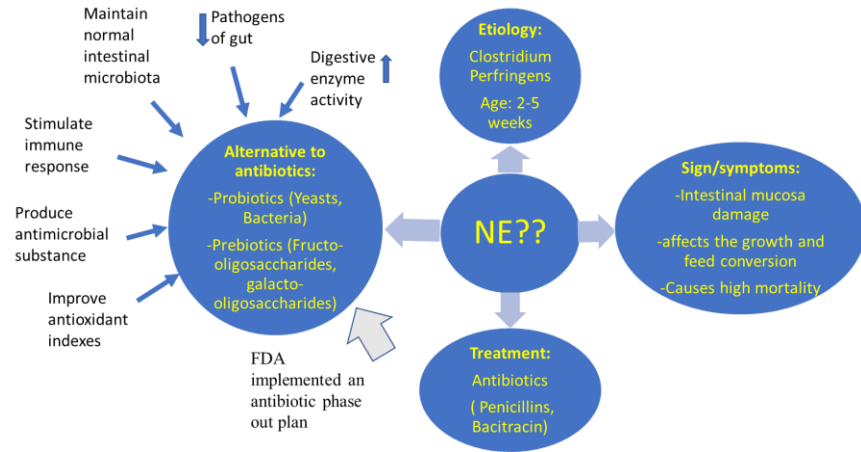
# Bacillus Subtilis an alternatives to antibiotics in controlling Necrotic Enteritis (NE) in broilers

Shweta Ghimire\*, Xinwen Zhang\*, Jinglin Zhang\*, Dr. Changqing Wu\*

\*Department of animal and food sciences, University of Delaware



## Introduction:



## Objectives:

Our research aim is to study if the new probiotic *Bacillus subtilis* isolates 103a and 62a can control necrotic enteritis (NE) and improve animal performance in broiler chickens.

## Methods and materials:

- Day 1 broiler, reared in deep litter for 28 days,
- feed and water without probiotic and antibiotic given ad libitum.
- Probiotic water calculated:

age of the bird in days \* 0.2 ounces  
\*number of bird in treatment house.

## Methodological tests:

- Major body organ weight (bursa, spleen, liver, thymus) and NE lesion scoring
- Antimicrobial assay
- Average birds' weight and feed consumption recorded on day 1, 10, 15, 20, 22, 24, 26, and 28 for feed conversion ratio (FCR)

- Microbiota analysis of cecum content using Shoreline Biome Kit (PacBio) compared to Athena database in Sbanalyzer, and  $\alpha$ -diversity using R
- oxygen radical antioxidant capacity (ORAC) assay from blood plasma

Group	no. of birds/house	Water	IBDV challenge		CP challenge	
			Age of chick	Dose	Age of chick	Dose
Control	15	normal water	x	x	x	x
103a	5	103a at 10 <sup>7</sup> CFU/ml water	x	x	x	x
62a	5	62a at 10 <sup>7</sup> CFU/ml water	x	x	x	x
Mixed(103a+62a)	5	mixed at 10 <sup>7</sup> CFU/ml water	x	x	x	x
Control	15	normal water	10	10x	16,17,18	10 <sup>8</sup>
103a	5	103a at 10 <sup>7</sup> CFU/ml water	10	10x	16,17,18	10 <sup>8</sup>
62a	5	62a at 10 <sup>7</sup> CFU/ml water	10	10x	16,17,18	10 <sup>8</sup>
Mixed(103a+62a)	5	mixed at 10 <sup>7</sup> CFU/ml water	10	10x	16,17,18	10 <sup>8</sup>

Table1: Research design for broiler with CP challenge and probiotic supplementation

## Results:

### 1) FCR

- Significant decrease in FCR in the infected group compared to the non-infected 62a treated broilers.

### 2) ORAC assay

- 103a probiotic in the infected group significantly ( $p < 0.05$ ) decreased antioxidant level of plasma compared to control.

## 3) Organ weight , lesion sore and mortality

	Non infected				Infected			
	Cont rol	103a	62a	Mixed	Cont rol	103a	62a	Mixed
Thymus (g)	2.12 ±0.88	2.85±1.96	2.28±0.57	1.94±0.55	2.7±0.99	2.77 ±0.56	2.76±0.3	1.66±0.56
Spleen (g)	1.22 ±0.48	1.12±0.47	0.79±0.57	1.20±0.56	1.13±0.04	1.18 ±0.43	0.91±0.22	0.82±0.22
Bursa (g)	2.15 ±0.58	1.77±0.83	2.1±0.22	1.35±0.93	1.86±0.57	1.8±0.42	2.4±0.84	1.97±0.51
Liver (g)	23.2 ±4.187	24.07±10.41	23.45 ±5.21	26.46 ±7.67	27.34 ±4.63	32.3 ±2.45	28.49 ±2.19	26.05 ±8.12
Lesion scores (d28)	0,2,0	0,0,0	2,0,0	0,1,0	2,3,3	3,1,2	3,1,1	1,1,2

Table2: Organ weight with std error and lesion score for experimental groups

Treatment and challenges	No. of mortality	Symptoms or lesion of dead chickens
Control Non-infected	3	1 have fluid filled peritoneal cavity, and other did not showed any lesions or symptoms.
103a Non-infected	2	No lesions seen
62a Non infected	1	Have leg problems and difficulty walking, no lesions seen
Mixed Non infected	0	N/A
Control infected	4	1 euthanized as it could not move, and other chicken did not show any lesions
103a infected	2	1 euthanized as it could not move, and no lesions or sign seen in another
62a Infected	1	Euthanized as it could not move, and no other lesions seen
Mixed infected	0	N/A

Table3: Number of mortality, and signs and lesion observed

- Control infected group had higher small intestine NE lesion scores (avg= 2.7), 103a probiotic (avg=2), 62a (avg=1.7), and the mixed (avg=1.3).
- No significant difference in organ weight
- infected and non infected control had higher mortality compared to 103a and 62a whereas mixed have 0 mortality

## 4) Alpha diversity of cecum microbiota

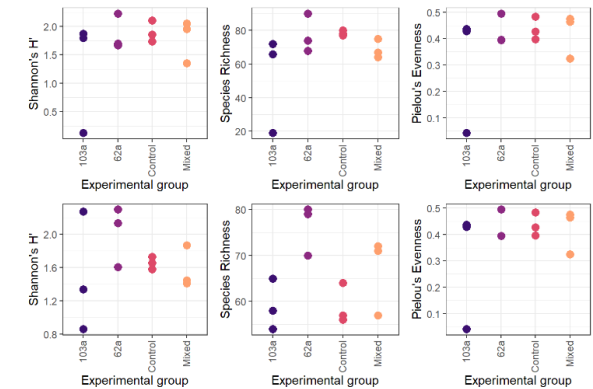


Figure 1: alpha diversity showing Shannon index (H), richness and evenness for cecum sample between infected (top row) and non infected(bottom row) group

- Shannon index was high in infected group compared to non-infected group except for 103a which was decreased.
- 62a had higher H index, richness, and evenness in both infected and non infected experimental groups meaning high species diversity

## Conclusion:

Supplementation of two probiotics in the drinking water for broilers might control the lesions of N.E. Promising positive impacts is observed for both probiotic supplementation in our current pilot trial and will be evaluated in larger feeding trial in future.

## References:

- Khalique, A.; Zeng, D.; Shoaib, M.; Wang, H.; Qing, X.; Rajput, D. S.; Pan, K.; Ni, X. Probiotics Mitigating Subclinical Necrotic Enteritis (SNE) as Potential Alternatives to Antibiotics in Poultry. *AMB Express* **2020**, *10* (1), 1–10. <https://doi.org/10.1186/S13568-020-00989-6/FIGURES/2>.
- J.E. Blajman, L.S. Frizzo, M.V. Zbrun, D.M. Astesana, M.L. Fusari, L.P. Soto, M.R. Rosmini & M.L. Signorini (2014) Probiotics and broiler growth performance: a meta-analysis of randomised controlled trials, *British Poultry Science*, 55:4, 483-494, DOI: 10.1080/00071668.2014.931930