

## An unusual cause of membranous glomerulonephritis in a patient with HIV

Ying Maggie Chen · Luis A. Marcos ·  
Helen Liapis · Thomas H. Steinberg ·  
Aubrey R. Morrison

Received: 3 January 2011 / Accepted: 10 March 2011  
© Springer Science+Business Media, B.V. 2011

**Abstract** A 68-year old Caucasian male with a past medical history of human immunodeficiency virus (HIV) infection presented with acute oliguric renal failure and maculopapular rash. Renal biopsy demonstrated extensive foot process effacement as well as confluent small subepithelial electron-dense deposits, which is diagnostic of membranous glomerulonephritis. Subsequent serological tests showed venereal disease research laboratory test was positive in both serum and cerebral spinal fluid. Following penicillin treatment, the patient's creatinine returned to baseline 4 weeks later. Secondary membranous glomerulonephritis caused by syphilis in patients with HIV is discussed.

**Keywords** Acute kidney injury · Human immunodeficiency virus · Membranous glomerulonephritis · Syphilis

### Case presentation

A 68-year old Caucasian male with a history of human immunodeficiency virus (HIV) infection presented with severe generalized weakness over 1 week, mild lower extremity edema, and decreased urine output for 3 days. He had developed a maculopapular rash on the face and extremities 8 weeks ago. There was no history of previous renal disease, nausea, vomiting, weight loss, arthralgia, dysuria, gross hematuria, or fever. He was diagnosed with HIV 3 years ago and treated with efavirenz, emtricitabine, and tenofovir for the last 7 months. Homosexual activity was the only identified risk factor for HIV. He was started on gabapentin for myelodysplasia 4 weeks ago. Home medications included atipla (efavirenz, emtricitabine and tenofovir), gabapentin, atenolol, venlafaxine, levothyroxine, and olmesartan.

On physical examination, the patient was afebrile and normotensive. He had bilateral 1+ pedal edema, reduced sensation of vibration in lower extremities and diffuse maculopapular rash dense on the trunk, and bilateral upper and lower extremities.

Admission laboratory studies showed that serum creatinine level was 3.37 mg/dl (297  $\mu$ mol/l;

---

Ying Maggie Chen and Luis A. Marcos contributed equally to this work.

---

Y. M. Chen · A. R. Morrison (✉)  
Renal Division, Washington University School  
of Medicine, 8126, 660 S. Euclid Ave.,  
St. Louis, MO 63110, USA  
e-mail: amorriso@dom.wustl.edu

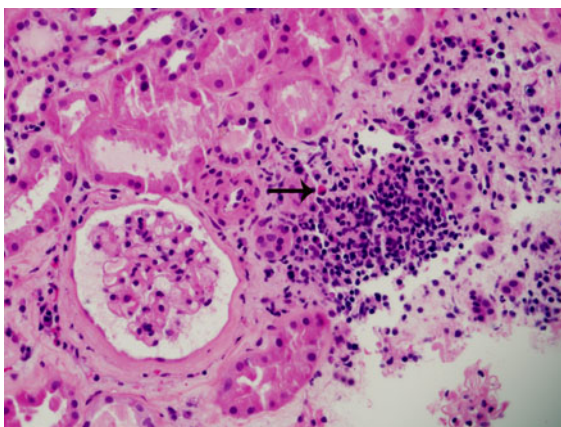
L. A. Marcos · T. H. Steinberg  
Infectious Diseases Division, Washington University  
School of Medicine, St. Louis, MO, USA

H. Liapis  
Department of Pathology and Immunology, Washington  
University School of Medicine, St. Louis, MO, USA

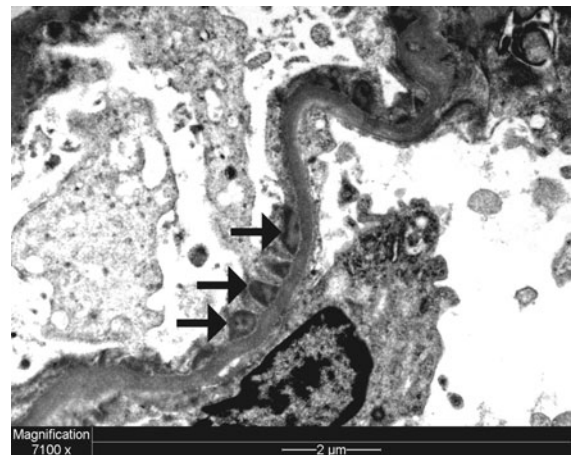
estimated glomerular filtration rate, 19 ml/min/1.73 m<sup>2</sup> according to the Modification of Diet in Renal Disease Study equation). Urinalysis showed 3+ protein. A 24-h urine collection revealed 1.5 g of protein, and spun urine sediment was bland. Serum albumin level was 22 g/l with total serum protein 66 g/l. The erythrocyte sedimentation rate was 92 mm/h. His thyroid-stimulating hormone was normal. Serological test results for hepatitis C virus and hepatitis B virus were negative. His CD4 count was 326 with HIV viral load of less than 48 copies/ml. His renal ultrasound showed mildly increased echogenicity in both kidneys with a normal kidney size without hydronephrosis. Over the next 2 days, despite discontinuing gabapentin, antiviral drugs and intravenous hydration, the patient's creatinine increased to 5.08 mg/dl (447 μmol/l). A kidney biopsy was performed.

In his kidney biopsy, light microscopy showed that none of the glomeruli were sclerosed. There was focal acute interstitial inflammation with eosinophils without evidence of HIV-associated nephropathy (Fig. 1). Unfortunately, the kidney sample was insufficient for immunofluorescence examination. Electron microscopy showed extensive foot process effacement and diffuse, small subepithelial electron dense deposits diagnostic of membranous glomerulonephritis (Fig. 2).

Subsequent serological tests showed that rapid plasma reagin (RPR) titer was 1:256 (it was negative 2 years ago), fluorescent treponemal antibody was



**Fig. 1** Mild interstitial nephritis with eosinophils (*arrow*), neutrophils, and rare white cell casts. Glomeruli appear unremarkable (hematoxylin and eosin ×200)



**Fig. 2** Transmission electron microscopy shows extensive foot process effacement as well as confluent small subepithelial electron dense deposits (*arrows*). The deposits had variegated appearance diagnostic of early membranous glomerulonephritis. There were no typical bell-shaped deposits (*humps*) to suggest post-infectious glomerulonephritis (uranyl acetate staining)

reactive and venereal disease research laboratory (VDRL) test titer was 1:128. Cerebral spinal fluid revealed that VDRL was 1:2 positive. Neurosyphilis was diagnosed and high-dose intravenous penicillin G was administered. Urine output increased significantly 48 h later and creatinine decreased. The patient was seen in the outpatient clinic 4 weeks after completing penicillin therapy. His creatinine had returned to baseline, and the spot urine protein-creatinine ratio was markedly decreased to 0.17 g/g creatinine. Membranous glomerulonephritis was considered secondary to syphilis.

## Discussion

Syphilis is an old disease with substantial resurgence in the past decade. It has been estimated that more than 60% of syphilis cases occur in men who have sex with men. A large portion of patients with syphilis are also HIV positive [1]. The most common presentation of syphilitic renal involvement is proteinuria, and the incidence of proteinuria is about 8% in the patients with secondary syphilis and 7% in those with tertiary syphilis [2]. The syphilitic glomerulopathy includes membranous glomerulopathy (most common) [3], minimal change disease with

interstitial edema [4], rapid progressive glomerulonephritis with crescents [5], mesangial proliferative and post-infectious endocapillary proliferative glomerulonephritis [6], IgA nephropathy [7], renal gumma and amyloid renal disease [8]. In addition, syphilis can cause interstitial nephritis associated with salt-losing nephropathy [9]. The mechanism for membranous nephropathy involves immune complex formation triggered by treponemal antigens [10, 11]. Antitreponemal antibodies were also eluted from kidney tissue [5, 12]. Complete resolution of renal manifestations after penicillin therapy is the rule in the patients with syphilis [13]. It is noteworthy that syphilis can also cause congenital nephrotic syndrome in the infants born from mothers infected with syphilis. Penicillin, if given sufficiently early, results in complete clinical and histological recovery in the affected infants [14].

Acute interstitial nephritis (AIN) caused by tenofovir or gabapentin was also in the differential diagnoses because the renal biopsy showed mild acute interstitial nephritis with eosinophils. Tenofovir is also associated with extensive proximal tubular dysfunction and Fanconi syndrome [15, 16]. However, our patient had been on tenofovir for 7 months with stable renal function, which makes tenofovir an unlikely drug culprit. While there might be a minor superimposed component of AIN from gabapentin started about 4 weeks ago, complete resolution of proteinuria and rapid recovery of renal function following penicillin treatment indicates that syphilitic membranous nephropathy is the major cause for his acute kidney injury.

The most common renal lesion in patients with HIV is HIV-associated nephropathy (HIVAN), which is characterized by a triad of collapsing glomerulopathy, microcystic tubular dilatation, and endothelial cell tubuloreticular inclusions. However, approximately 40% of patients with HIV who develop renal disease do not have HIVAN [17, 18]. Furthermore, there is a trend of decreasing yearly incidence of HIVAN paralleling the use of antiretroviral therapy [19]. Therefore, potentially reversible causes of renal involvement in patients with HIV have to be considered; syphilis is a frequently overlooked cause. Our case underscores the importance of screening for syphilis among patients with HIV in the evaluation of proteinuria.

## References

1. CDC DoSp (2006) Syphilis surveillance report
2. Hermann G, Marr WL (1935) Clinical syphilitic nephropathies. A study of new cases and survey of reported cases. *Am J Syph Neurol* 19:1–29
3. Hunte W, al-Ghraoui F, Cohen RJ (1993) Secondary syphilis and the nephrotic syndrome. *J Am Soc Nephrol* 3:1351–1355
4. Krane NK, Espenan P, Walker PD, Bergman SM, Wallin JD (1987) Renal disease and syphilis: a report of nephrotic syndrome with minimal change disease. *Am J Kidney Dis* 9:176–179
5. Walker PD, Deeves EC, Sahba G, Wallin JD, O'Neill WM Jr (1984) Rapidly progressive glomerulonephritis in a patient with syphilis. Identification of antitreponemal antibody and treponemal antigen in renal tissue. *Am J Med* 76:1106–1112
6. Bhorade MS, Carag HB, Lee HJ, Potter EV, Dunea G (1971) Nephropathy of secondary syphilis. A clinical and pathological spectrum. *JAMA* 216:1159–1166
7. Tang S, Chan KW, Chan TM, Lai KN (1999) Skin lesions, hepatitis, and nephropathy in a 30-year-old man. *Am J Kidney Dis* 34:380–383
8. Thompson L (1920) Syphilis of the kidney. *JAMA* 75:17–20
9. Chen YC, Lee N, Chang CT, Wu MS (2005) Salt loss and hyponatraemia in a patient with syphilitic nephritis. *Nephrol Dial Transplant* 20:1248–1250
10. O'Regan S, Fong JS, de Chadarevian JP, Rishikof JR, Drummond KN (1976) Treponemal antigens in congenital and acquired syphilitic nephritis: demonstration by immunofluorescence studies. *Ann Intern Med* 85:325–327
11. Tourville DR, Byrd LH, Kim DU, Zajd D, Lee I, Reichman LB, Baskin S (1976) Treponemal antigen in immunopathogenesis of syphilitic glomerulonephritis. *Am J Pathol* 82:479–492
12. Gamble CN, Reardan JB (1975) Immunopathogenesis of syphilitic glomerulonephritis. Elution of antitreponemal antibody from glomerular immune-complex deposits. *N Engl J Med* 292:449–454
13. Hruby Z, Kuzniar J, Rabczynski J, Bogucki J, Steciwko A, Weyde W (1992) The variety of clinical and histopathologic presentations of glomerulonephritis associated with latent syphilis. *Int Urol Nephrol* 24:541–547
14. Basker M, Agarwal I, Bendon KS (2007) Congenital nephrotic syndrome—a treatable cause. *Ann Trop Paediatr* 27:87–90
15. Horberg M, Tang B, Towner W, Silverberg M, Bersoff-Matcha S, Hurley L, Chang J, Blank J, Quesenberry C Jr, Klein D (2010) Impact of tenofovir on renal function in HIV-infected, antiretroviral-naïve patients. *J Acquir Immune Defic Syndr* 53:62–69
16. Agarwala R, Mohan S, Herlitz LC, Cheng JT (2010) The case: 41-year-old HIV patient with proteinuria and progressive renal dysfunction. Tenofovir toxicity. *Kidney Int* 77:475–476
17. Ross MJ, Klotman PE (2002) Recent progress in HIV-associated nephropathy. *J Am Soc Nephrol* 13:2997–3004

18. Wyatt CM, Klotman PE, D'Agati VD (2008) HIV-associated nephropathy: clinical presentation, pathology, and epidemiology in the era of antiretroviral therapy. *Semin Nephrol* 28:513–522
19. Berliner AR, Fine DM, Lucas GM, Rahman MH, Racusen LC, Scheel PJ, Atta MG (2008) Observations on a cohort of HIV-infected patients undergoing native renal biopsy. *Am J Nephrol* 28:478–486