



Monocularly Deprived Cats: Improvement of the Deprived Eye's Vision by Visual Decortication

S. Murray Sherman

Science, New Series, Vol. 186, No. 4160 (Oct. 18, 1974), 267-269.

Stable URL:

<http://links.jstor.org/sici?sici=0036-8075%2819741018%293%3A186%3A4160%3C267%3AMDCIOT%3E2.0.CO%3B2-V>

Your use of the JSTOR archive indicates your acceptance of JSTOR's Terms and Conditions of Use, available at <http://www.jstor.org/about/terms.html>. JSTOR's Terms and Conditions of Use provides, in part, that unless you have obtained prior permission, you may not download an entire issue of a journal or multiple copies of articles, and you may use content in the JSTOR archive only for your personal, non-commercial use.

Each copy of any part of a JSTOR transmission must contain the same copyright notice that appears on the screen or printed page of such transmission.

Science is published by American Association for the Advancement of Science. Please contact the publisher for further permissions regarding the use of this work. Publisher contact information may be obtained at <http://www.jstor.org/journals/aaas.html>.

Science

©1974 American Association for the Advancement of Science

JSTOR and the JSTOR logo are trademarks of JSTOR, and are Registered in the U.S. Patent and Trademark Office. For more information on JSTOR contact jstor-info@umich.edu.

©2003 JSTOR

10. M. W. Hu, W. E. Bondinell, D. Hoffmann, *J. Labelled Compd.* **10**, 79 (1974).
11. L. K. Keefer and P. P. Roller, *Science* **181**, 1245 (1973).
12. S. S. Mirvish, L. Wallcave, M. Eager, P. Shubik, *ibid.* **180**, 65 (1972).
13. G. Lipp and U. Döllberg, *Beitr. Tabakforsch.* **2**, 345 (1964).
14. G. E. Moore, L. L. Bissinger, E. C. Proehl, *J. Am. Geriat. Soc.* **1**, 497 (1953); E. L. Wynder, I. J. Bross, R. M. Feldman, *Cancer* **10**, 1300 (1957); Royal College of Physicians, London, *Smoking and Health* (Pitman, London, 1962); *U.S. Public Health Rep. No. 1103* (1964); Royal College of Physicians, London, *Smoking and Health Now* (Pitman, London, 1971); U.S. Department of Health, Education, and Welfare, *Health Services and Mental Health Administration Publication No. 73-8704* (1973).
15. F. G. Bock, *Cancer Res.* **28**, 2363 (1968); B. L. Van Duuren, *ibid.*, p. 2357; E. L. Wynder and D. Hoffmann, *Cancer* **24**, 289 (1969).
16. T. C. Tso and D. W. de Jong, *Abstracts of Cigar Research Council, Inc., Research Seminar Program, February 1973*, p. 9.
17. Supported by NIH grant CA 012376-03. This is report No. 30 of "Chemical studies on tobacco smoke."

2 May 1974

Monocularly Deprived Cats: Improvement of the Deprived Eye's Vision by Visual Decortication

Abstract. *Monocularly deprived cats were tested for visual perimetry before and after visual cortex lesions. Such a lesion greatly enhances the deprived eye's performance and impairs that of the nondeprived eye so that the pronounced preoperative interocular asymmetry is lost postoperatively. Apparently this destruction of abnormal corticotectal pathways allows the expression of previously suppressed, normal retinotectal pathways.*

A cat raised with the lids of one eye sutured together develops severe abnormalities in its geniculocortical system. In such a cat, stimulation of the deprived eye drives very few cortical neurons (1, 2) or lateral geniculate Y cells, although it does drive X cells in apparently normal numbers (3). Also, the geniculate cells innervated by the deprived eye are abnormally small (4, 5). These deficits are, however, limited to the binocular segment of the geniculocortical system (5, 6). In the monocular segment (6), the "deprived" geniculate neurons are of normal size (5), and the deprived eye drives the normal complement of both Y cells (3) and, apparently, cortical cells (2).

Recently, I have shown a correlation between these geniculocortical deficits and visual behavior in monocularly deprived cats. On a visual perimetry test, these cats behave with the deprived eye as if they see objects in the monocular segment of visual field, but are completely blind for the binocular segment (7). While this behavior could be predicted from the geniculocortical and corticotectal deficits, the retinotectal pathways of monocularly deprived cats seem to develop normally (8, 9). This is of considerable interest because normally reared cats without visual cortex can perform on this perimetry test by means of their retinotectal pathways (10, 11). Furthermore, such decorticate cats apparently see the entire ipsilateral hemifield with each eye (11).

Since the deprived eye has apparently normal retinotectal input (8, 9), it might

be expected to view the entire 90° of ipsilateral hemifield and not just the peripheral crescent that represents the monocular segment. Wickelgren and Sterling (8) provided electrophysiological evidence that in monocularly deprived cats the deprived eye's retinotectal input is somehow suppressed by the abnormal corticotectal pathway, and that this suppression is abolished by decortication.

I now describe a behavioral analog for the Wickelgren and Sterling data. I tested monocularly deprived cats before and after visual cortical lesions and determined that these lesions significantly improve nonlearned visual behavior guided by the deprived eye.

Three cats were studied, and previous

reports provide details on the surgical, behavioral, and histological techniques (7, 11). At 8 days of age, each cat had one eye closed by lid suture, the left eye for cat LMD7 and the right eye for cats RMD8 and RMD11. At 10 to 12 months of age all had their eyes opened prior to testing. I evaluated their binocular and monocular fields of view by means of a simple perimetry test (7). In brief, the cat fixated on one object while a second visual stimulus was introduced into a limited portion of the visual field. Every 15° sector of the horizontal extent of visual field was repeatedly tested and the cat's response to the second stimulus, orientation or lack of orientation to it, determined the extent of functional visual field. As a control, the level of these orientations for each sector was compared to a baseline of "spontaneous" orientations in the absence of a second stimulus—that is, the "blank responses" in (7). In addition, the cats were tested for their ability to follow moving targets and for visual placing responses (7).

After initial testing, each cat underwent decortication (11). Cat LMD7 had most of the occipitotemporal cortex bilaterally aspirated, and this included all of the visual recipient zones of both the lateral geniculate nucleus and also the pulvinar and lateral posterior thalamic complex (11, 12). In addition, this cat had a split of the commissure of the superior colliculus to permit visual functioning of the midbrain (10, 11). Cats RMD8 and RMD11 had smaller bilateral lesions involving mostly just the lateral geniculate cortical zone (11, 12) (that is, this included all of areas 17 and 18, and most of area 19). In these

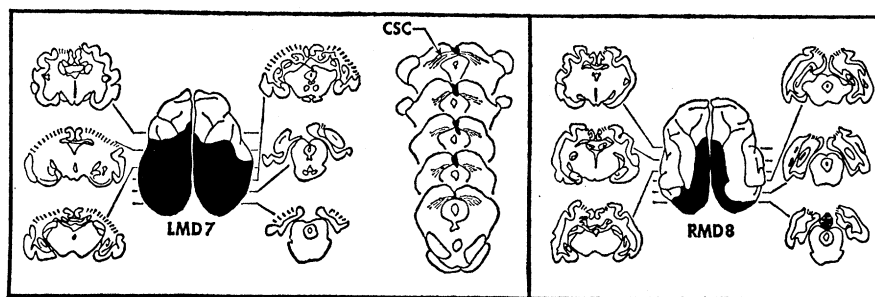


Fig. 1. Reconstruction of lesions for cats LMD7 and RMD8. In both, the lateral geniculate showed retrograde degeneration throughout its extent. The cortical lesion in LMD7 involved most of the occipitotemporal cortex, including all known projection zones of the lateral geniculate and pulvinar and lateral posterior thalamic complex (12). Also in this cat, the commissure of the superior colliculus (CSC) was completely transected, except for a few surviving fibers at the extreme anterior and posterior borders. For RMD8, dorsally the lesion involved all of the lateral gyrus, and medially it involved all cortex superior to the fundus of the splenial sulcus; thus all known lateral geniculate recipient zones were ablated, but the visual projections of the pulvinar and lateral posterior complex were largely spared (12).

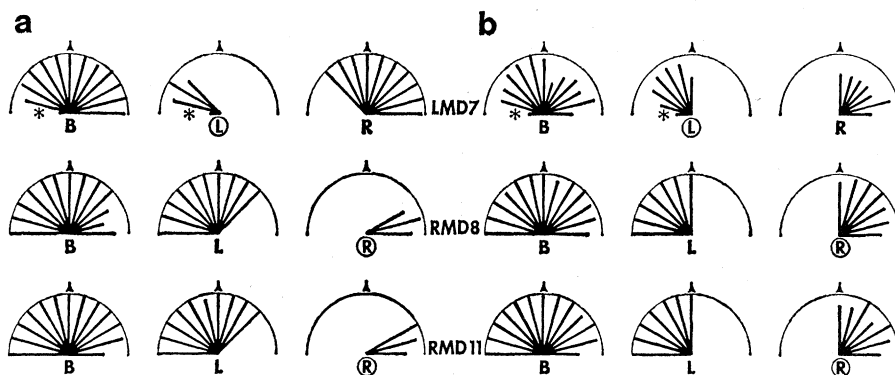


Fig. 2. Horizontal extent of visual field perimetry for each cat pre- and postoperatively. Each cat was tested binocularly (B) and monocularly with the left (L) or right (R) eye. The deprived eye is indicated by a circled L or R. The black bars indicate in polar coordinates the positive response levels for every 15° sector of visual field, and the semicircles show the 100 percent levels. The positive response levels (G percent) have been normalized against the level of spontaneous turning (B percent) by the relationship $(G - B)/(100 - B)$ percent if $G > B$; the normalized value is zero if $B \geq G$ [for details see (7)]. Every sector (bilaterally) to 120° of the fixation point (indicated by a triangle) was tested. The levels marked by asterisks for cat LMD7 are not significantly higher than the spontaneous turning levels, while all other levels are significantly higher ($P > .05$ and $P < .001$, respectively, on a chi-square test). (a) Preoperative testing. (b) Postoperative testing, following visual decortication.

cats with the smaller cortical aspiration, no collicular commissure split was deemed necessary, since such a split was not needed to permit visual behavior in normally reared cats with similar cortical lesions (10, 11). I am retaining cat RMD8 for further behavioral study, but LMD7 and RMD11 have been killed and their lesions were histologically confirmed (see Fig. 1). I assume that the lesions of cats RMD8 and RMD11 are practically identical, both because their postoperative behavior was indistinguishable and also because of the excellent visualization during surgery of RMD8.

Figure 2 illustrates the pre- and postoperative behavior of all three cats. Preoperatively, all showed typical monocularly deprived visual perimetry (Fig. 2a) (7). The nondeprived eye had a normal field of view while that of the deprived eye included only the monocular segment. After the cortical lesions, a dramatic change in perimetry occurred in all three cats (Fig. 2b). Now no qualitative interocular differences were detectable, and each eye saw the entire ipsilateral hemifield. This represents a dramatic improvement in overall visually guided behavior for the deprived eye. Not only was the extent of field doubled for all three cats, but cats RMD8 and RMD11 with the deprived eye postoperatively had noticeably brisker visual following and placing responses than they had preoperatively (7). That is, they could follow moving

objects more consistently and at higher speeds, and they more accurately and consistently extended their forepaws to anticipate contact when lowered toward a visible surface. The overall behavior of cat LMD7 was qualitatively more sluggish with either eye than that of RMD8 or RMD11.

These improved responses for the deprived eye and lack of interocular asymmetry were apparent in cats RMD8 and RMD11 within the first postoperative week. Cat LMD7, however, was blind for 2 to 3 weeks postoperatively, and it is interesting that I detected visual behavior for its deprived eye several days before I could ascertain any for the nondeprived eye.

In terms of this postoperative time course of visually guided behavior, lack of interocular asymmetry, size of visual fields, and overall briskness of response, these monocularly deprived cats were indistinguishable postoperatively from similarly lesioned, normally reared cats that I previously tested and described (11). I then suggested that such cats probably use retinotectal pathways for visually guided behavior, since geniculocortical pathways are destroyed; and that such cats behave on these tests as if each eye's temporal retina were nonfunctional. This obtains presumably because the retinotectal pathways nearly exclusively contain crossed nasal retinal fibers (13). The fact that normal cats use temporal retina on these tests indicates that geniculocortical

pathways are used, but it cannot be determined whether the midbrain also normally contributes to this behavior. My present data suggest that, at least for monocularly deprived cats, geniculocortical pathways dominate in this visual behavior and that retinotectal pathways are somehow suppressed. This suppression is overcome by eliminating the abnormal visual cortex, a phenomenon previously demonstrated electrophysiologically (8) and now demonstrated behaviorally.

In all three cats the improvement in visual behavior for the deprived eyes was quite dramatic after visual decortication. I emphasize that only nonlearned visually guided behavior was tested, and I did not evaluate such behavior as learned visual discrimination. Monocularly deprived cats, when forced to use their deprived eyes, perform very poorly on pattern discrimination (14), and it would be interesting to determine whether cortical lesions might improve such performance. Of course, a cat with a lesion as large as that of LMD7 would not be expected to perform pattern discriminations (15, 16), and it is unclear how a normally reared cat with a lesion such as those of RMD8 and RMD11 would perform (16, 17). Finally, the minimum cortical removal that would improve perimetry for the deprived eye has not yet been determined. If, for instance, this removal requires the involvement of only area 17, one might anticipate significant improvement in visual discrimination of patterns by the deprived eye since such a cortical removal in normally reared cats has little effect on discrimination of most tested patterns (16).

S. MURRAY SHERMAN

Department of Physiology,
University of Virginia
School of Medicine,
Charlottesville 22901

References and Notes

1. T. N. Wiesel and D. H. Hubel, *J. Neurophysiol.* **26**, 1003 (1963); *ibid.* **28**, 1029 (1965); L. Ganz, M. Fitch, J. A. Satterberg, *Exp. Neurol.* **22**, 614 (1968).
2. S. M. Sherman, R. W. Guillery, J. H. Kaas, K. J. Sanderson, *J. Comp. Neurol.*, in press.
3. S. M. Sherman, K.-P. Hoffmann, J. Stone, *J. Neurophysiol.* **35**, 532 (1972).
4. T. N. Wiesel and D. H. Hubel, *ibid.* **26**, 978 (1963).
5. R. W. Guillery and D. J. Stelzer, *J. Comp. Neurol.* **139**, 413 (1970).
6. The binocular segment of the visual field is that central portion normally viewed by both eyes. The monocular segments on either side are the peripheral crescents viewed only by ipsilateral, nasal retina. The binocular segment of the lateral geniculate nucleus and striate cortex include those neurons with re-

- ceptive fields in the binocular segment of visual field, and the monocular segment of these structures is similarly defined. For example, in the geniculate, the binocular segment includes the medial, laminated portion including all of lamina A1 and corresponding parts of the A and C laminae; the monocular segment is the lateral region of the nucleus where the A and C laminae extend beyond lamina A1.
7. S. M. Sherman, *Brain Res.* **49**, 25 (1973); **73**, 491 (1974).
 8. B. G. Wickelgren and P. Sterling, *Nature (Lond.)* **224**, 1032 (1969).
 9. K.-P. Hoffman and S. M. Sherman, *J. Neurophysiol.*, in press.
 10. J. M. Sprague, *Science* **153**, 1544 (1966).
 11. S. M. Sherman, *ibid.* **185**, 355 (1974).
 12. L. J. Garey and T. P. S. Powell, *Proc. R. Soc. Lond. Ser. B* **169**, 107 (1967); A. M. Graybiel, *Brain Res.* **44**, 99 (1972); A. C. Rosenquist, S. B. Edwards, L. A. Palmer, *ibid.*, in press. For a summary, see J. M. Sprague, G. Berlucchi, G. Rizzolatti, in *The Handbook of Sensory Physiology*, R. Jung, Ed. (Springer-Verlag, Berlin, 1973), vol. 7/3b, p. 30, figure 3.
 13. P. Sterling, *Brain Res.* **54**, 347 (1973).
 14. L. Ganz and M. Fitch, *Exp. Neurol.* **22**, 638 (1968); P. B. Dews and T. N. Wiesel, *J. Physiol. (Lond.)* **206**, 437 (1970); G. Rizzolatti and V. Tradardi, *Exp. Neurol.* **33**, 181 (1971); K. L. Chow and D. L. Stewart, *ibid.* **34**, 409 (1972).
 15. K. U. Smith, *J. Genet. Psychol.* **53**, 251 (1938); M. S. Loop, S. M. Sherman, D. D. Feeny, E. E. Kicliter, *Proceedings of the Association for Research in Vision and Ophthalmology* (1974).
 16. R. W. Doty, *J. Comp. Neurol.* **143**, 341 (1971).
 17. S. S. Winans, *J. Comp. Physiol. Psychol.* **74**, 167 (1971); C. C. Wood, P. D. Spear, J. D. Braun, *Brain Res.* **66**, 443 (1974).
 18. Supported by grant GB-38264 from the National Science Foundation. I thank L. Smith for technical assistance.

6 June 1974

cuit across each quarter-bladder were used to measure sodium transport (1, 6). After a stable baseline was obtained (for both potential difference and short-circuit current), *d*-aldosterone (Calbiochem) was added (in a methanol carrier) to the serosal medium for the experimental quarter-bladder (usual final concentration, $10^{-6}M$); the serosal medium (5 ml) for the control quarter-bladder received the same volume (10 μ l) of the methanol carrier (without aldosterone). (Similar results can be obtained with aldosterone concentrations of $\sim 10^{-7}M$; a concentration $> 10^{-8}M$ is usually needed to stimulate short-circuit current.)

Each hemibladder studied biochemically was monitored with an electrophysiological experiment performed on the corresponding hemibladder from the same toad, incubated under the same experimental and control conditions.

After one of each pair of hemibladders was removed for the electrophysiological studies described above, the corresponding hemibladder was cut into two to four parts for biochemical studies. Each piece of tissue (wet weight, ~ 80 mg) was incubated at 24° to $25^{\circ}C$ with 2 ml of DBR containing [^{35}S]methionine (Amersham/Searle) and the specific additions were indicated for each experiment. In most studies the standard DBR was modified by adding nine or four parts of DBR to one part of $NaHCO_3$ -free, methionine-free, minimal Eagle's medium (MEM; Microbiological Associates), and was adjusted to pH 7.9 to 8.0 with tris buffer.

After incubation, the epithelial cell layer was removed by scraping, washed twice with cold DBR, and collected by centrifugation at 600g for 1 minute. This washed pellet was then resuspended in 1 ml of lysing buffer (pH 8.5) consisting of 0.1M glycine, 0.1M NaCl, 0.01M EDTA, 0.1 percent sodium dodecyl sulfate (SDS), and 0.01M β -mercaptoethanol. The suspension was then frozen and thawed successively, three times, and dissolved by heating at $50^{\circ}C$ with agitation for 1 hour, and then at $100^{\circ}C$ in a water bath for 10 to 15 minutes. The solution was centrifuged, and the residue was extracted twice with lysing buffer at $100^{\circ}C$. Little residue remained after this procedure. Four volumes of cold acetone were added to the supernatant, and the solution was allowed to stand

Aldosterone-Induced Protein in Toad Urinary Bladder

Abstract. *Simultaneous electrophysiological and biochemical experiments demonstrated a specific aldosterone-induced protein in paired urinary hemibladders isolated from the toad Bufo marinus. Whenever aldosterone stimulated short-circuit current, aldosterone specifically increased [^{35}S]methionine incorporation into a low-molecular-weight protein (about 12,000). Comparative studies with dexamethasone and insulin and inhibitory studies with spironolactone and actinomycin D suggest mineralocorticoid specificity.*

Aldosterone and other mineralocorticoids stimulate transepithelial sodium transport across the isolated toad urinary bladder (1). This stimulation is characterized by a lag of 30 to 90 minutes before sodium transport increases, and by sensitivity to inhibition by actinomycin D, puromycin, and cycloheximide (2). The stimulation is not produced by glucocorticoids (1) and can be abolished by spironolactones which displace aldosterone from its nuclear binding sites (3). On the basis of these data and by analogy with other model systems of steroid hormone action, one widely held hypothesis (4) suggests that aldosterone acts within the cell nucleus to induce the synthesis of a specific RNA, which then codes for the synthesis of a specific protein (aldosterone-induced protein; AIP). This protein, which may be a membrane component, a permease, or a carrier molecule, is responsible for the increased sodium transport induced by the hormone. However, there has not yet been any direct proof of this hypothesis; neither a specific aldosterone-induced RNA (5), nor a specific AIP (2, 4) has been demonstrated. This report presents evidence from toad urinary bladders (i) that aldosterone specifically induces the synthesis of a low-molecular-weight protein or poly-

peptide and (ii) that the production of this AIP is correlated with the stimulation of sodium transport.

Female toads (*Bufo marinus*) were obtained from the Dominican Republic and maintained on 0.6 percent NaCl solution for 48 hours before use. The paired, excised hemibladders were placed in continuously aerated, doubly buffered Ringer solution (DBR; see below) at room temperature (22° to $24^{\circ}C$) for 15 to 30 minutes before measurements were begun. The standard doubly buffered Ringer solution (DBR) consisted of 98.2 mM NaCl, 3.4 mM KCl, 4.9 mM Na_2HPO_4 , 1.0 mM $CaCl_2$, 2.5 mM $NaHCO_3$, and 5 mM dextrose, along with penicillin (50 unit/ml), streptomycin (50 μ g/ml); and phenol red (0.01 percent) as pH indicator. The pH was 7.9 to 8.1, and the osmolality was 210 to 220 milliosmoles per kilogram.

A modified Lucite double chamber was used for the electrophysiological studies (6). One of each pair of hemibladders was mounted across the entire chamber, so that a single hemibladder provided an experimental and a control quarter bladder. Each quarter-bladder isolated its own serosal and mucosal compartments (cross-sectional areas of 2.3 cm 2). The transepithelial potential difference and the short-cir-