The Effect of Cortical and Tectal Lesions on the Visual Fields of Binocularly Deprived Cats

S. MURRAY SHERMAN
Department of Physiology, University of Virginia School of Medicine, Charlottesville, Virginia 22901

ABSTRACT The visual fields of seven cats raised with binocular lid suture were measured before and after various neural lesions. Each of the cats preoperatively responded with each eye to stimuli from 90° ipsilateral through to the midline. A transection of the optic chiasm rendered one cat blind on the visual field tests. Large bilateral occipito-temporal cortical ablations (4 cats) did not measurably affect orienting responses or the extent of visual field. Unilateral occipito-temporal cortical ablations (2 cats) also had no affect on the visual fields, but subsequent ablations of the contralateral superior colliculus produced permanent blindness in the hemifield contralateral to the ablated tectum. These two cats also were apparently blind with the eye contralateral to the ablated tectum; but with the other eye, the cats retained their preoperative orienting responses. These data are consistent with the hypothesis that, with early binocular deprivation, cats develop dependence upon retinotectal and not thalamocortical pathways for visually guided orienting behavior.

Cats raised to adulthood with binocular eyelid closure have deficient visual orienting behavior. With monocular viewing, the visual orienting responses are limited to stimuli in the ipsilateral hemifield (corresponding to nasal retina), and the cat can follow or track horizontally moving objects only if they are directed from the center to the ipsilateral periphery (see fig. 1 and Sherman, '73, '74a, for details). This is contrasted to behavior in a normal cat which, with only one eye open, orients to stimuli from 90° ipsilateral to 45° contralateral and follows objects moving in either horizontal direction (see the preceding paper, Sherman, '77, and Sherman, '73, for details). That is, the binocularly deprived cat uses nasal retina nearly exclusively for this behavior whereas a normal cat uses nasal and temporal retina nearly equally. With binocular viewing on these tests of visual orienting behavior, the deprived cat shows no gross evidence of abnormalities.

These deficits in the binocularly deprived cats are remarkably similar to those described in the preceding paper (Sherman, '77) for normally reared cats made dependent upon retinotectal pathways for visually guided behavior. That is, a normally reared cat with a bilateral visual cortex ablation (plus a split of the collicular commissure for large cortical lesions) orients well to stimulation of nasal retina but poorly if at all to stimulation of temporal retina.

This has led to the hypothesis (Sherman, '72, '73, '74a,b), that binocularly deprived cats depend upon retinotectal pathways for orienting behavior because of deficient development of the geniculo-cortical pathways (Wiesel and Hubel, '65; Sherman et al., '72). The retinotectal pathways in these cats seem to develop normally (Hoffmann and Sherman, '75). The present study tests this hypothesis by observing the effects of cortical and tectal lesions on visual orienting behavior in these cats. The hypothesis is supported by data which indicate that large cortical lesions do not grossly affect visual orienting ability, whereas tectal lesions produce a permanent field blindness.

MATERIALS AND METHODS

Subjects

Seven cats, born and reared in the labo-

TABLE 1

Cat	Surgery
BD1	1. At 24 months postnatal, split the optic chiasm. Sacrifice after 12 additional months.
BD5, BD11, BD12, BD18	1. At 14 to 22 months postnatal, remove occipito-temporal cortex. Sacrifice after 6 to 7 additional months.
BD6	1. At 19 months postnatal, remove right occipito-temporal cortex. 2. After 3 further months, remove left superior colliculus. Sacrifice after 6 additional months.
BD13	1. At 12 months postnatal, remove left occipito-temporal cortex. 2. After 5 further months, remove right superior colliculus. Sacrifice after 9 additional months.

ratory, were studied. On the eighth postnatal day each had the lids of both eyes sutured together (Wiesel and Hubel, '63). Care was taken to ensure that no openings occurred in the lids until they were parted for behavioral testing at 9 to 16 months postnatal.

Methods

The surgical, behavioral and histological methods used were identical to those described in the preceding paper (Sherman, '77). Each cat was tested before and after various neural lesions, and table 1 summarizes the lesions for each cat. Cat BD1 underwent a midsagittal transection of the optic chiasm; cats BD5, BD11, BD12, and BD18 had a bilateral ablation of occipito-temporal cortex; and cats BD6 and BD13 had a unilateral ablation of the occipito-temporal cortex followed in a second operation by an ablation of the contralateral superior colliculus. The occipito-temporal cortical lesion was designed to equal the size of the same lesions described in the previous paper (Sherman, '77).

RESULTS

Preoperative fields of binocularly deprived cats

These cats oriented only to stimulation of nasal retina, and they did so less accurately and briskly than normal cats, (Sherman, '73, '74a). Very little intersubject variability was evident on the visual field tests. Figure 1 summarizes this by showing the combined average response levels for the seven cats of this study. As in figure 1 of the previous paper (Sherman, '77), this summary figure shows response levels, each of which represents the mean of seven values (1 per cat), and the standard errors of these means range from 2% to 10%. Consistent with the lack of orientation evoked by stimulation of temporal retina is the observation that, with monocular viewing, these cats followed horizontally moving targets only if directed from the midline to the periphery ipsilateral to the open eye (Sherman, '73). Unlike the decorticate cats with collicular disconnection described in the previous paper (Sherman, '77), these deprived cats during monocular viewing showed no tendency to orient spontaneously into the contralateral hemifield.

Optic chiasm transection

The midsagittal transection of the optic chiasm was complete in BD1 as judged both by gross inspection of the brain before sectioning and by the histological material. For the entire 12-month postoperative survival period, this animal appeared totally blind on all tests of visually guided orienting behavior, and this is summarized in figure 2. The apparently intact fibers from temporal retina, which are mainly directed into the geniculo-cortical pathways, are insufficient to subserve orienting responses as judged by this behavioral technique.

Bilateral occipito-temporal cortex ablations

Cats BD5, BD11, BD12, and BD18 each underwent a one-stage, bilateral ablation

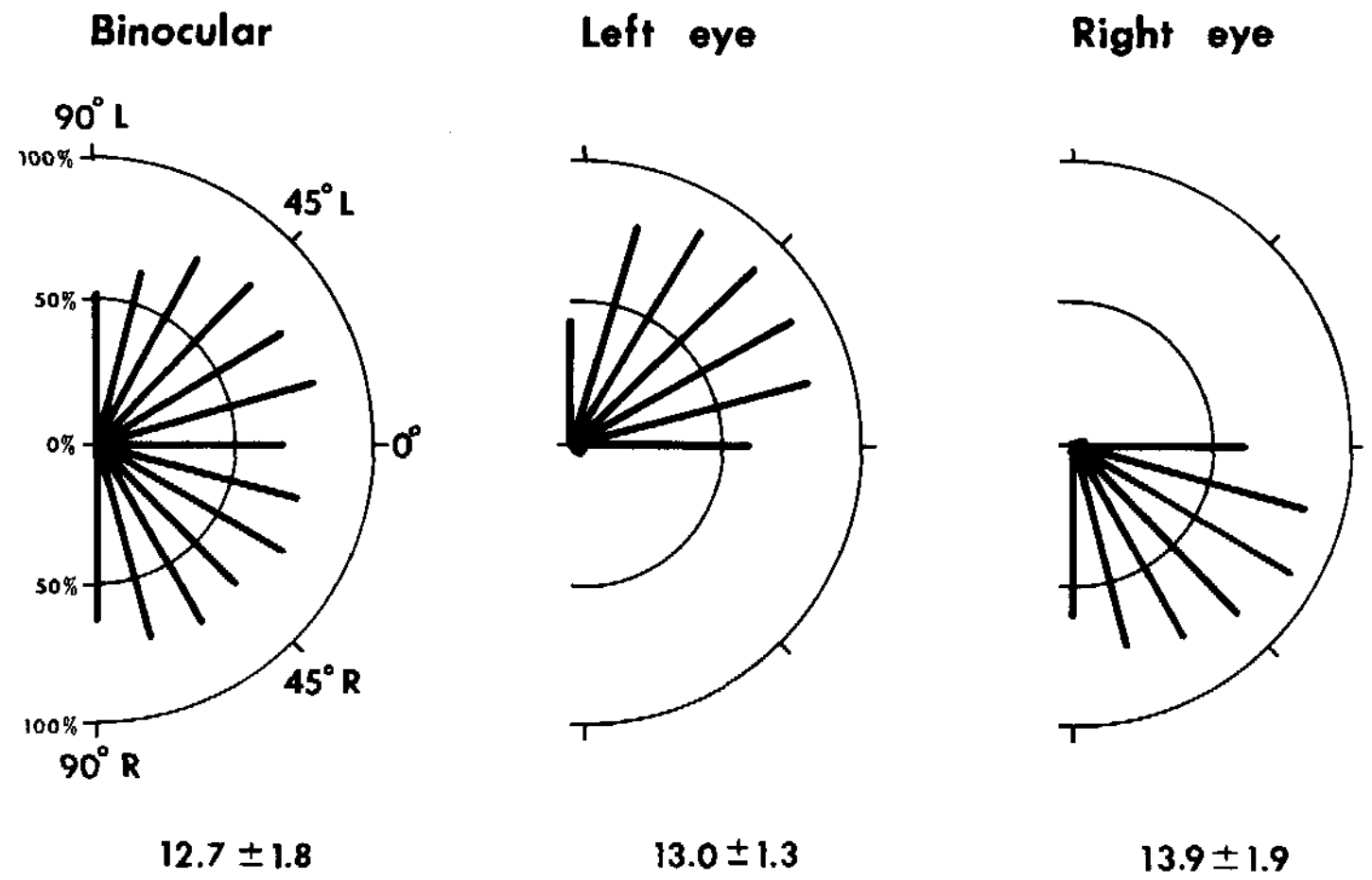

Fig. 1 Typical visual fields for cats reared with binocular eyelid suture (see text and Sherman, '73, '74a). The polar plots represent the normalized response levels for each 15° sector of visual field, and the two semicircles represent the 50% and 100% response levels. Each response level for each sector represents an average of the separate values computed for the seven cats. The standard errors for these means range from 2% to 10%. The numbers below each plot represent the level of spontaneous orienting (mean ± standard error). These spontaneous levels were computed in the same way as were the response levels shown in the plots. The sectors of visual field beyond 90° were also routinely tested (cf. Sherman, '73, '74a), but stimuli there elicited responses so rarely that they have been omitted from this and succeeding figures.

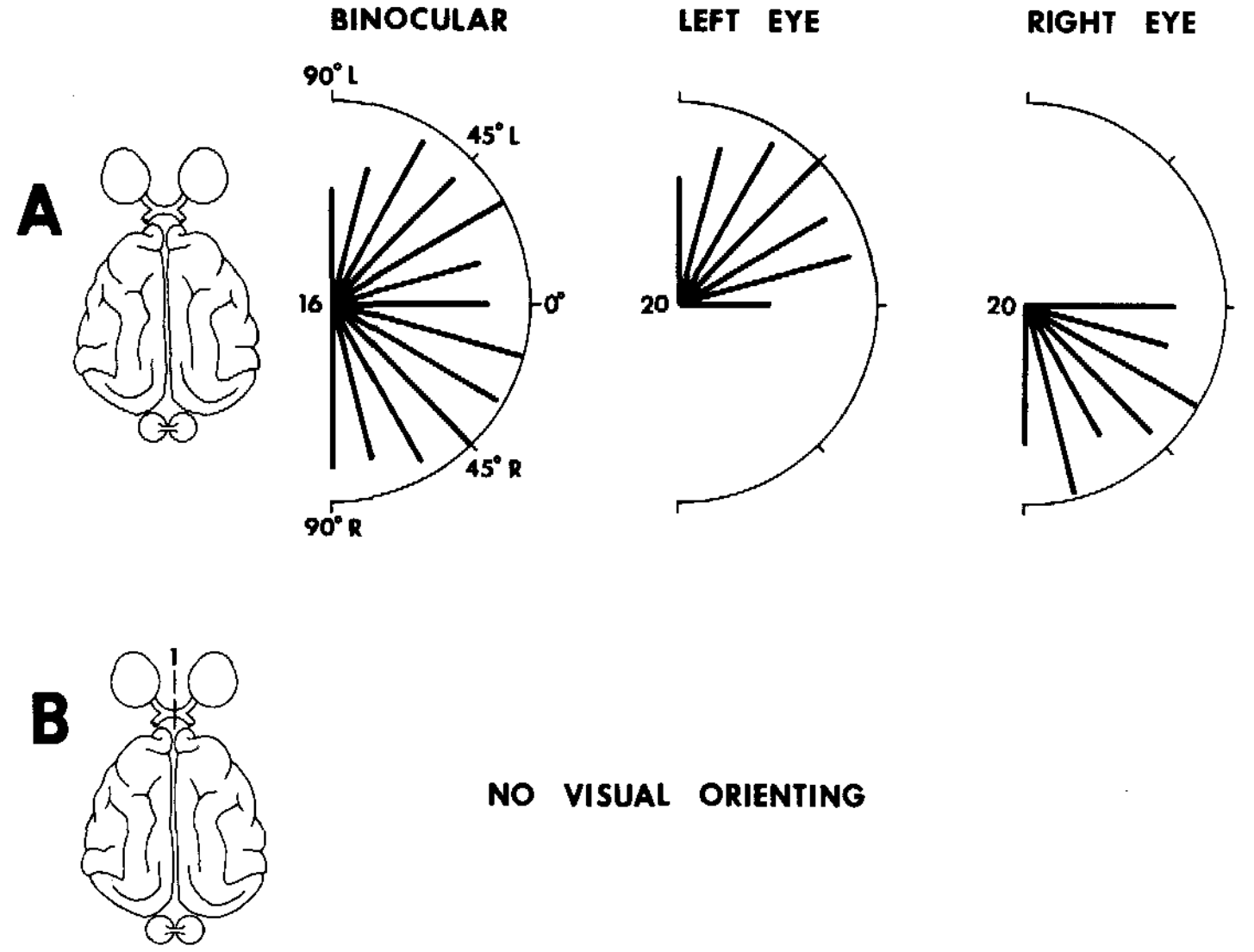

Fig. 2 Visual fields for BD1. The conventions for the polar plots are the same as in figure 1 except that the numbers at the origin of each plot represent the level of spontaneous orientations. A. Preoperative fields. B. Following midsagittal transection of the optic chiasm, BD1 failed to demonstrate visual orienting responses.

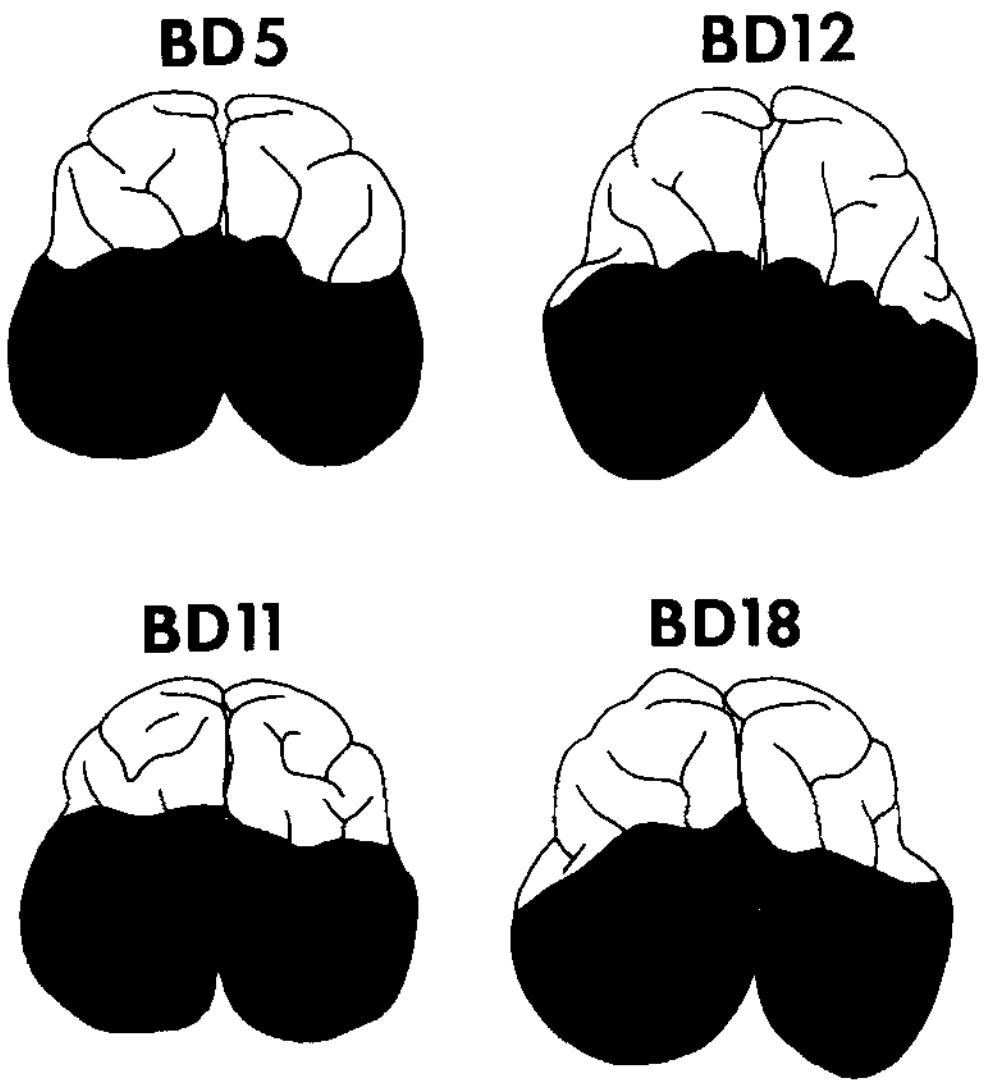

Fig. 3 Summary of cortical ablations as seen dorsally in BD5, BD11, BD12 and BD18. The lesions are reconstructed in detail for BD5 and BD12 in figure 4. Retrograde degeneration was evident throughout the lateral geniculate nuclei, and probably also throughout the pulvinar nuclei, in these cats (see text).

of occipito-temporal cortex. These lesions are summarized from a dorsal view in figure 3, and no significant variability in lesion size was noted among the cats. Two of the lesions (for BD5 and BD12) are reconstructed in detail in figure 4. These lesions are approximately of the same extent as those of the previous paper (Sherman, '77). Each of these cats had complete retrograde degeneration throughout the dorsal lateral geniculate nuclei (see also below). With bilateral lesions, pulvinar degeneration was difficult to assess, but apparently also obtained throughout.

The cats' testing began two to four weeks postoperatively. Irrespective of any variability of lesion extent among the cats, there were no detectable postoperative differences in their visually guided orienting behavior. In fact, the extensive lesions, which render normally reared cats blind on these tests (see the preceding paper, Sherman, '77), had no detectable effect postoperatively (figs. 5-8). Two conclusions are drawn from this. First, this is consistent with the hypothesis that binocularly deprived cats have not developed dependence upon thalamocortical pathways for this behavior. Second, the sort of intercollicular suppression that obtains in normally reared cats and that prevents visually guided orientation after large decortication apparently does not develop in the binocularly deprived cats. This latter conclusion derives from the fact that, in the deprived, decorticate cats, a collicular commissure transection is not needed to allow the expression of visual orientation.

Unilateral occipito-temporal cortex and collicular lesions

Cats BD6 and BD13 each had a unilateral occipito-temporal lesion followed three to five months later with an ablation of the contralateral superior colliculus. In BD6, these ablations involved the right cortex and left colliculus; in BD13, they involved the left cortex and right colliculus. The lesions are reconstructed in figures 9 and 10, and are roughly equal in extent to those of the previous paper (Sherman, '77). Both cats showed clear retrograde degeneration throughout the dorsal lateral geniculate and pulvinar nuclei ipsilateral to the cortical lesions. Figure 11 illustrates this for the lateral geniculate nuclei of BD6. It is interesting to note that, even though lateral geniculate neurons may be anatomically abnormal due to the deprivation rearing (Wiesel and Hubel, '65; Guillery, '73), they still show impressive degeneration following cortical ablations. A similar result obtains for deprived geniculate laminae of monocularly deprived cats following cortical ablations (Sherman, unpublished observations).

Within two to four weeks after the cortical ablations, visual field testing was begun. No postoperative change in the extent of or responsiveness within the visual fields was evident (figs. 12, 13). The only postoperative change detected in the cats was a slight tendency to circle towards the side of the cortical lesion, and *all* of the spontaneous orientations were in that direction.

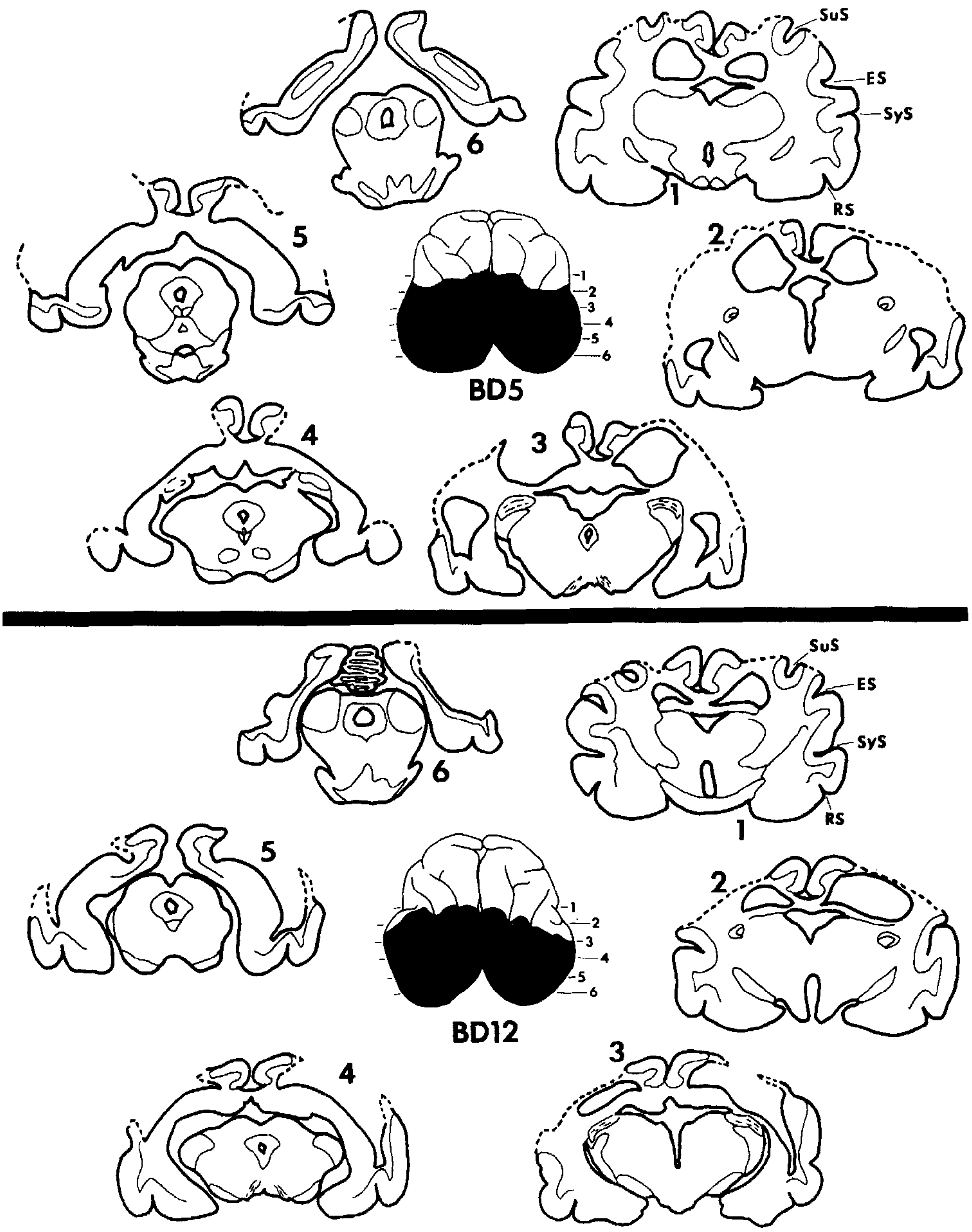

Fig. 4 Reconstruction of typical occipito-temporal cortical ablations in BD5 (upper) and BD12 (lower). Abbreviations: ES, ectosylvian sulcus; RS, rhinal sulcus; SuS, suprasylvian sulcus; SyS, sylvian sulcus.

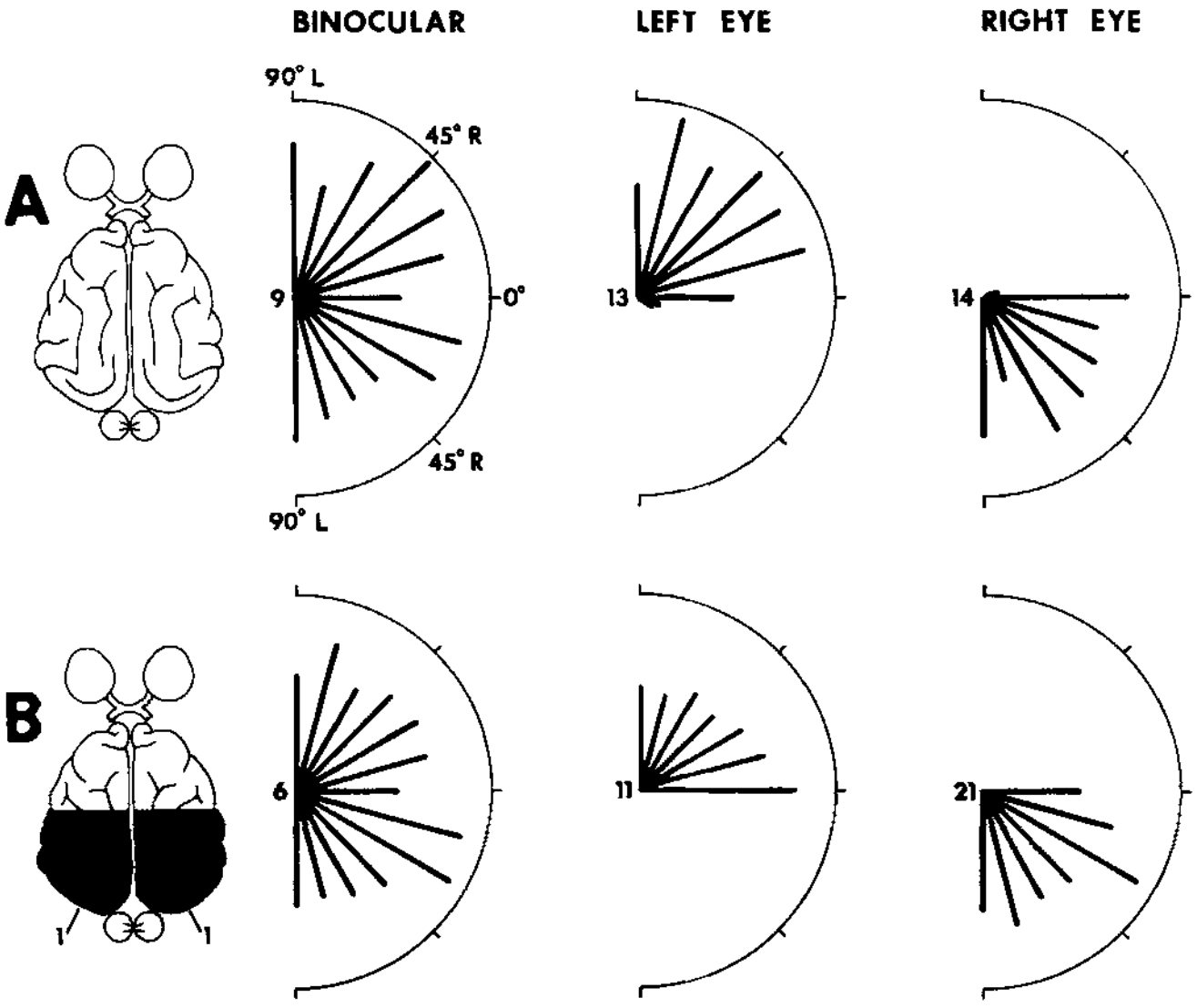

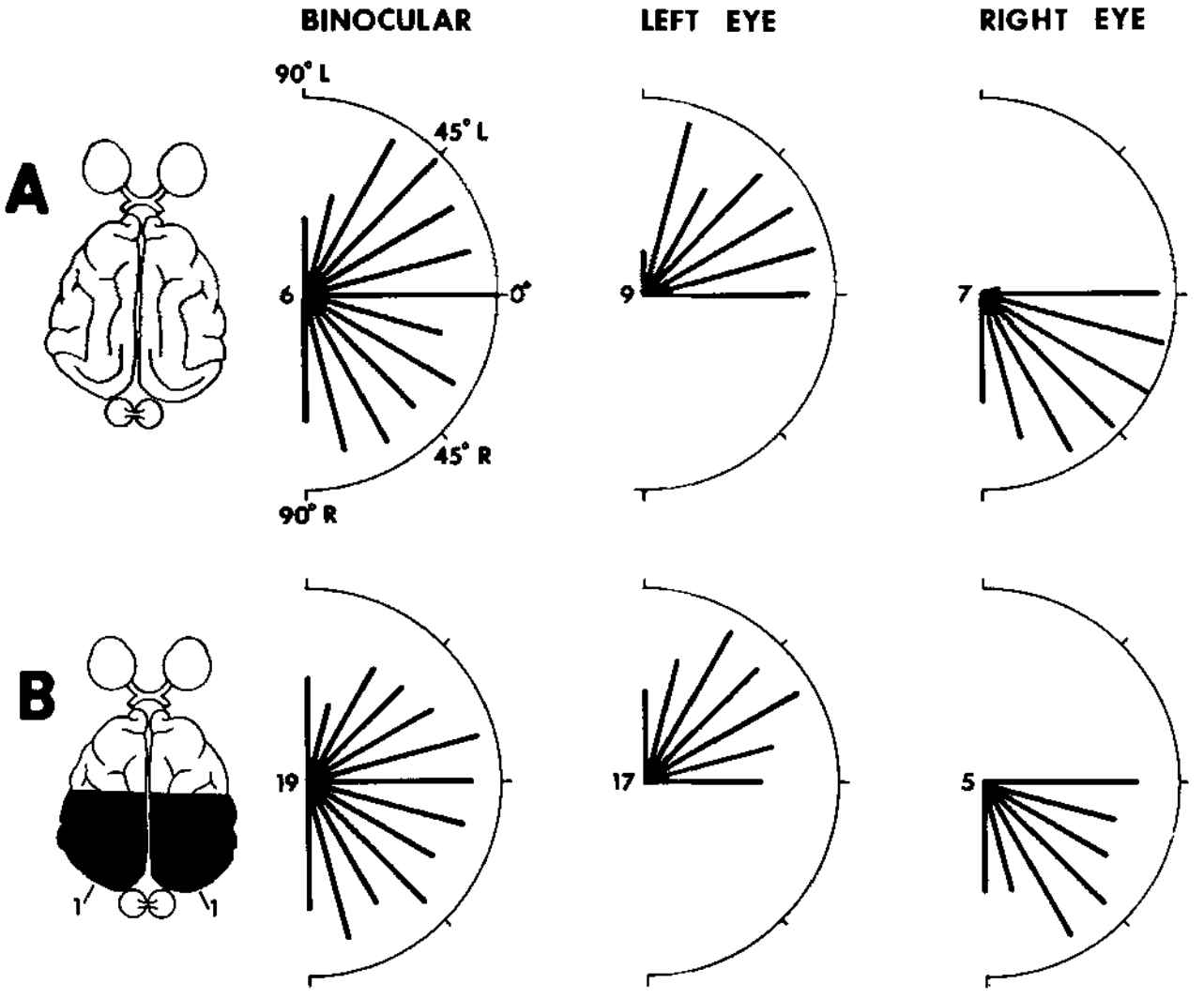

Fig. 6 Visual fields for BD11 pre- and postoperatively shown as in figure 5.

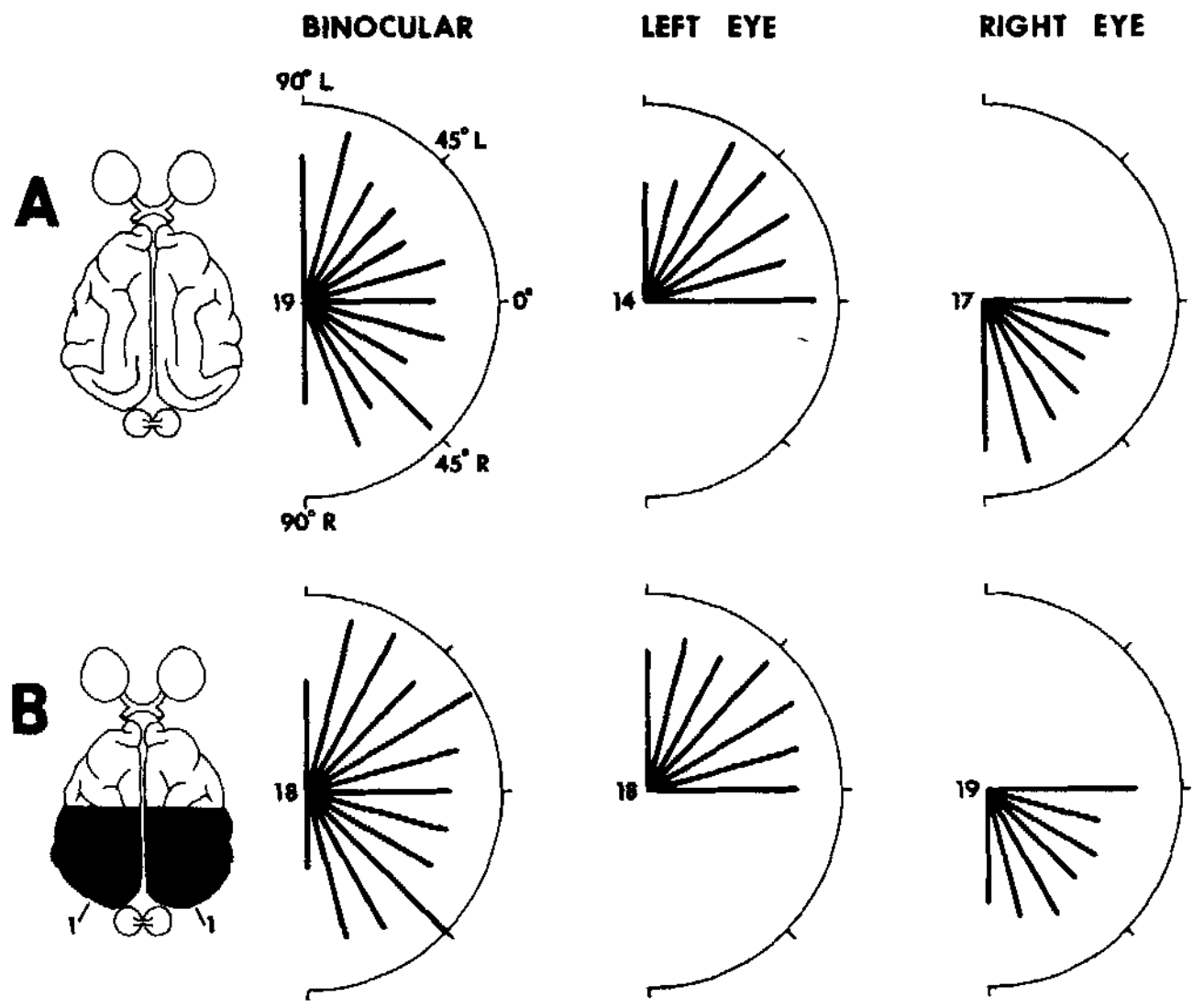

Fig. 7 Visual fields for BD12 pre- and postoperatively shown as in figure 5.

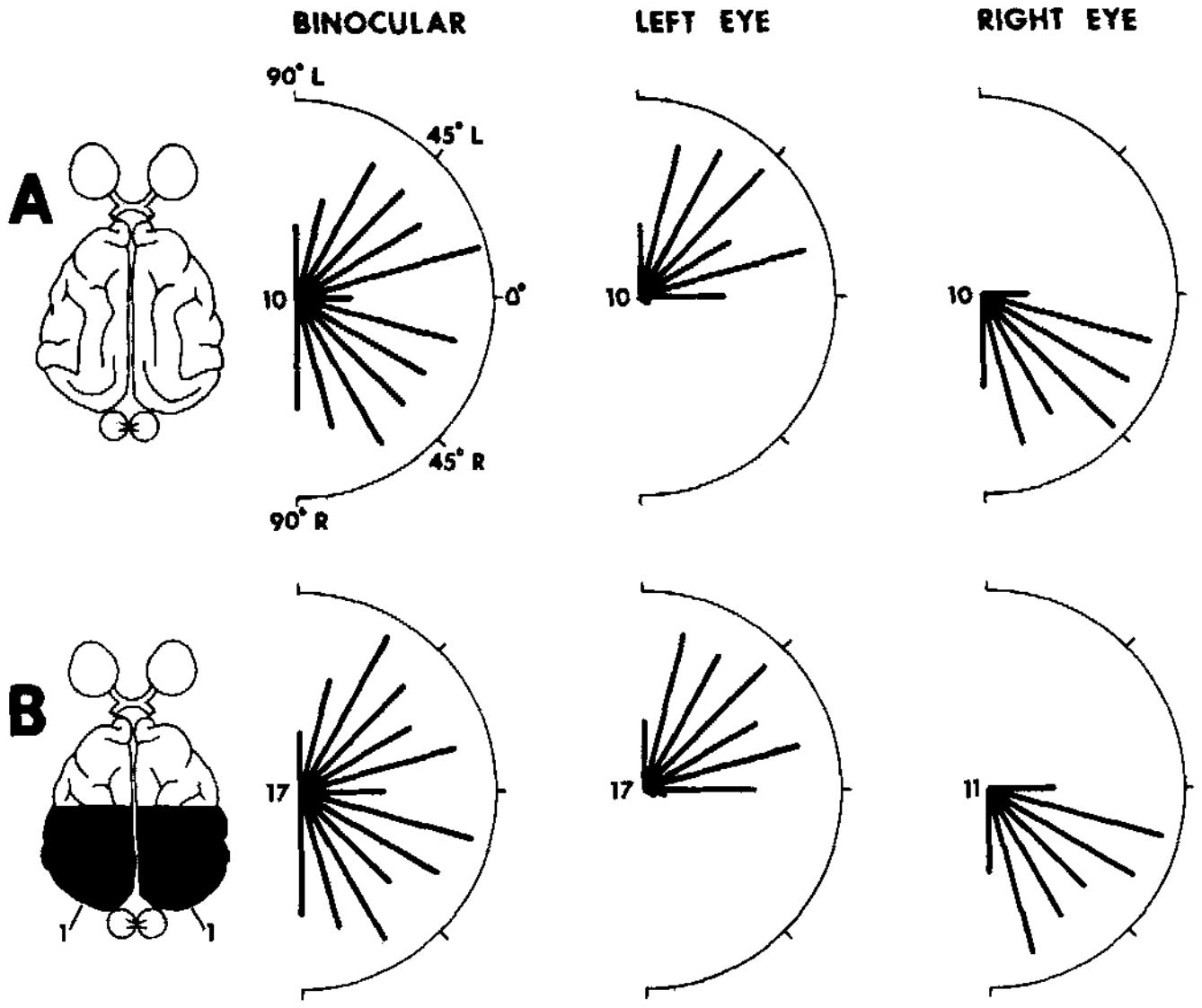

Fig. 8 Visual fields for BD18 pre- and postoperatively shown as in figure 5.

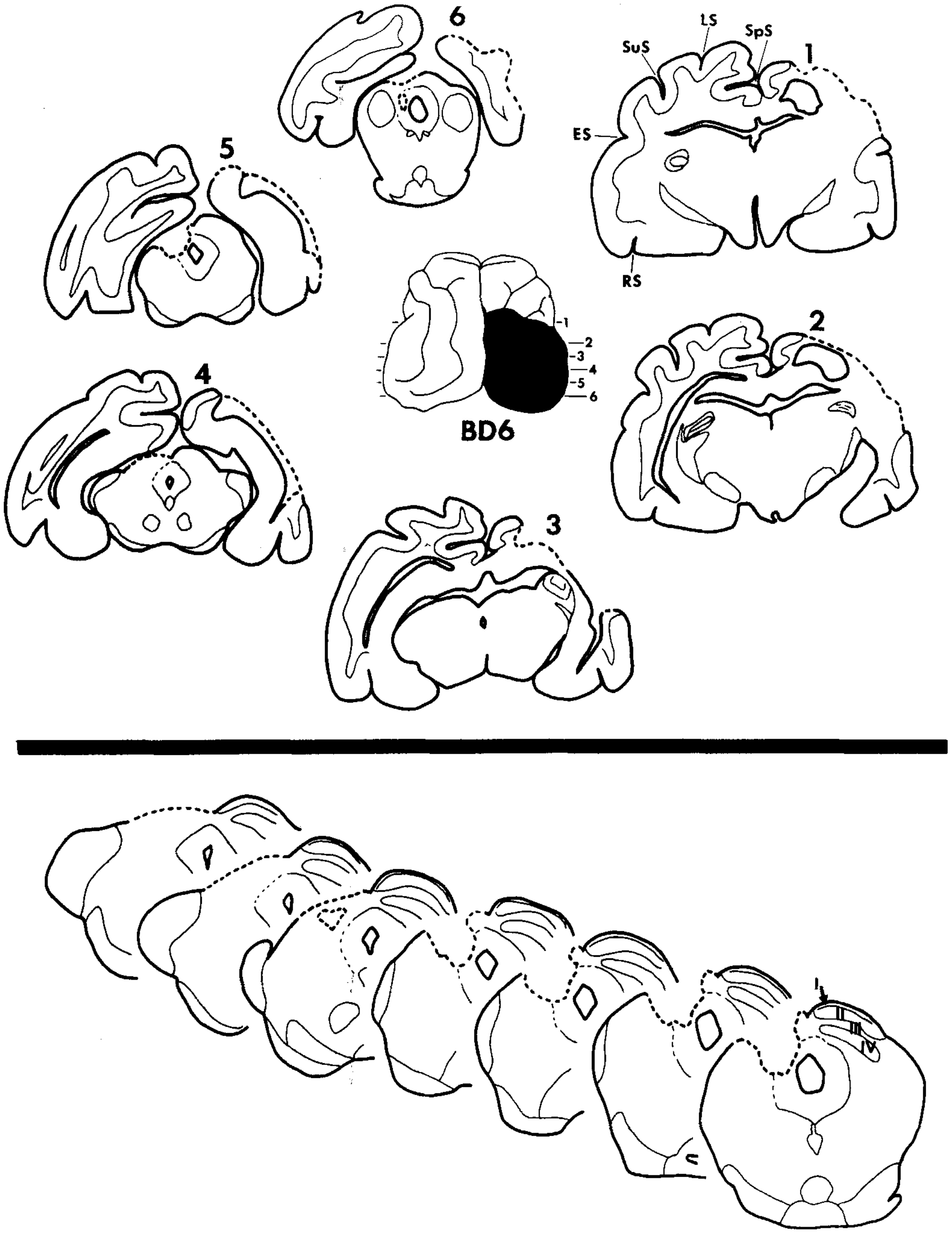

Fig. 9 Reconstruction of ablations in BD6. *Top*. Ablation of right occipito-temporal cortex in first operation. *Bottom*. Ablation of left superior colliculus in subsequent operation. The right dorsal lateral geniculate and pulvinar nuclei showed retrograde degeneration throughout. Abbreviations as in figure 4 plus: LS, lateral sulcus; SpS, suprasplenial sulcus.

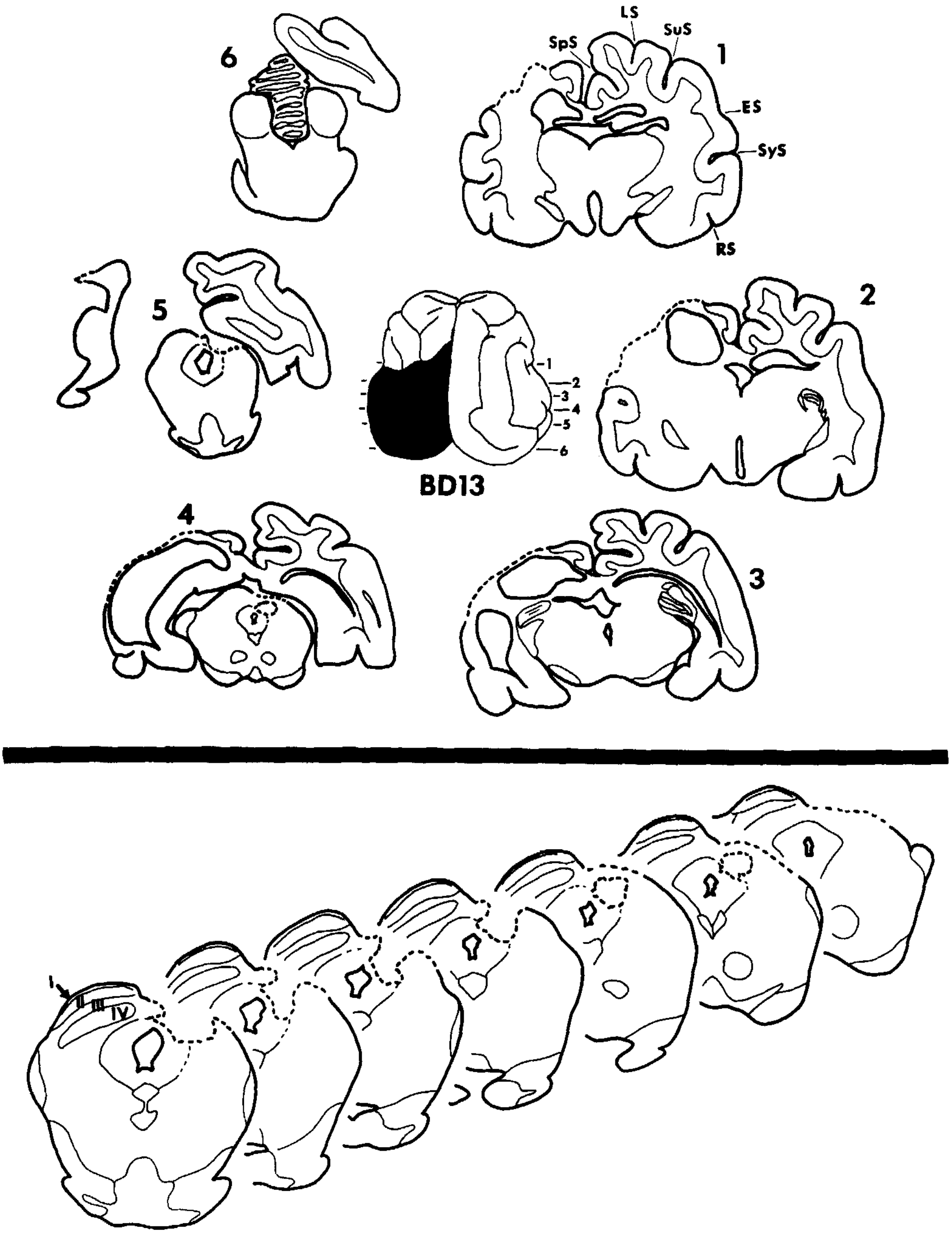

Fig. 10 Reconstruction of ablations in BD13. *Top.* Ablation of left occipito-temporal cortex in first operation. *Bottom.* Ablation of right superior colliculus in subsequent operation. The left dorsal lateral geniculate and pulvinar nuclei showed retrograde degeneration throughout. Abbreviations as in figures 5 and 9.

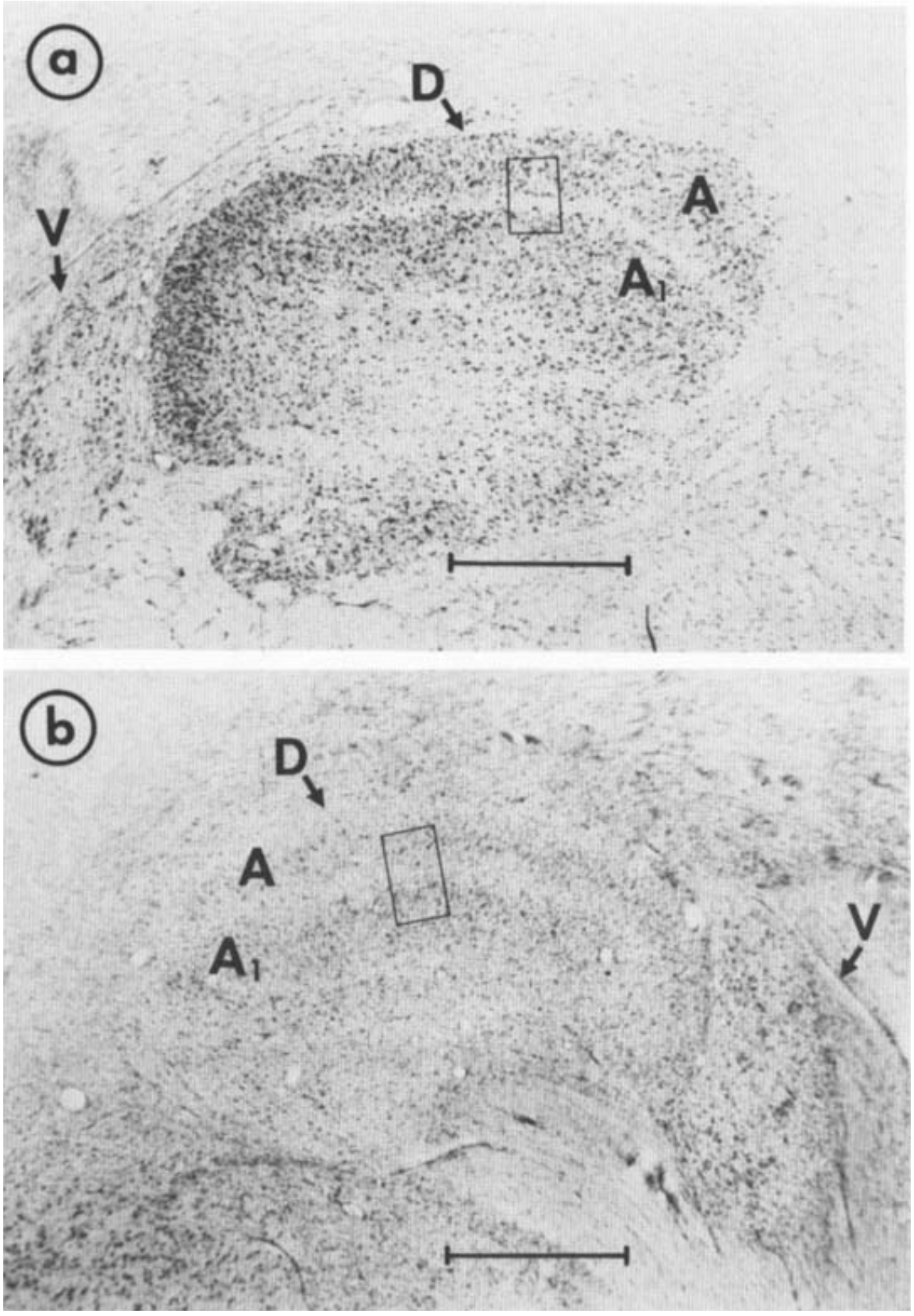

Fig. 11 Lateral geniculate nuclei of BD6 postoperatively; cresylecht violet stain. a. Low power view of left lateral geniculate nucleus (in nonlesioned hemisphere). The horizontal line represents 1 mm. The dorsal (D) and ventral (V) portions of the nucleus are indicated, as are laminae A (A) and A1 (A1). b. Low-power view of right lateral geniculate nucleus (in lesioned hemisphere). The scale and abbreviations are as in a. Note the severe degeneration of the dorsal, but not ventral, portion of the nucleus. c. Higher power view of neurons in the left lateral geniculate nucleus. The area is indicated by the rectangle in a, and the horizontal line equals 100 μm. d. Higher power view of neurons in the right lateral geniculate nucleus. The area is indicated by the rectangle in b, and the scale is the same as in c.

Yet clearly there obtained no significant defect in the field contralateral to the lesion, and this is consistent with the results shown in figures 5-8.

Following the collicular ablation, the cats showed a relatively strong tendency to circle to the side of this second lesion (i.e., a reverse of the previous tendency). After four to eight weeks this circling abated to mild levels and the cats were tested. Figures 12 and 13 show that after the second lesion both cats totally ignored all stimuli placed in the hemifield contralateral to the ablated colliculus. This pattern was seen equally with binocular viewing and with use only of the eye

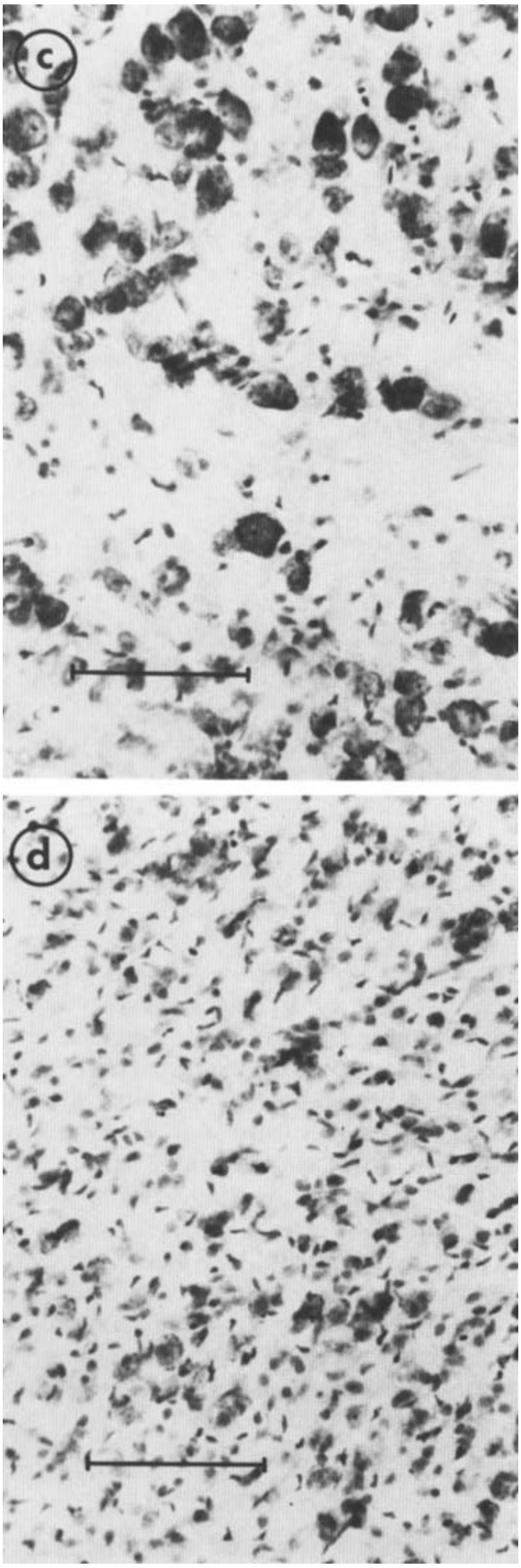

Figure 11

ipsilateral to the ablated colliculus. While using the other eye, both cats appeared to be totally blind on these tests. These patterns of visual field defects persisted throughout each cat's survival period (6 or 9 months after the collicular lesion). More than 90% of the spontaneous orientations now were directed towards the hemifield ipsilateral to the ablated colliculus. Figures 12 and 13 indicate that the binocularly deprived cats orient to stimuli contralateral to an intact colliculus, do not orient to stimuli contralateral to an ablated colliculus, and this orienting is unaffected by a cortical lesion. As long as the eye ipsilateral to the collicular lesion was kept open (whether or not the other eye was open), good responses were obtained and the animal could follow horizontally moving objects from the center to the periphery on the side of the good eye. If only the other eye were used, no responses were seen, and no tracking of moving objects could be evoked.

DISCUSSION

These results are consistent with the hypothesis that cats raised with binocular eyelid suture never develop dependence upon thalamocortical pathways for visually guided orienting behavior. Instead, they develop dependence upon retinotectal pathways for this behavior. Therefore, massive cortical ablations are without obvious effect on visual orienting, whereas collicular ablations abolish the behavior.

Comparison with normally reared cats

Unlike binocularly deprived cats, normally reared cats appear to use thalamocortical pathways for visual orienting behavior. Figure 14 summarizes this difference between cats in three ways. (1) Normally reared cats orient to stimulation of temporal retina, and binocularly deprived cats do not (fig. 14A). Responses to such stimulation seem to depend upon geniculocortical pathways (see the previous paper, Sherman, '77). (2) Lesions of visual cortex reduce or abolish the visual fields of normally reared cats but have no

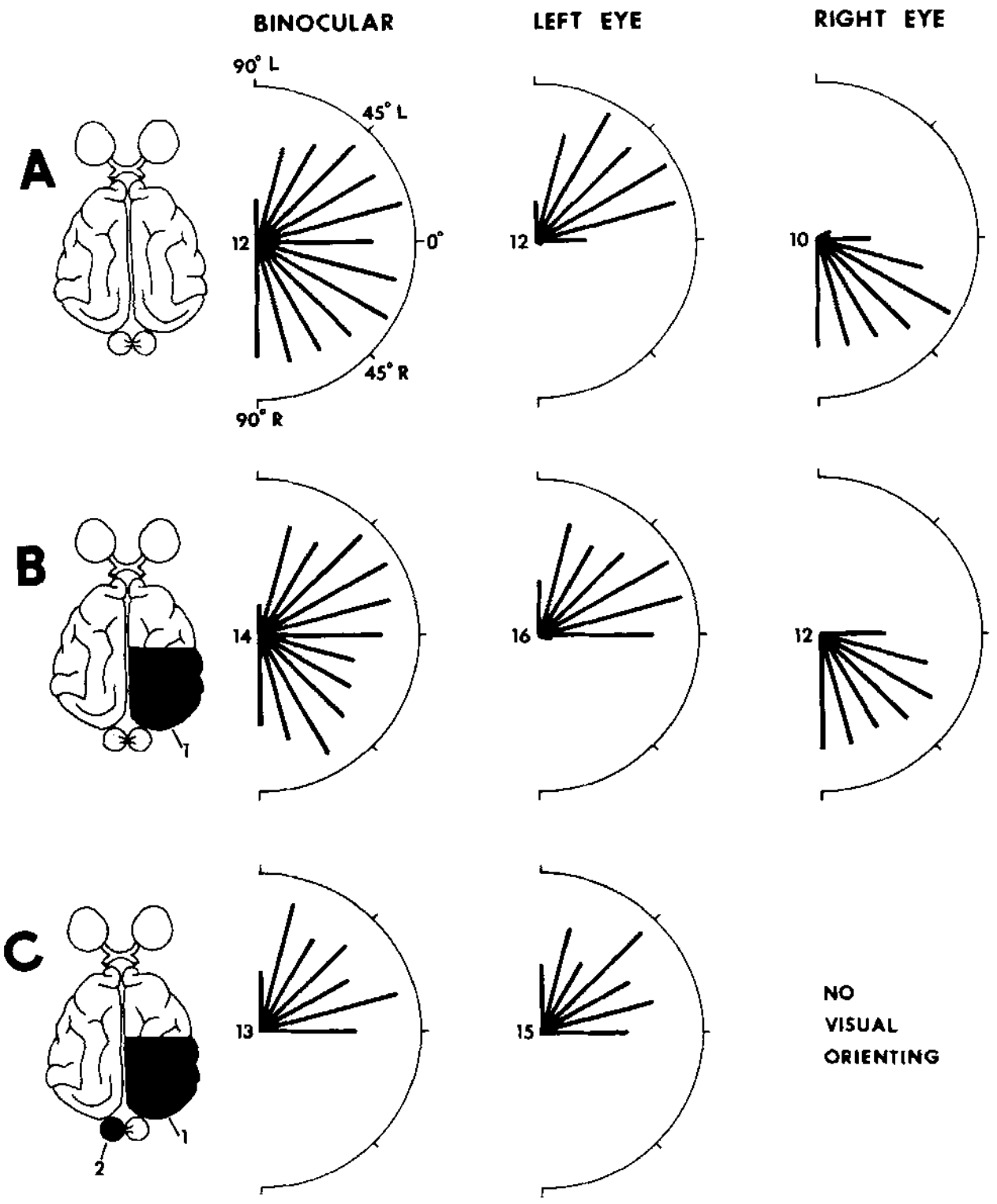

Fig. 12 Visual fields for cat BD6; conventions as in figure 2. A. Preoperative fields. B. Fields after right cortical ablation. C. Fields after subsequent ablation of left colliculus. A permanent right hemianopia ensued, and the right eye seemed blind on these visual orienting tests.

appreciable affect on the orienting behavior of the binocularly deprived cats (fig. 14B). (3) Collicular lesions do not abolish orienting behavior in normally reared cats but do in the binocularly deprived cats (fig. 14C).

Another obvious difference between normal and binocularly deprived cats concerns the development of intercollicular suppression. The evidence for this in normally reared cats derives from the observation emphasized in the preceding paper (Sherman, '77). That is, after visual decortication, functional disconnection of the superior colliculi (i.e., a unilateral collicular ablation or a collicular commissure transection) is necessary for clear visually guided orienting behavior. Such tectal surgery is not necessary for visual orienting in binocularly deprived cats with visual cortex ablations. Apparently, intercollicular suppression does not develop normally in these deprived cats. This possibly obtains because development of this suppression is linked to the appearance of certain cortical pathways which fail to develop normally during binocular suture (e.g., Hoffmann and Sherman, '75). One final implication of this is worth noting. If, as suggested in the previous paper (Sherman, '77), certain collicular neurons in normally reared cats are rendered unresponsive after decortication because of this intercollicular suppression, then these neurons in binocularly deprived cats should have unchanged responsiveness after decortication.

Comparison with monocularly deprived cats

Monocularly deprived cats, like normal cats, also seem to depend upon cortex for visual orienting, and this differs from the

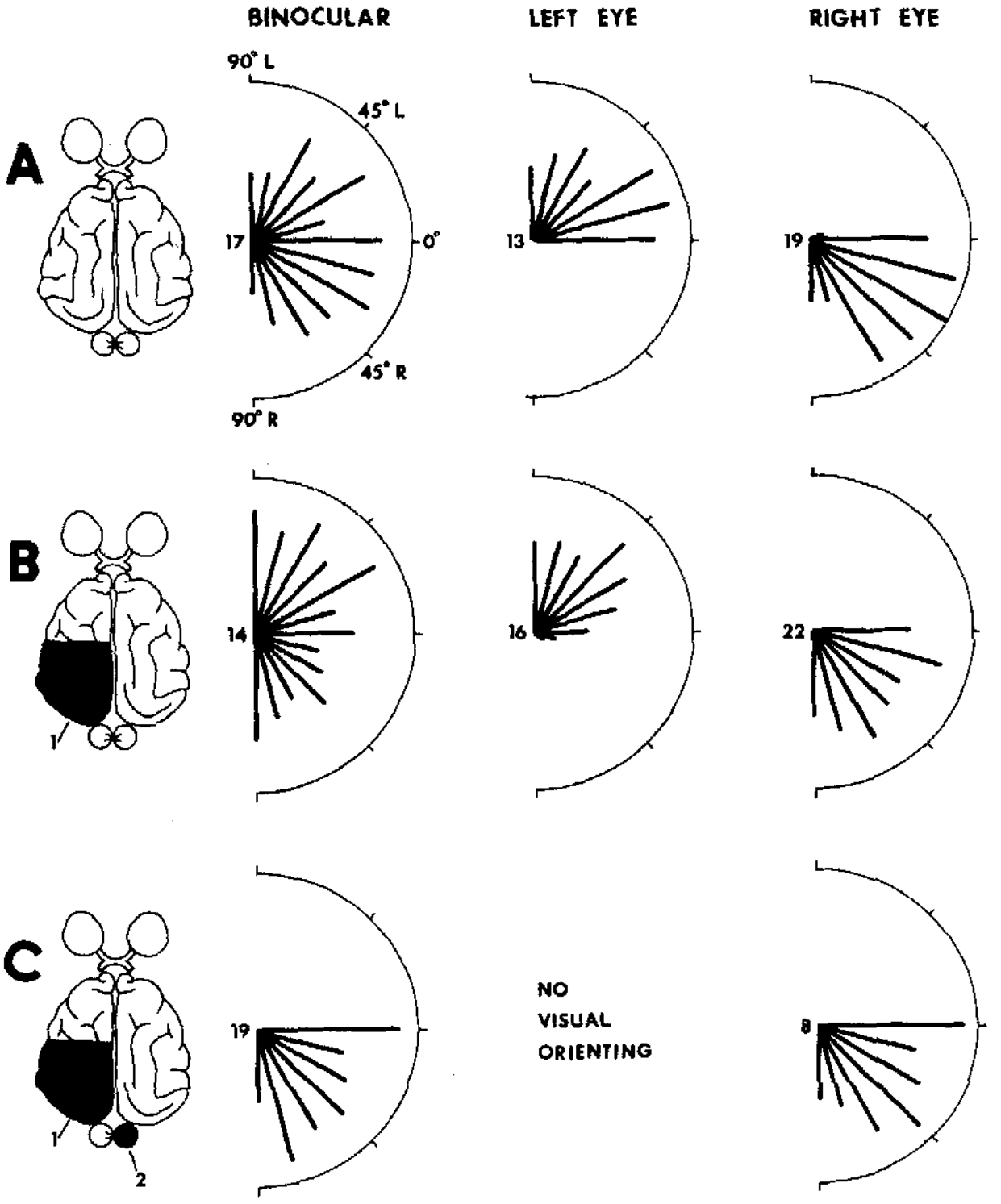

Fig. 13 Visual fields for cat BD13; conventions as in figure 2. A. Preoperative fields. B. Fields after left cortical ablation. C. Fields after subsequent ablation of right colliculus. A permanent left hemianopia ensued, and the left eye seemed blind on these visual orienting tests.

observations made of binocularly deprived cats. Monocularly deprived cats, when tested with the non-deprived eye, display a normal field of view; but with the deprived eye, they orient only to stimuli in the peripheral, monocular segment (Sherman, '73, '74a). This correlates with the pattern of deficits in the geniculocortical pathways (Guillery and Stelzner, '70; Sherman et al., '72; Sherman et al., '74). Furthermore, cortical ablations in monocularly (but not binocularly) deprived cats dramatically alter the visual fields (Sherman, '74c). Finally, if a small lesion is placed neonatally in nasal retina of the open eye, the monocularly deprived cat develops the ability to orient to stimulation of the corresponding region of *temporal* retina in the deprived eye (Sherman et al., '74), and this, too, suggests cortical participation.

The orienting behavior of monocularly deprived cats correlates with the pattern of its geniculocortical development in two ways. First, the deprived, monocular segments develop relatively normally, and this can best be explained by assuming that a form of competition between central pathways related to each eye at least partially controls development (Sherman et al., '74). Second, cortical participation in orienting behavior could also be related to the apparent domination of many collicular neurons by the corticotectal pathway in normal and monocularly deprived cats (Sterling and Wickelgren, '70; Hoffmann and Sherman, '74).

Likewise, the lack of cortical participation in visual orienting behavior for binocularly deprived cats can also be correlated with its geniculocortical deficits. First, the inability to record normal numbers of Y-cells in these cats occurs through-

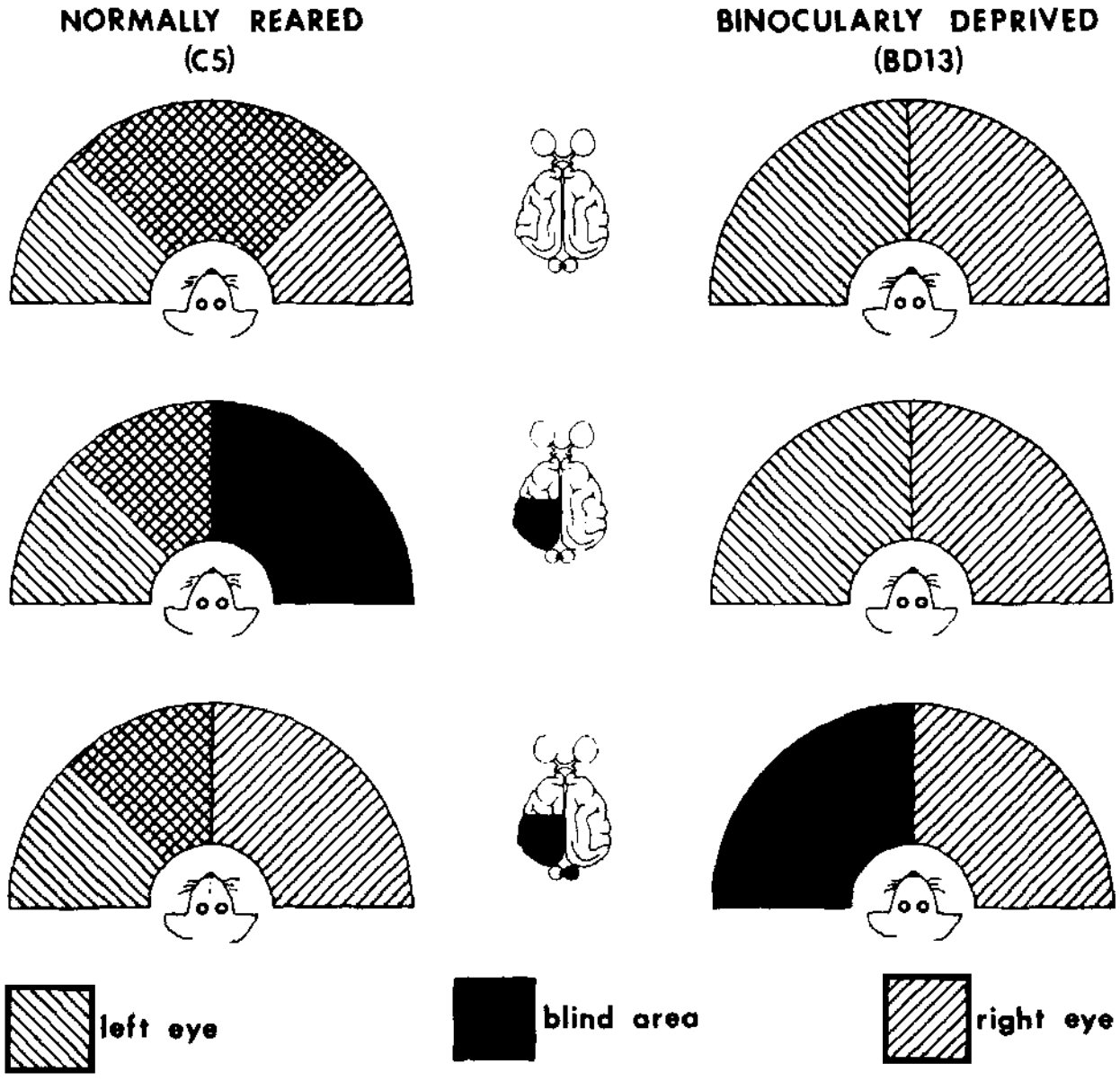

Fig. 14 Comparison of effects of lesions on visual orienting in normally reared and binocularly deprived cats. Data for the normally reared cat (C5) are from the preceding paper (Sherman, '77), whereas data for the deprived cat (BD13) are from the present paper. *Top*. Preoperatively with each eye, the normal cat sees from 90° ipsilateral to 45° contralateral, whereas the deprived cat sees only from 90° ipsilateral to 0°. *Middle*. After an extensive, left cortical ablation a normal cat fails to orient to stimuli placed to the right of the midline whereas the deprived cat's fields seem grossly unaffected. *Bottom*. After the subsequent right collicular ablation, vision in the normal cat returns in the right hemifield (Sprague, '66; previous paper, Sherman, '77), whereas the deprived cat suffers a permanent inability to orient to objects placed to the left of the midline. Note that after these ablations in the normal cat, the right eye has a full field of view but the left eye's field of view is limited to the ipsilateral 90° (see previous paper, Sherman, '77).

out the lateral geniculate nucleus, including the monocular segments (Sherman et al., '72). Second, collicular neurons in these cats appear to be dominated by retinotectal and not corticotectal input (Hoffmann and Sherman, '75), and this correlates with the hypothesized, general lack of geniculocortical development.

Therefore, the difference in the visual orienting of monocularly and binocularly deprived cats described here and elsewhere (Sherman, '73, '74a,c) represents another qualitative difference between such cats that indicates different developmental mechanisms (Sherman, '72; Sherman and Guillery, '76). For example, rearing with monocular suture clearly reveals the aforementioned "binocular competition" and considerable geniculocortical development related to visual orienting behavior, whereas binocular deprivation reveals neither. It may be that, instead of its geniculocortical pathways developing by means of mechanisms involving binocular competition, these pathways in binocularly sutured cats show a more global failure during development and remain relatively neonatal (Sherman, '72).

CONCLUSIONS

The main conclusion of this study is that binocularly deprived cats, unlike normal or monocularly deprived cats, do not develop geniculocortical participation in visual orienting. Instead, this behavior after early binocular suture appears to be dependent upon retinotectal pathways. It is emphasized that this experiment was solely directed at visual orienting behavior, and indeed other types of visual behavior may well be mediated by cortical pathways in these cats. For instance, we have found that the same binocularly deprived cats, whose orienting ability was unaffected by bilateral occipitotemporal cortex ablations, postoperatively lost their preoperative ability to learn or retain discriminations based on spatial patterns (Loop and Sherman, '77, submitted).

ACKNOWLEDGMENTS

The expert technical assistance of Lodi Smith and Sally Gibson is gratefully acknowledged. This research was supported by Grants BMS 73-06938 from the National Science Foundation and EY01565 from the Public Health Service as well as a Research Career Development Award (EY00020) from the Public Health Service.

LITERATURE CITED

Guillery, R. W. 1973 The effect of lid suture upon the growth of cells in the dorsal lateral geniculate nucleus of kittens. J. Comp. Neur., *148:* 417-422.

Guillery, R. W., and D. J. Stelzner 1970 The differential effects of unilateral lid closure upon the monocular and binocular segments of the dorsal lateral geniculate nucleus in the cat. J. Comp. Neur., *139:* 413-422.

Hoffmann, K.-P., and S. M. Sherman 1974 Effects of early monocular deprivation on visual input to cat superior colliculus. J. Neurophysiol., *37:* 1276-1286.

——— 1975 Effects of early binocular deprivation on visual input to cat superior colliculus. J. Neurophysiol., *38:* 1049-1059.

Loop, M. S., and S. M. Sherman (1977, submitted) Visual discriminations of cats with cortical and tectal lesions. J. Comp. Neur.

Sherman, S. M. 1972 Visual development in cats. Invest. Ophthal., *11:* 394-401.

——— 1973 Visual field defects in monocularly and binocularly deprived cats. Brain Res., *49:* 25-45.

——— 1974a Permanence of visual perimetry deficits in monocularly and binocularly deprived cats. Brain Res., *73:* 491-501.

——— 1974b Visual fields of cats with cortical and tectal lesions. Science, *185:* 355-357.

——— 1974c Monocularly deprived cats: improvement of the deprived eye's vision by visual decortication. Science, *186:* 267-269.

——— 1977 The effect of superior colliculus lesions upon the visual fields of cats with cortical ablations. J. Comp. Neur., *172:* 211-230.

Sherman, S. M., and R. W. Guillery 1976 Behavioral studies of binocular competition in cats. Vision Res., *16:* 1479-1481.

Sherman, S. M., R. W. Guillery, J. H. Kaas and K. J. Sanderson 1974 Behavioral, electrophysiological and morphological studies of binocular competition in the development of the geniculo-cortical pathways of cats. J. Comp. Neurol., *158:* 1-18.

Sherman, S. M., K.-P. Hoffmann and J. Stone 1972 Loss of a specific cell type from the dorsal lateral geniculate nucleus in visually deprived cats. J. Neurophysiol., *35:* 532-541.

Sterling, P., and B. G. Wickelgren 1970 Function of the projection from the visual cortex to the superior colliculus. Brain, Behav. and Evol., *3:* 210-218.

Wiesel, T. N., and D. H. Hubel 1963 Effects of visual deprivation on morphology and physiology of cells in the cat's lateral geniculate body. J. Neurophysiol., *26:* 978-993.

Wiesel, T. N., and D. H. Hubel 1965 Comparison of the effects of unilateral and bilateral eye closure on cortical unit responses in kittens. J. Neurophysiol., *28:* 1029-1040.