DEGENERATIVE SPINE CONDITIONS: Evaluation and Diagnosis

Authored by:
Bryan K Lawson, MD
San Antonio Military Medical Center



Goals and Objectives

- Brief introduction to spine nomenclature
- Focused anatomic review
- Important exam maneuvers
- Case based integration of knowledge
- **Primary focus on diagnosis with general introduction to treatment**

© 2020 OrthoACCESS

Review of Nomenclature

- ”Spondylo”
- Spondylosis
- Spondylolysis
- Spondylodiscitis
- Spondylolisthesis
- Spondyloarthropathy

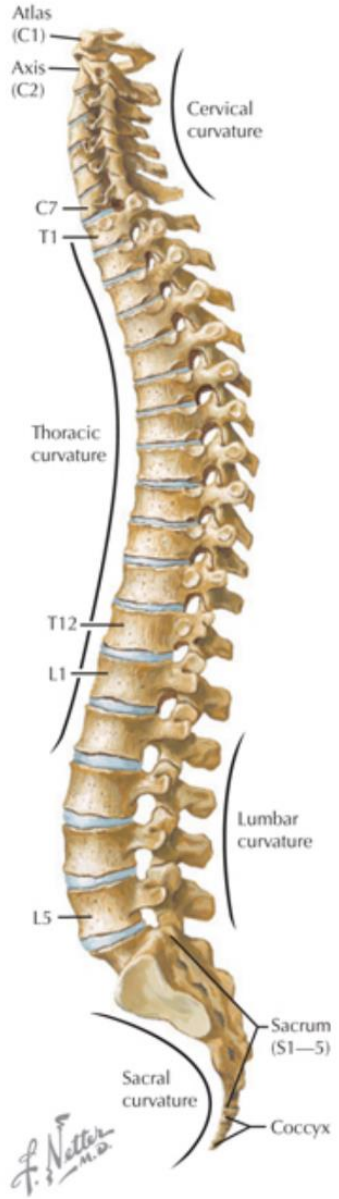

© 2020 OrthoACCESS

*Netter’s Concise Orthopaedic Anatomy Second Edition, 2010 Saunders/Elsevier

Cervical Spine Anatomy

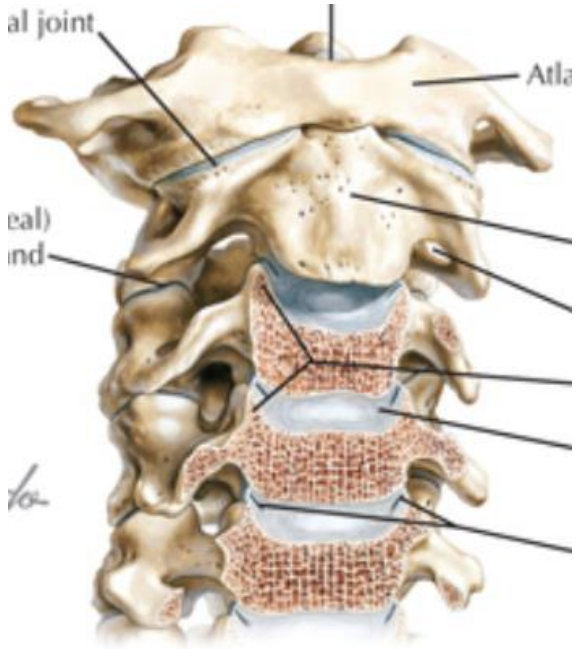

- Occipital – C2
- Subaxial Cervical Spine
- Vertebral Artery
- Nerve Root Numbering

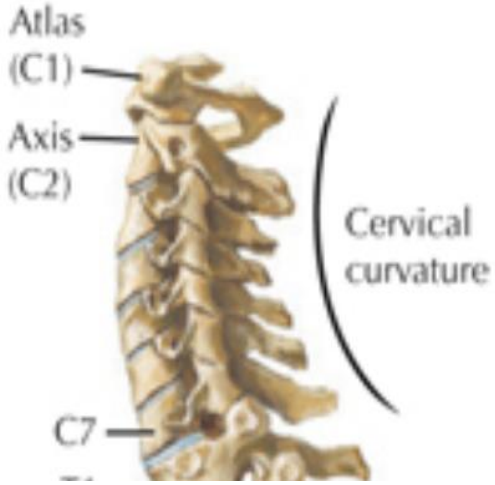

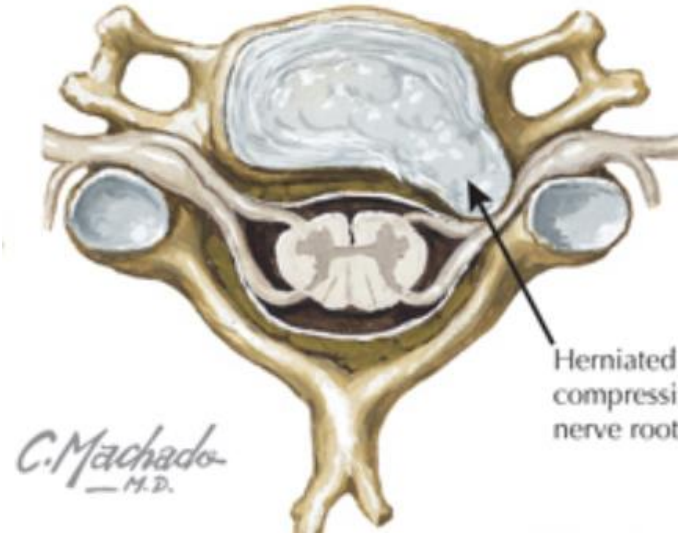

© 2020 OrthoACCESS

*Netter's Concise Orthopaedic Anatomy Second Edition, 2010 Saunders/Elsevier

Cervical Spine Anatomy

- **Occipital – C2**
- Subaxial Cervical Spine
- Vertebral Artery
- Nerve Root Numbering

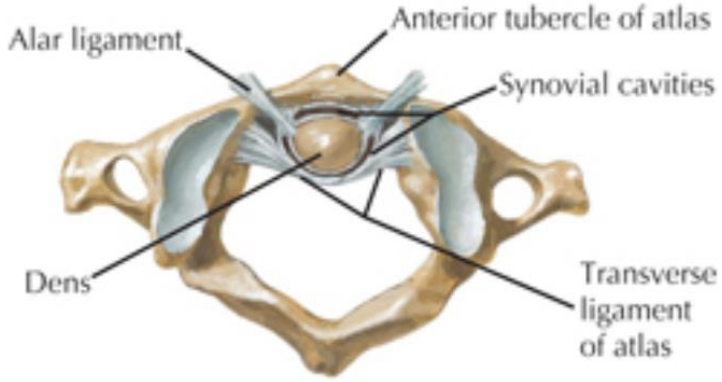

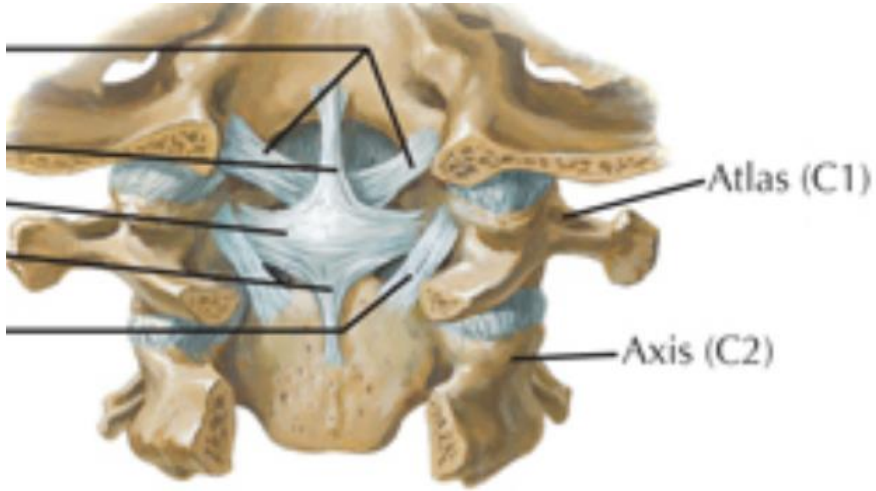

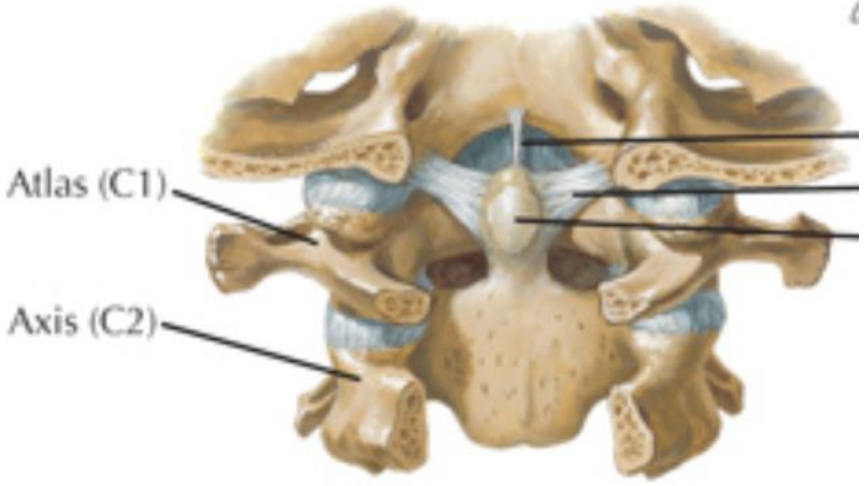

© 2020 OrthoACCESS

*Netter's Concise Orthopaedic Anatomy Second Edition, 2010 Saunders/Elsevier

Cervical Spine Anatomy

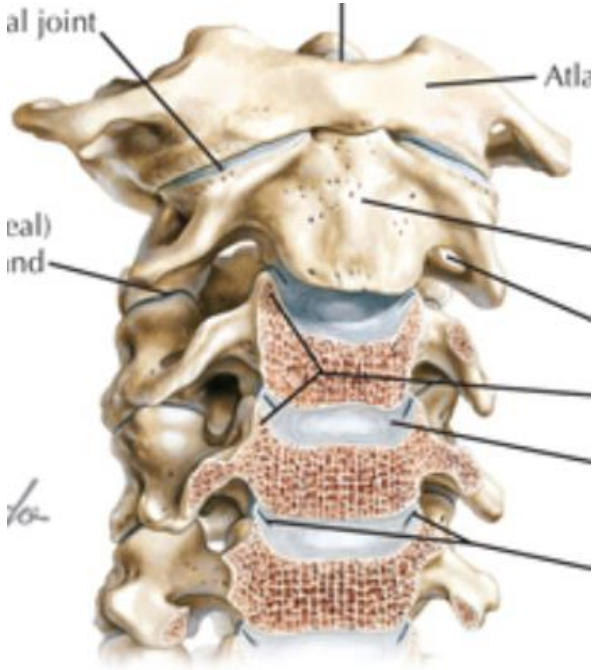

- Occipital – C2
- **Subaxial Cervical Spine**
- Vertebral Artery
- Nerve Root Numbering

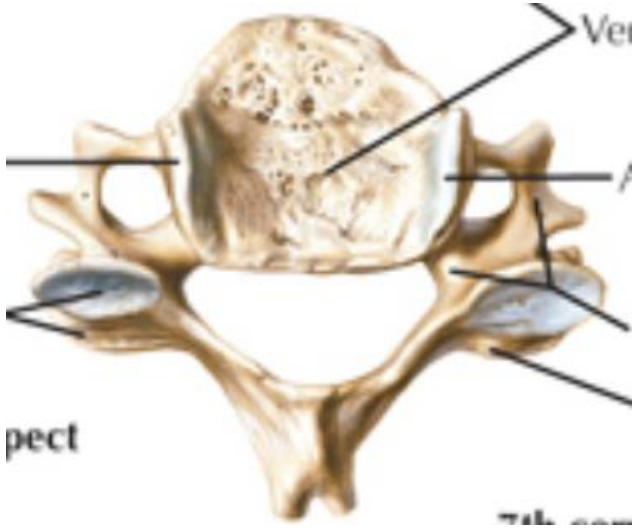

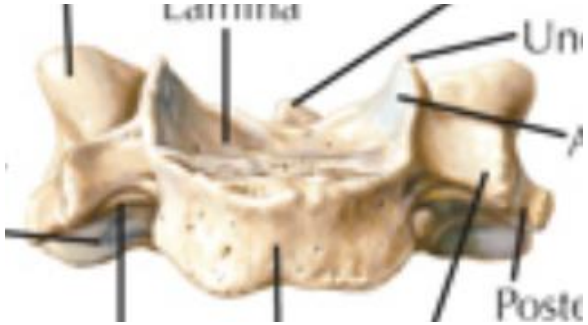

© 2020 OrthoACCESS

*Netter's Concise Orthopaedic Anatomy Second Edition, 2010 Saunders/Elsevier

Cervical Spine Anatomy

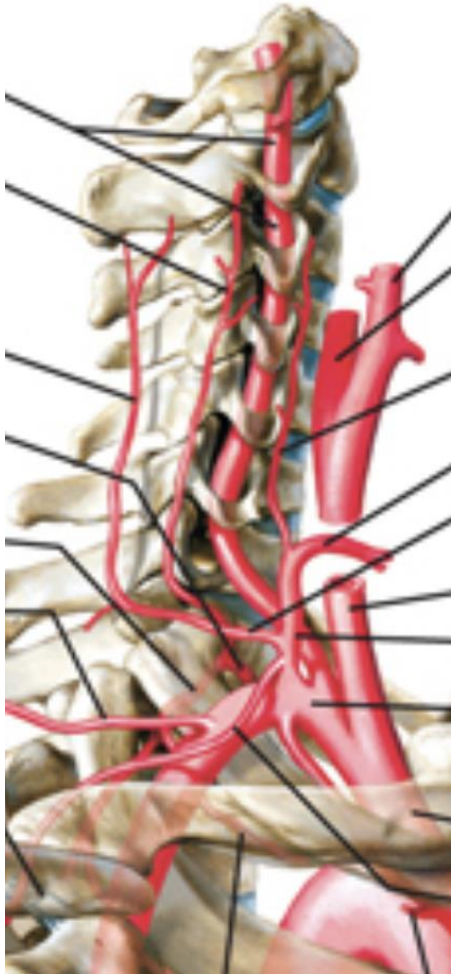

- Occipital – C2
- Subaxial Cervical Spine
- **Vertebral Artery**
- Nerve Root Numbering

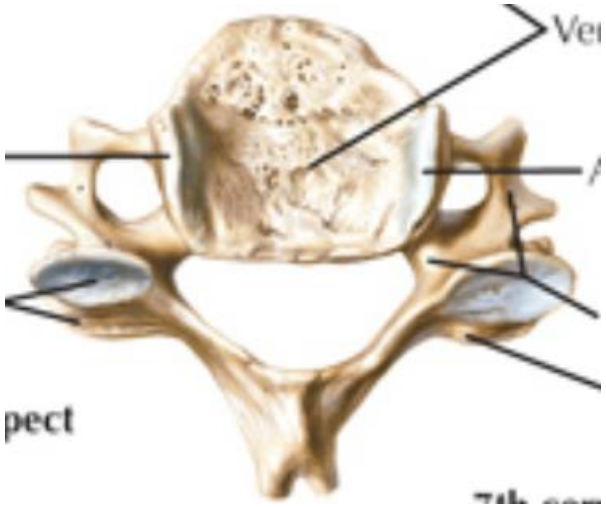

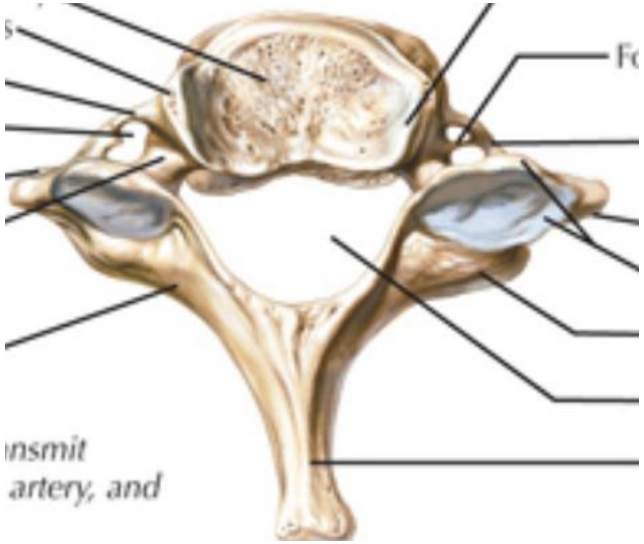

OrthoACCESS
© 2020 OrthoACCESS

*Netter's Concise Orthopaedic Anatomy Second Edition, 2010 Saunders/Elsevier

Cervical Spine Anatomy

- Occipital – C2
- Subaxial Cervical Spine
- Vertebral Artery
- **Nerve Root Numbering**

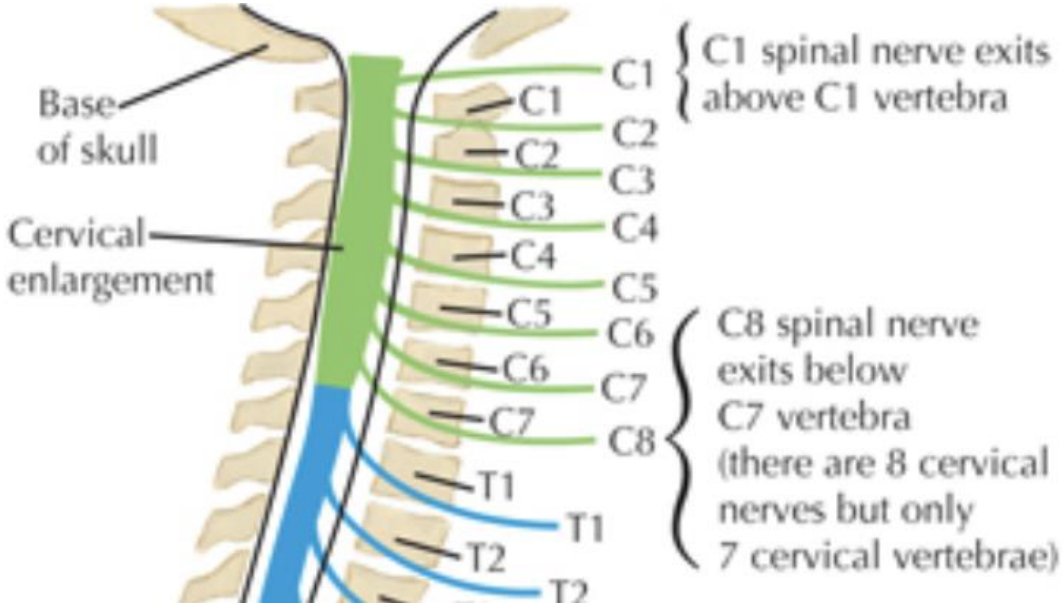

*Netter's Concise Orthopaedic Anatomy Second Edition, 2010 Saunders/Elsevier

© 2020 OrthoACCESS

Cervical Spine Patient History

- Rule out RED FLAGS
- Determine hierarchy of symptoms
  - Weakness
  - Numbness
  - Neck Pain
  - % Neck Pain vs % Extremity Pain

© 2020 OrthoACCESS

Cervical Spine Examination

- Strength Exam (C5-T1)
- Sensory Exam (C5-T1)
- Reflexes
- Gait
- Special Tests
  - Romberg
  - Spurling's
  - Hoffman
  - Inverted Brachial Radialis

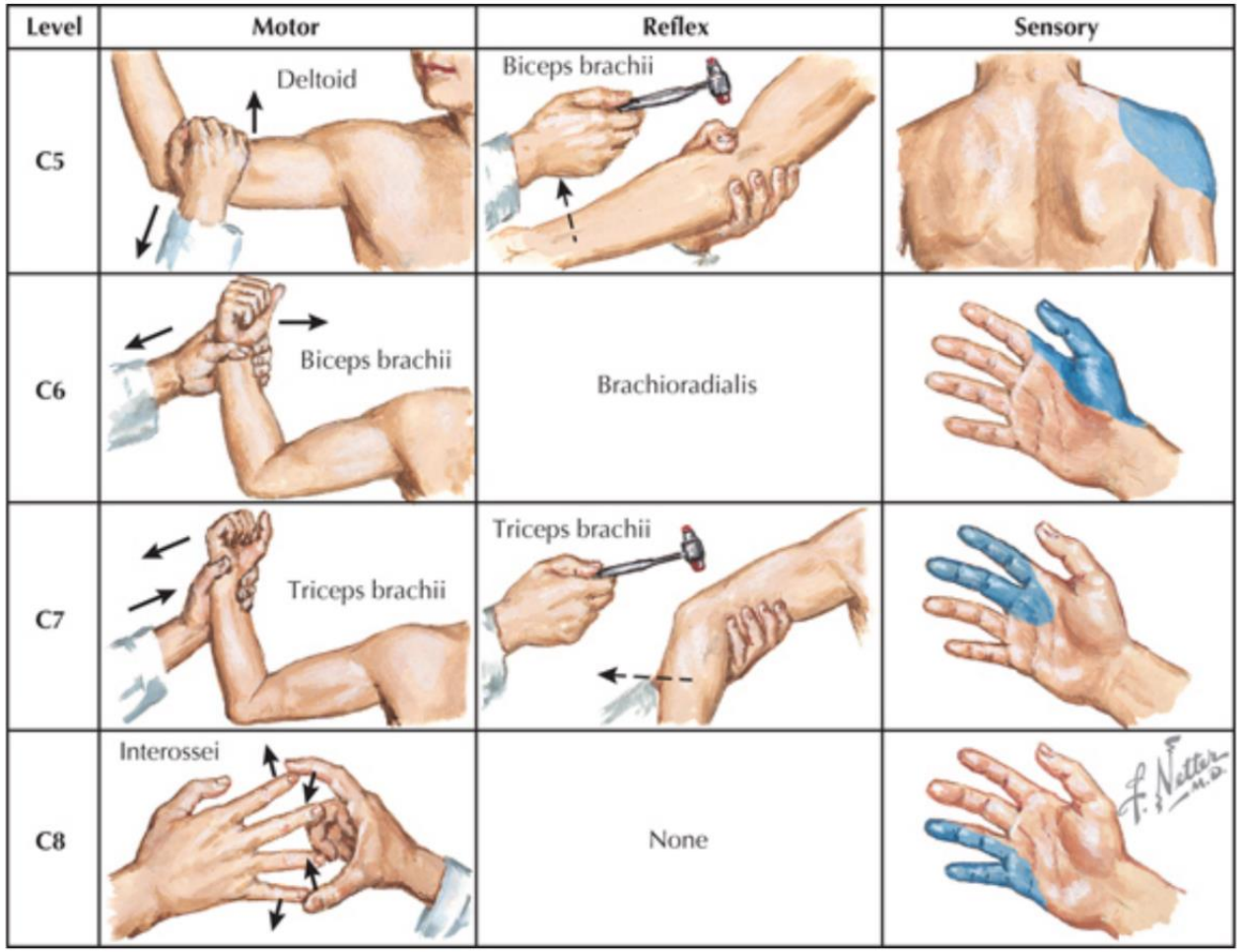

*Netter's Concise Orthopaedic Anatomy Second Edition, 2010 Saunders/Elsevier

© 2020 OrthoACCESS

Cervical Spine Case #1

- 42M presents with RIGHT thumb/radial forearm numbness and wrist extension weakness

© 2020 OrthoACCESS

Cervical Spine Case #1

- **42M presents with RIGHT thumb/radial forearm numbness and wrist extension weakness**
- No Gait Changes, No Bowel/Bladder Changes, No Dexterity changes
- STRENGTH: 3/5 RIGHT Biceps & Wrist Extension
- SENSATION: Impaired over the RIGHT Radial Forearm & Thumb
- REFLEXES: Symmetric Globally
- SPECIAL TESTS: Positive Spurling's (RIGHTWARD ROTATION)

© 2020 OrthoACCESS

Cervical Spine Case #1





© 2020 OrthoACCESS

Cervical Spine Case #1 (Disc Herniation)

RIGHT Parasagittal



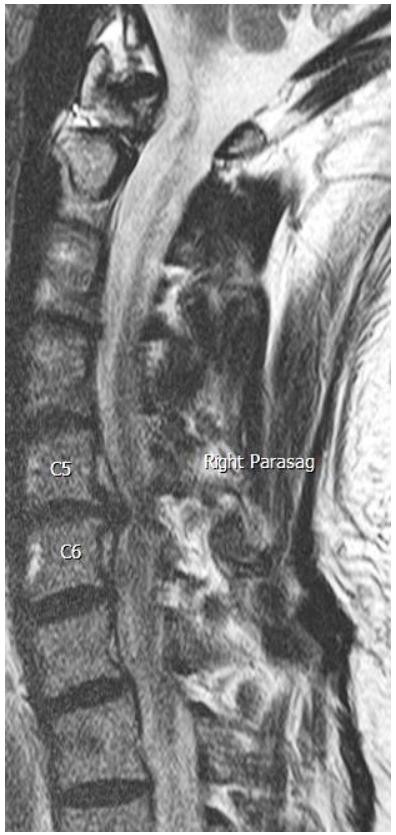

© 2020 OrthoACCESS

Cervical Spine Case #1 (Disc Herniation)

RIGHT Parasagittal



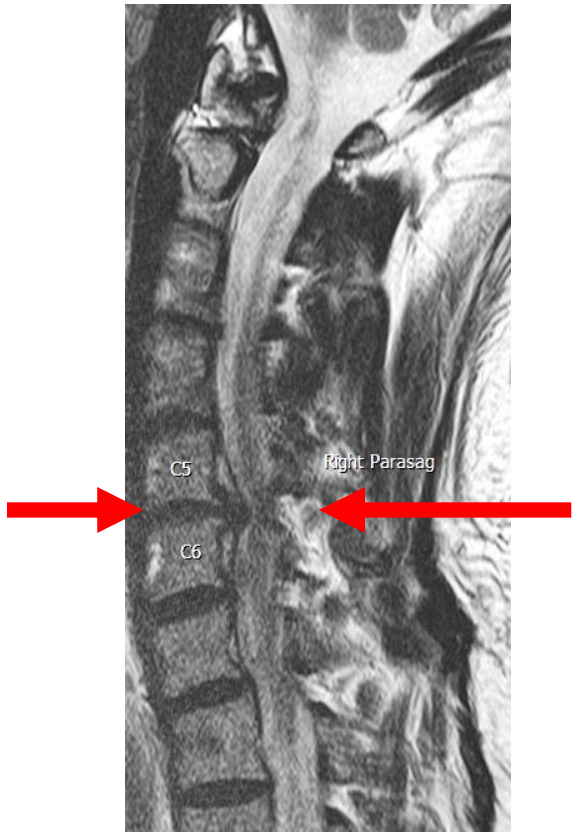

© 2020 OrthoACCESS

Cervical Spine Case #1 (Disc Herniation)



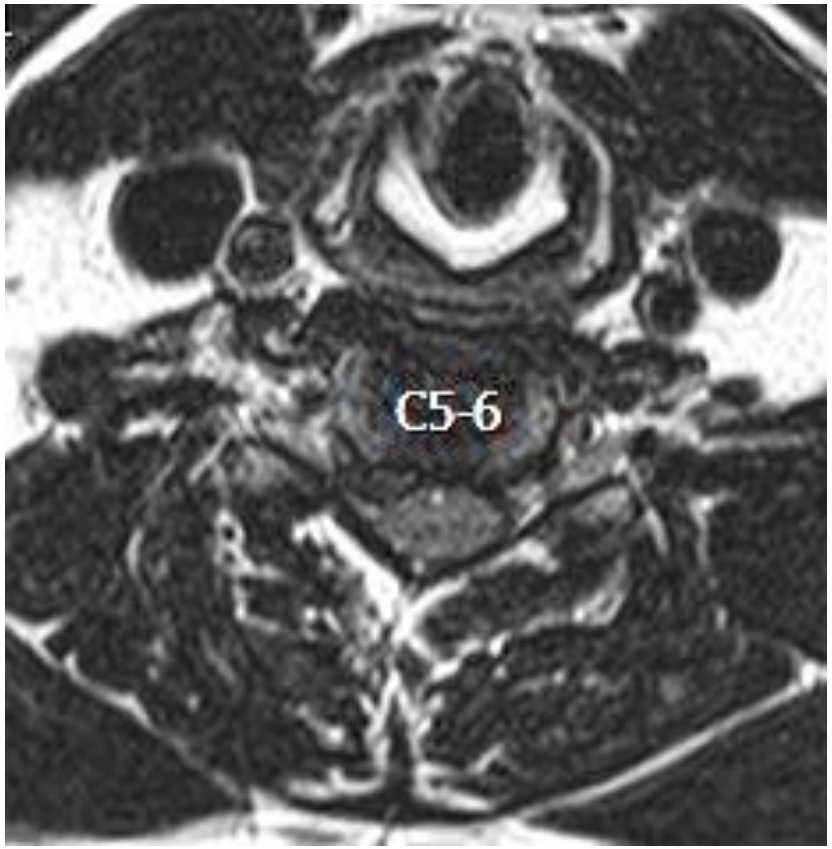

© 2020 OrthoACCESS

Cervical Spine Case #1 (Disc Herniation)



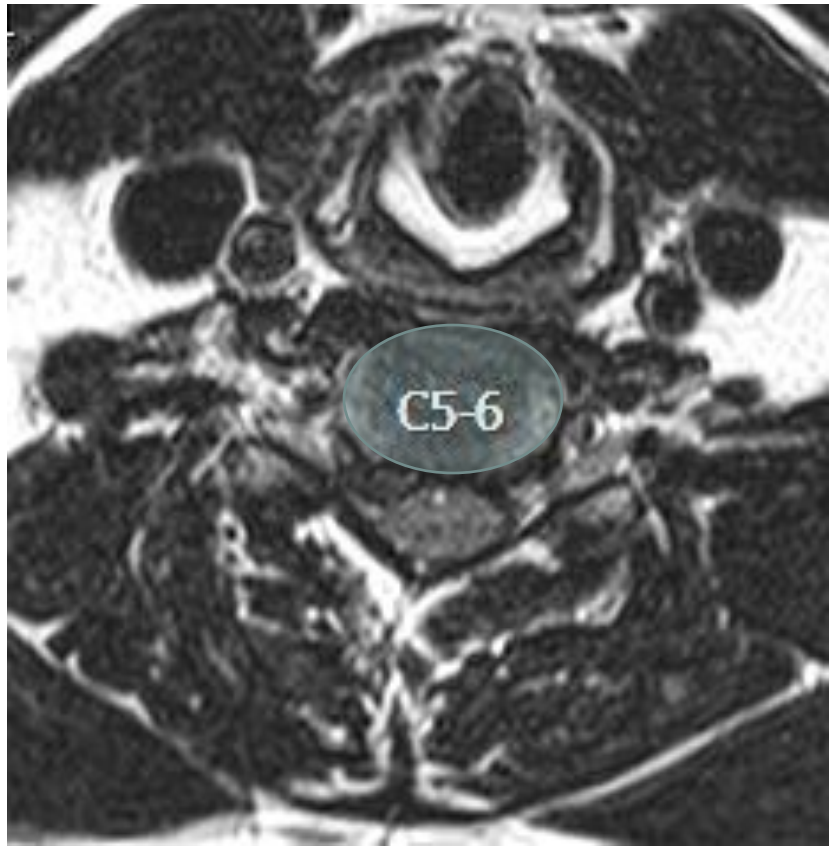

© 2020 OrthoACCESS

Cervical Spine Case #1 (Disc Herniation)



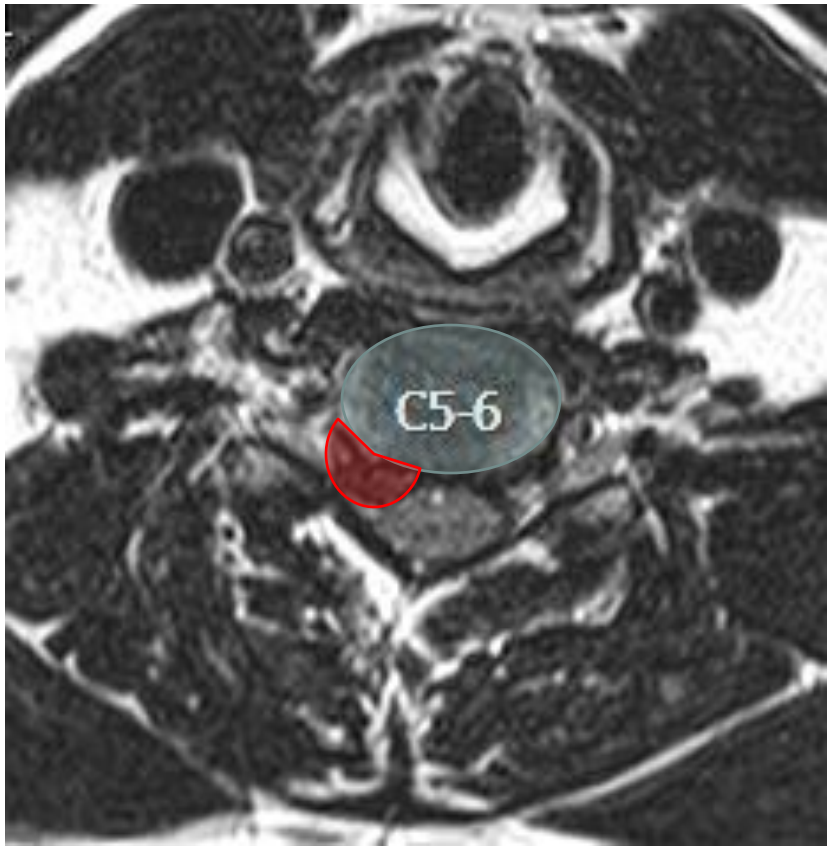

© 2020 OrthoACCESS

Cervical Spine Case #1 (Disc Herniation)

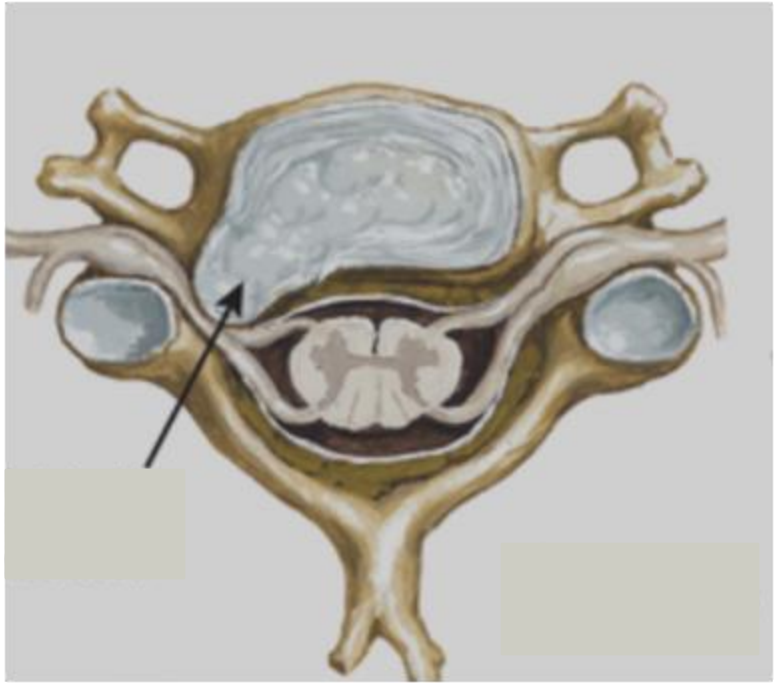

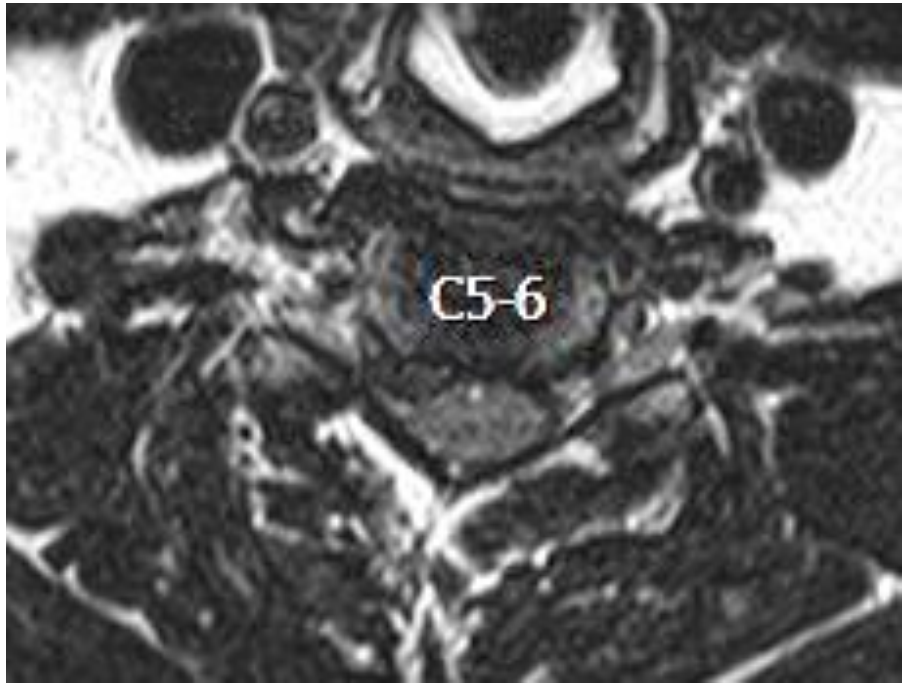

© 2020 OrthoACCESS

Cervical Spine Case #1 (Disc Herniation)

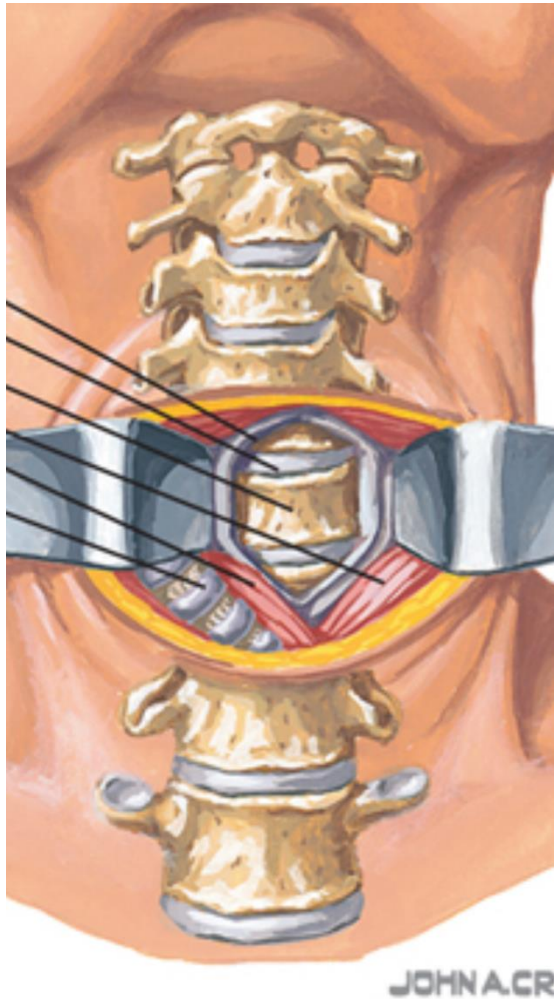

*Netter's Concise Orthopaedic Anatomy Second Edition, 2010 Saunders/Elsevier

© 2020 OrthoACCESS

Cervical Spine Case #1 (Disc Herniation)

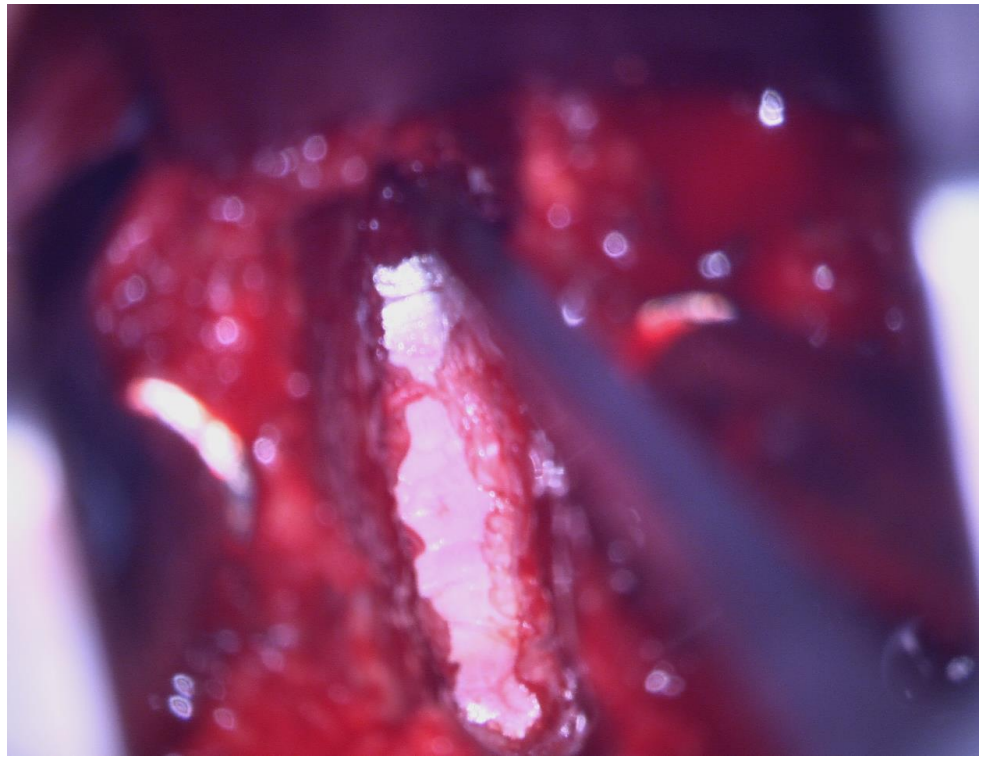

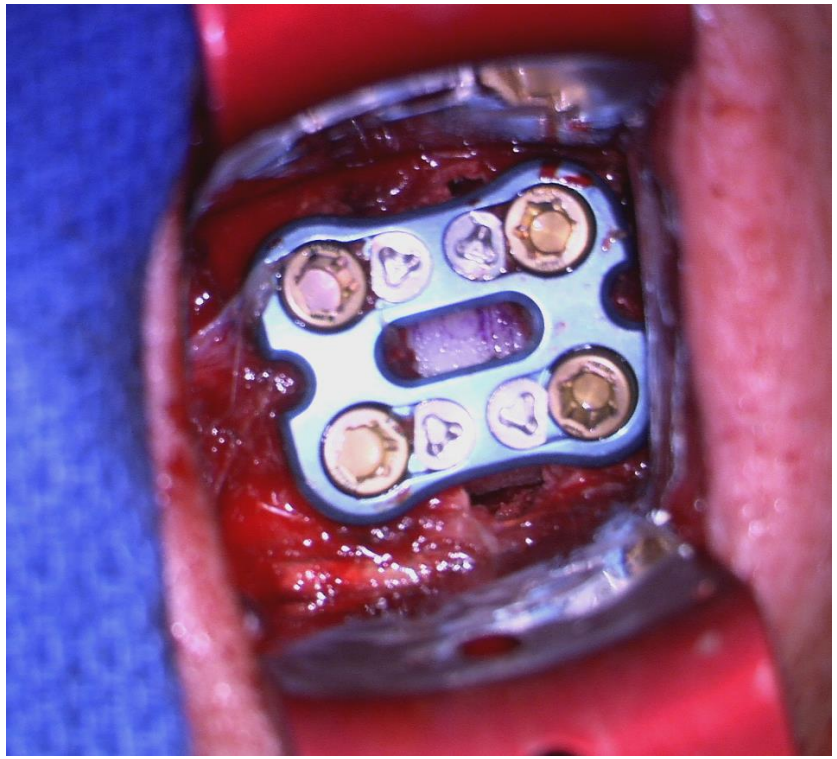

© 2020 OrthoACCESS

Cervical Spine Case #1 (Disc Herniation)





© 2020 OrthoACCESS

Cervical Spine Case #2

- 74F presents with progressive gait imbalance and decreased dexterity

© 2020 OrthoACCESS

Cervical Spine Case #2

- **74F presents with progressive gait imbalance and decreased dexterity**
- Can no longer ambulate without walker, unable to button blouse, progressive urinary retention.
- STRENGTH: Global upper and lower extremity weakness
- SENSATION: Generally symmetric and non-focal
- REFLEXES: Global Hyper-Reflexia
- SPECIAL TESTS: Positive Hoffman, Positive Romberg

© 2020 OrthoACCESS

Cervical Spine Case #2



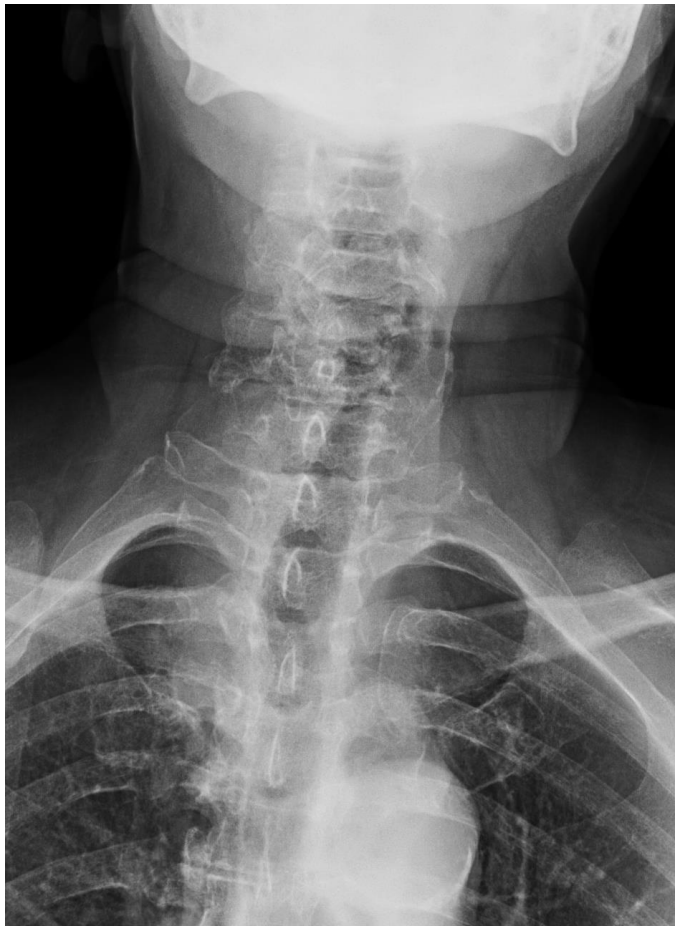

© 2020 OrthoACCESS

Cervical Spine Case #2 (Cervical Stenosis/Myelopathy)



OrthoACCESS
© 2020 OrthoACCESS

Cervical Spine Case #2 (Cervical Stenosis/Myelopathy)



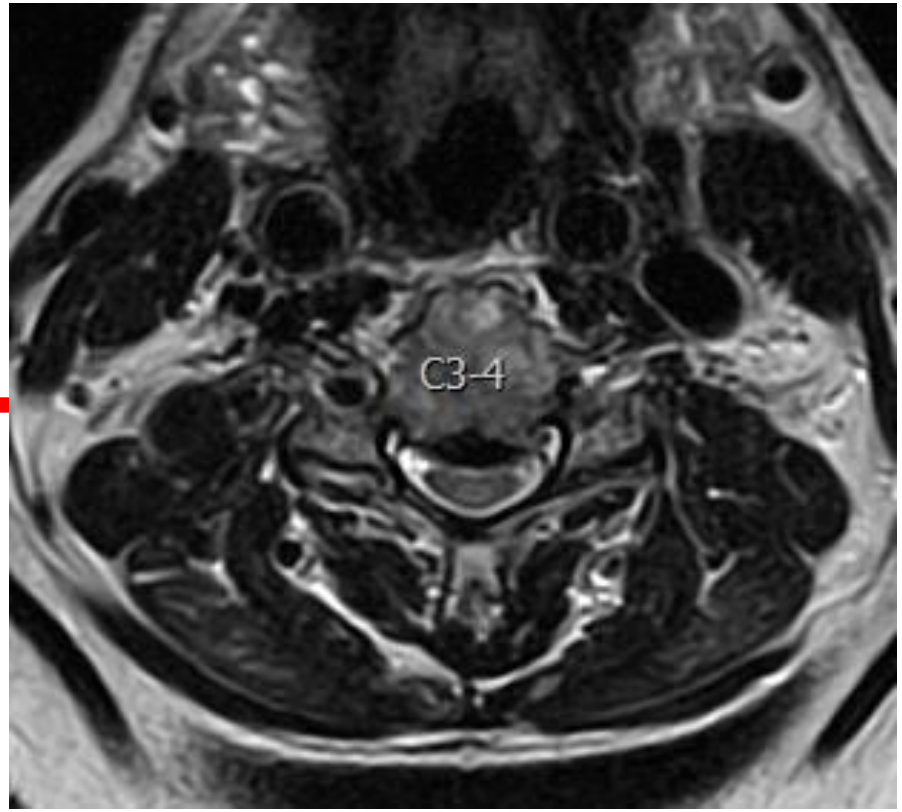

OrthoACCESS
© 2020 OrthoACCESS

Cervical Spine Case #2 (Cervical Stenosis/Myelopathy)



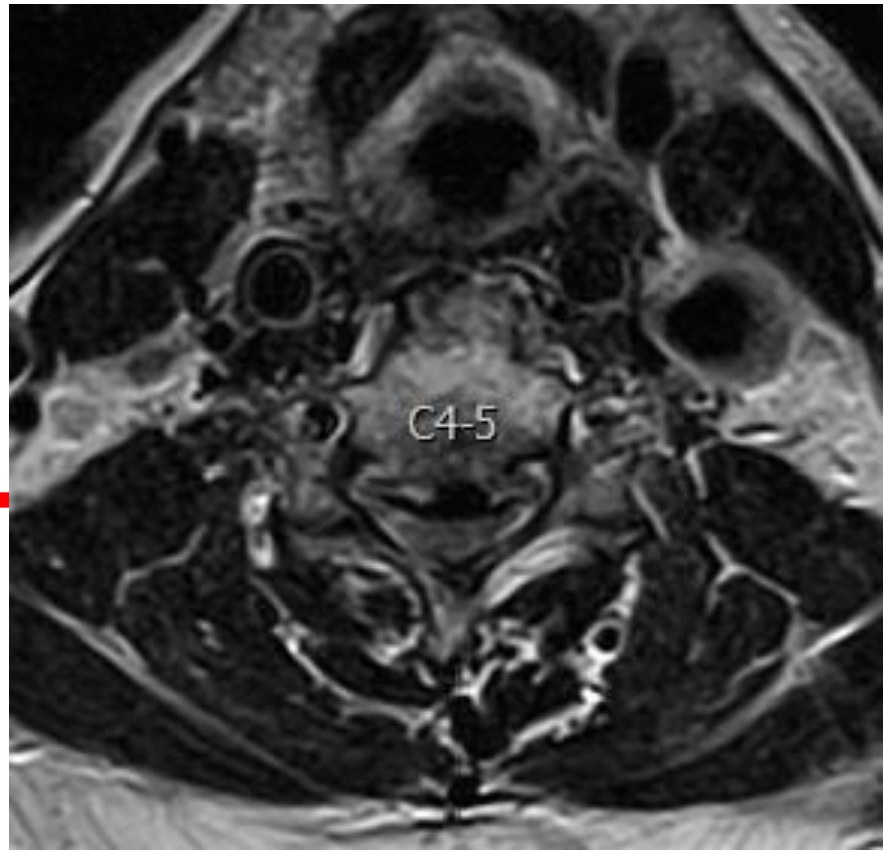

OrthoACCESS
© 2020 OrthoACCESS

Cervical Spine Case #2 (Cervical Stenosis/Myelopathy)

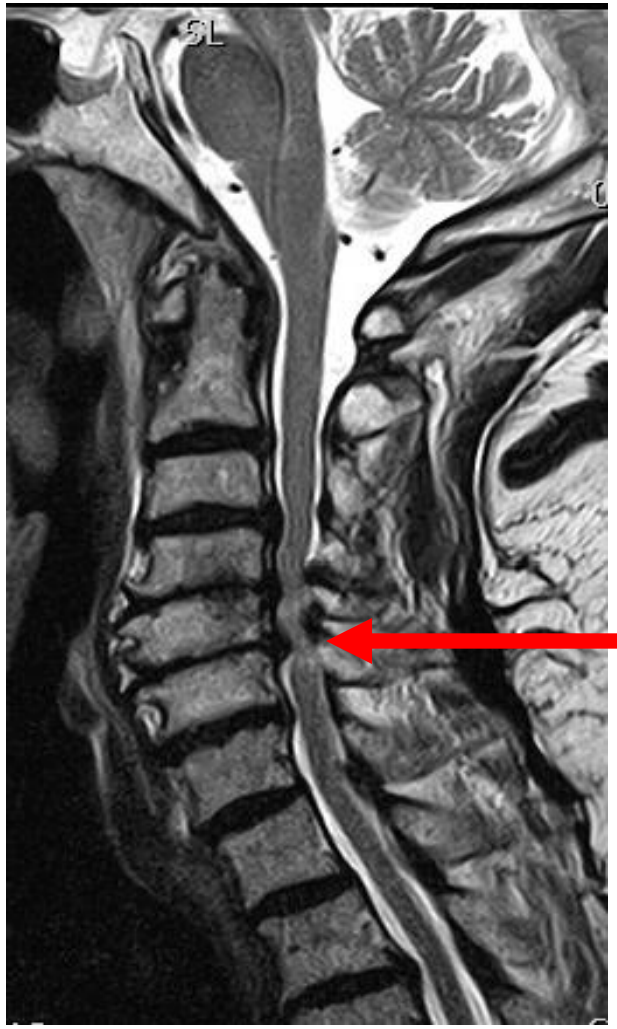

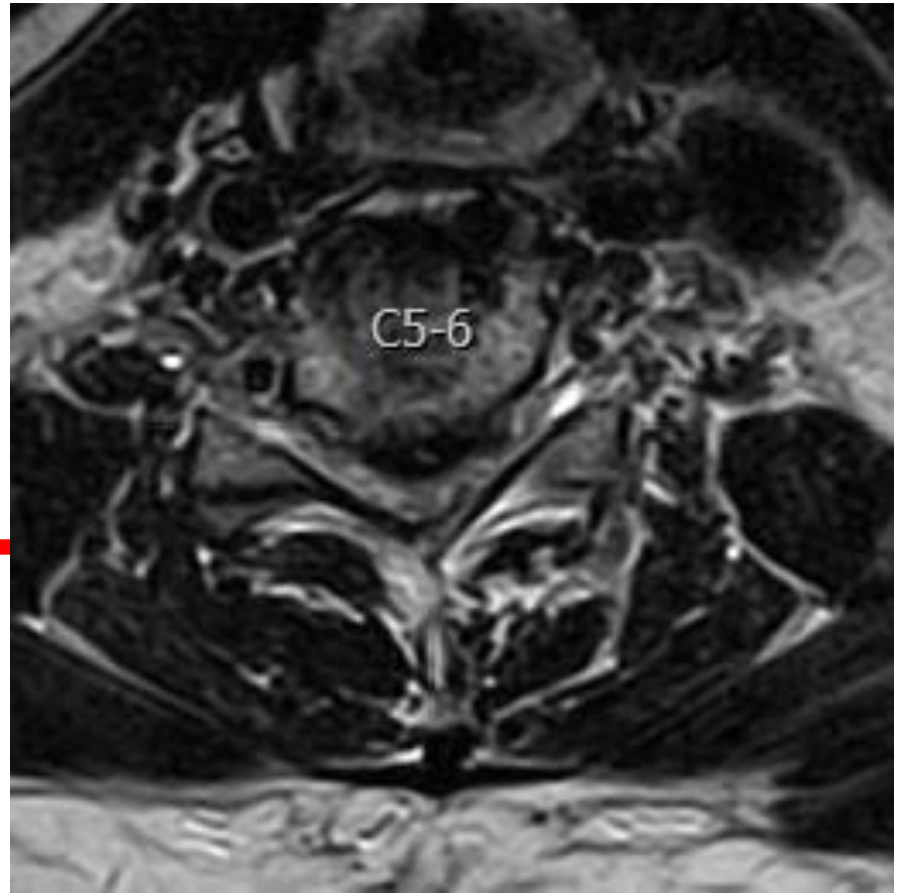

OrthoACCESS
© 2020 OrthoACCESS

Cervical Spine Case #2 (Cervical Stenosis/Myelopathy)





© 2020 OrthoACCESS

Lumbar Spine Anatomy

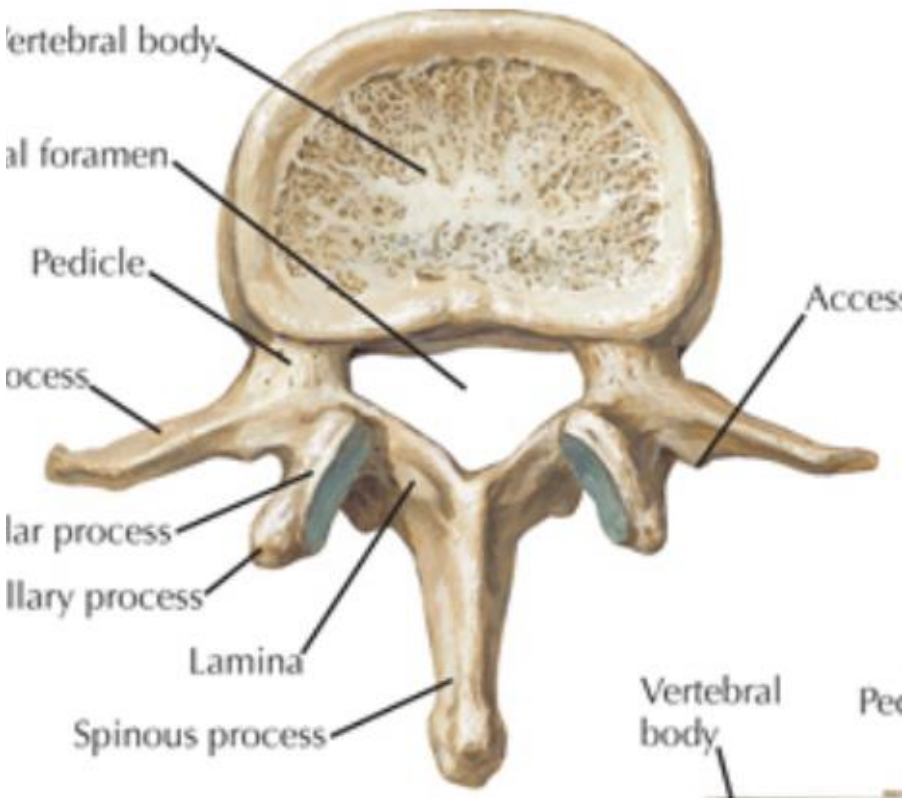

- Regions of the Canal
  - CENTRAL
  - LATERAL RECESS
  - FORAMINAL
- Causes of Stenosis
- Location of stenosis
  - Isolated Region
  - Tricompartmental
  - Foraminal

© 2020 OrthoACCESS

*Netter's Concise Orthopaedic Anatomy Second Edition, 2010 Saunders/Elsevier

Lumbar Spine Anatomy

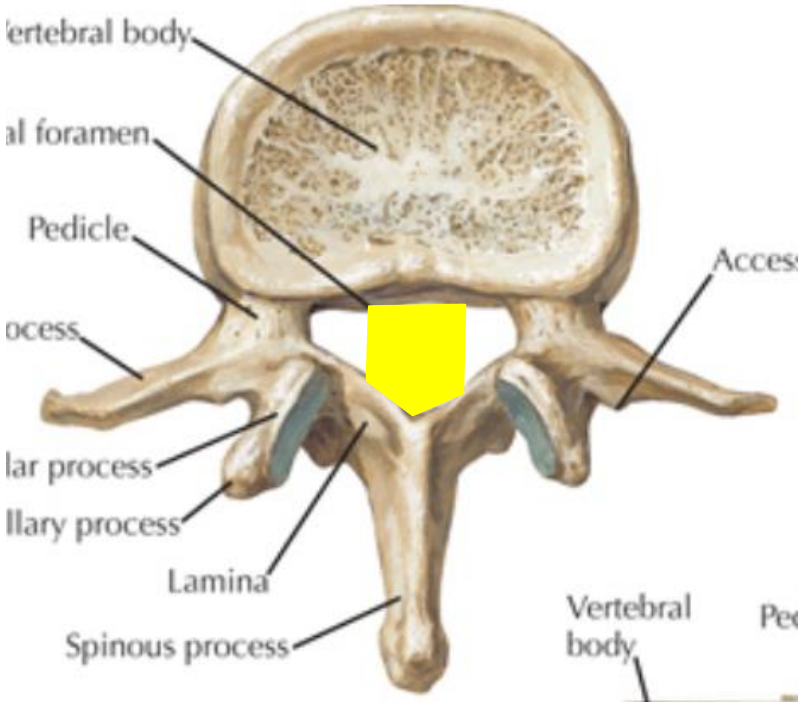

- Regions of the Canal
  - CENTRAL
  - LATERAL RECESS
  - FORAMINAL
- Causes of Stenosis
- Location of stenosis
  - Isolated Region
  - Tricompartmental
  - Foraminal

© 2020 OrthoACCESS

*Netter's Concise Orthopaedic Anatomy Second Edition, 2010 Saunders/Elsevier

Lumbar Spine Anatomy

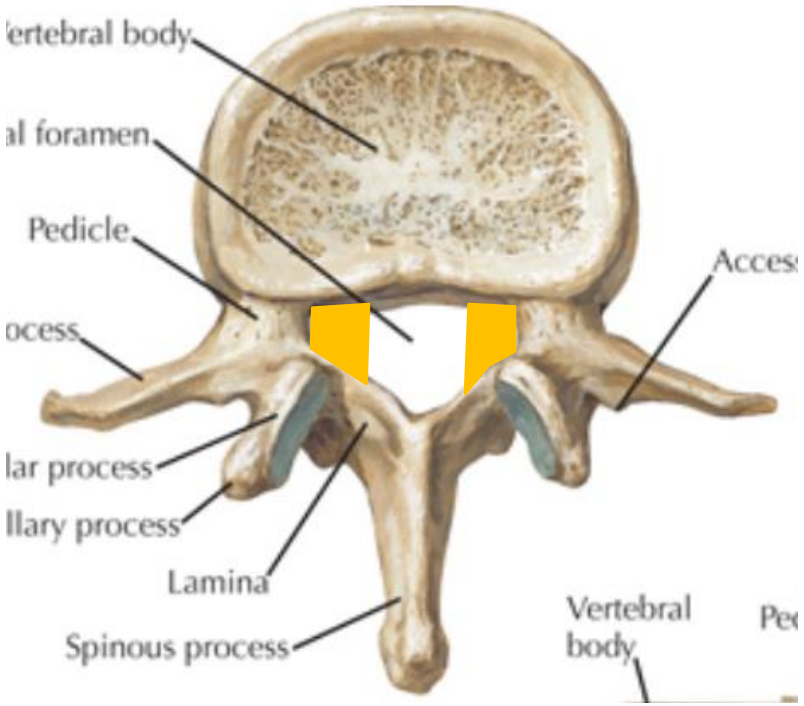

- Regions of the Canal
  - CENTRAL
  - LATERAL RECESS
  - FORAMINAL
- Causes of Stenosis
- Location of stenosis
  - Isolated Region
  - Tricompartmental
  - Foraminal

© 2020 OrthoACCESS

*Netter's Concise Orthopaedic Anatomy Second Edition, 2010 Saunders/Elsevier

Lumbar Spine Anatomy

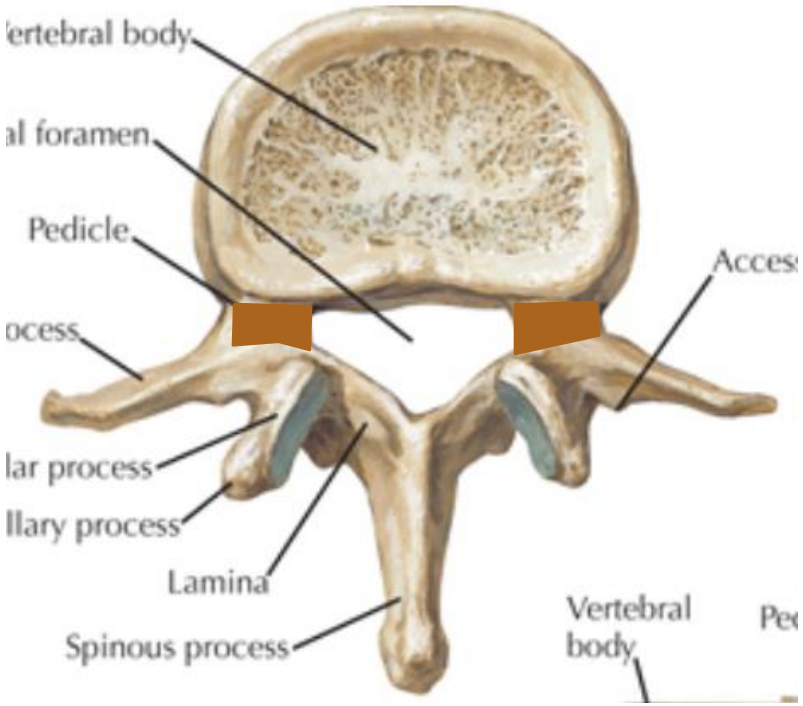

- Regions of the Canal
  - CENTRAL
  - LATERAL RECESS
  - FORAMINAL
- Causes of Stenosis
- Location of stenosis
  - Isolated Region
  - Tricompartmental
  - Foraminal

© 2020 OrthoACCESS

*Netter's Concise Orthopaedic Anatomy Second Edition, 2010 Saunders/Elsevier

Lumbar Spine Anatomy

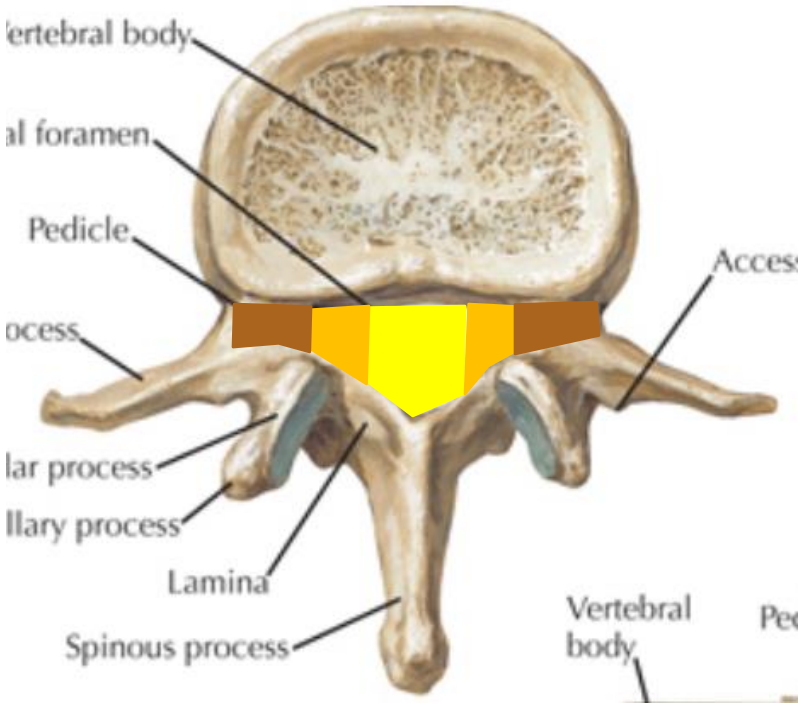

- Regions of the Canal
  - CENTRAL
  - LATERAL RECESS
  - FORAMINAL
- Causes of Stenosis
- Location of stenosis
  - Isolated Region
  - Tricompartmental
  - Foraminal

© 2020 OrthoACCESS

*Netter's Concise Orthopaedic Anatomy Second Edition, 2010 Saunders/Elsevier

Lumbar Spine Anatomy

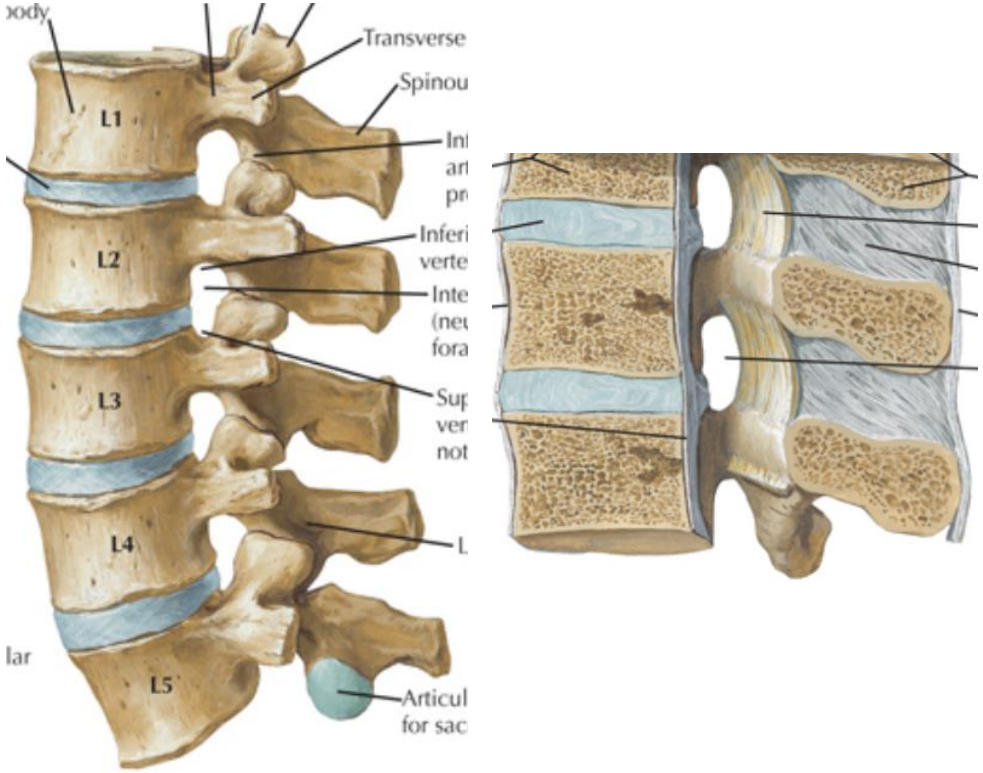

- Consider the Cranial to Caudal Dimension
  - Ligamentum Flavum
  - Disc Height Loss induced foraminal changes

© 2020 OrthoACCESS

*Netter's Concise Orthopaedic Anatomy Second Edition, 2010 Saunders/Elsevier

Lumbar Spine Anatomy

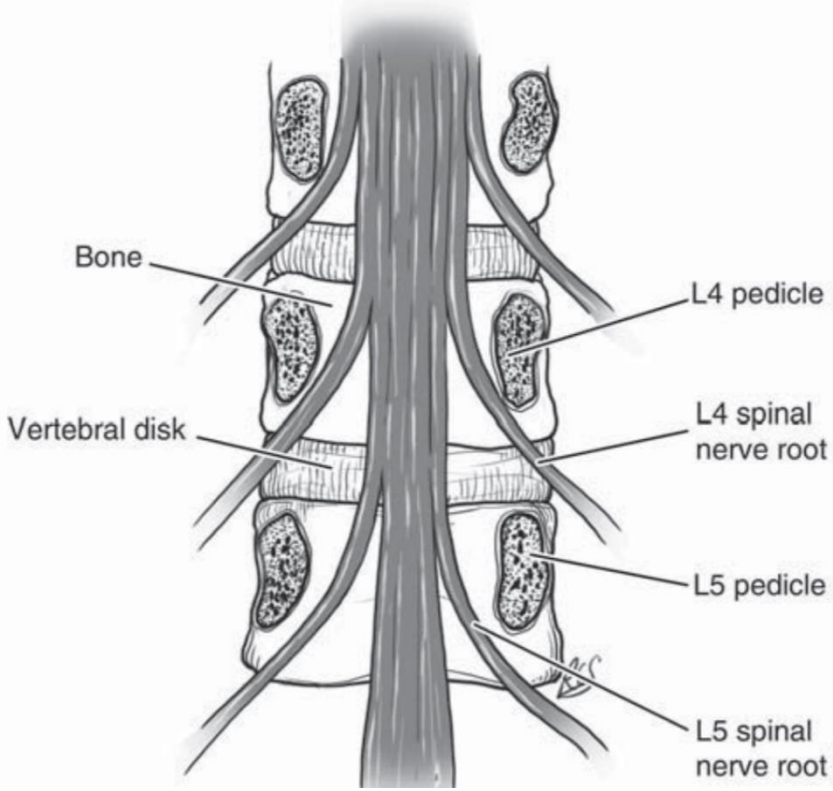

*AAOS Orthopaedic Knowledge Update: Spine 4 2012
American Academy of Orthopaedic Surgeons

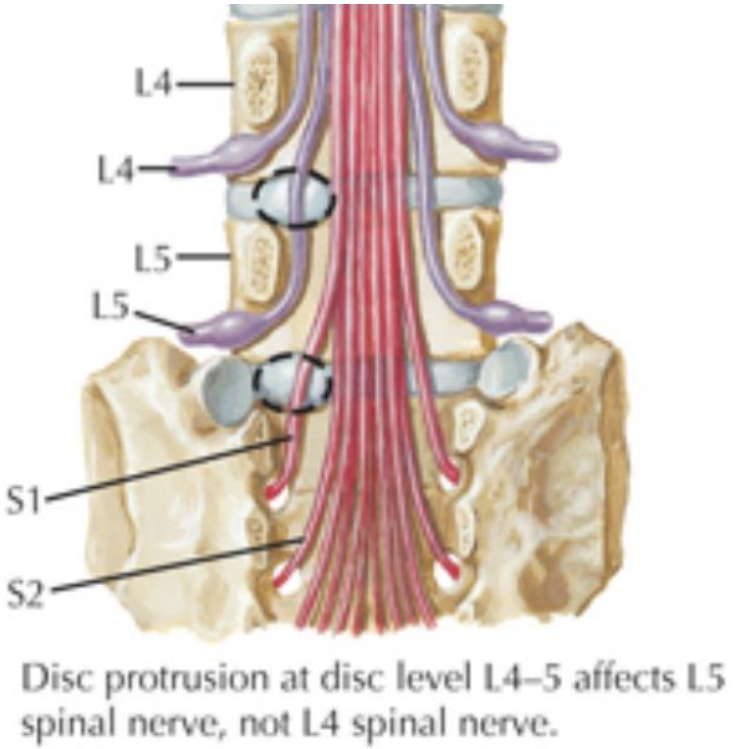

Disc protrusion at disc level L4–5 affects L5 spinal nerve, not L4 spinal nerve.

*Netter's Concise Orthopaedic Anatomy Second Edition, 2010 Saunders/Elsevier

© 2020 OrthoACCESS

Lumbar Spine Patient History

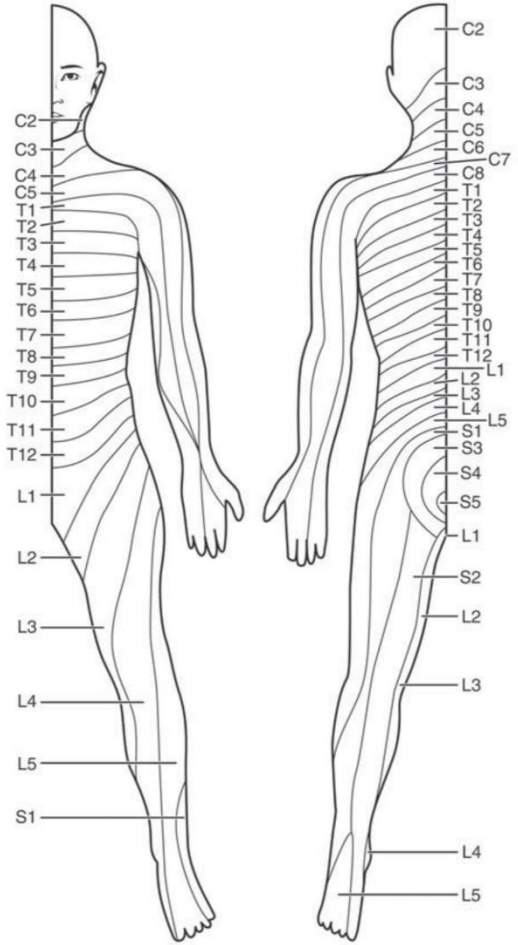

- Rule out RED FLAGS
- Determine hierarchy of symptoms
  - Weakness
  - Numbness
  - Back Pain
  - % Back Pain vs % Extremity Pain

© 2020 OrthoACCESS

*AAOS Orthopaedic Knowledge Update: Spine 4
2012 American Academy of Orthopaedic Surgeons

Lumbar Spine Examination

LEVEL	MOTOR	SENSORY	REFLEX
		LUMBOSACRAL ROOTS	
L1	Transversus abdominis Internal oblique	Inguinal region	None
L2	Psoas	Upper thigh	None
L3	Quadriceps	Anterior and medial thigh	None
L4	Tibialis anterior	Medial leg, ankle, f[illegible]	P[illegible]r
L5	Extensor hallux longus	Dorsal/plantar foot, [illegible] web space, lateral leg	H[illegible]ring
S1	Gastrocnemius	Lateral foot, posterior leg	Achilles
S2-4	Sphincter	Perianal sensation	Anal wink

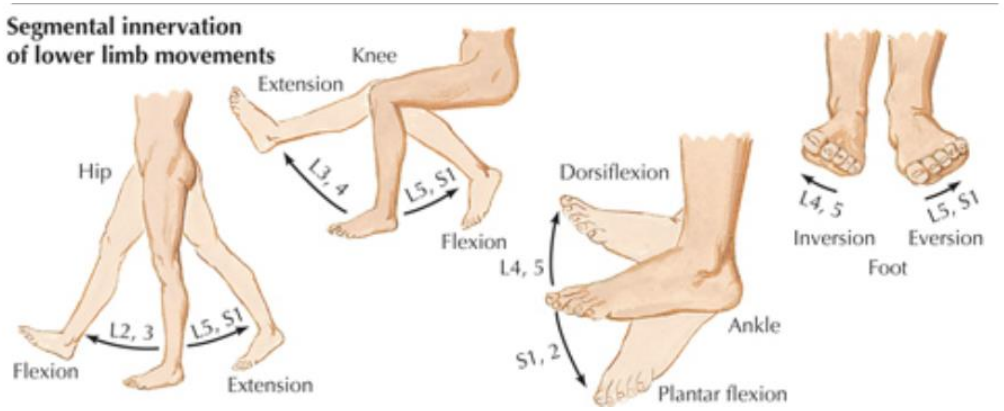

- Strength Exam (L2-S1)
- Sensory Exam (L2-S1)
- Reflexes
- Gait
- Special Tests
  - Straight Leg Raise
  - Babinski
  - Ankle Clonus
  - Patrick's/FABER Exam

© 2020 OrthoACCESS

*Netter's Concise Orthopaedic Anatomy Second Edition, 2010 Saunders/Elsevier

Lumbar Spine Case #1

- **34F presents with radiating LEFT leg pain and states that her LEFT foot “slaps” the ground while walking (FOOT DROP).**

© 2020 OrthoACCESS

Lumbar Spine Case #1

- **34F presents with radiating LEFT leg pain and states that the LEFT "slaps" the ground while walking (FOOT DROP).**
- Steppage gait, Normal bowel/bladder function
- STRENGTH: 2/5 LEFT ankle dorsiflexion otherwise non-focal
- SENSATION: Impaired over the LEFT foot 1st dorsal web space
- REFLEXES: Symmetric Globally
- SPECIAL TESTS: Positive Straight Leg Raise (LEFT LEG)

© 2020 OrthoACCESS

Lumbar Spine Case #1



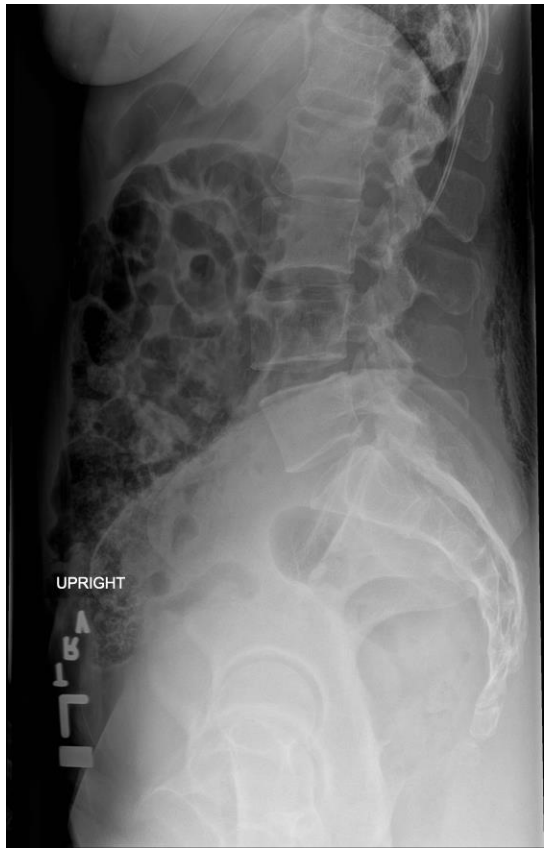

© 2020 OrthoACCESS

Lumbar Spine Case #1 (Disc Herniation/Radiculopathy)



© 2020 OrthoACCESS

Lumbar Spine Case #1 (Disc Herniation/Radiculopathy)

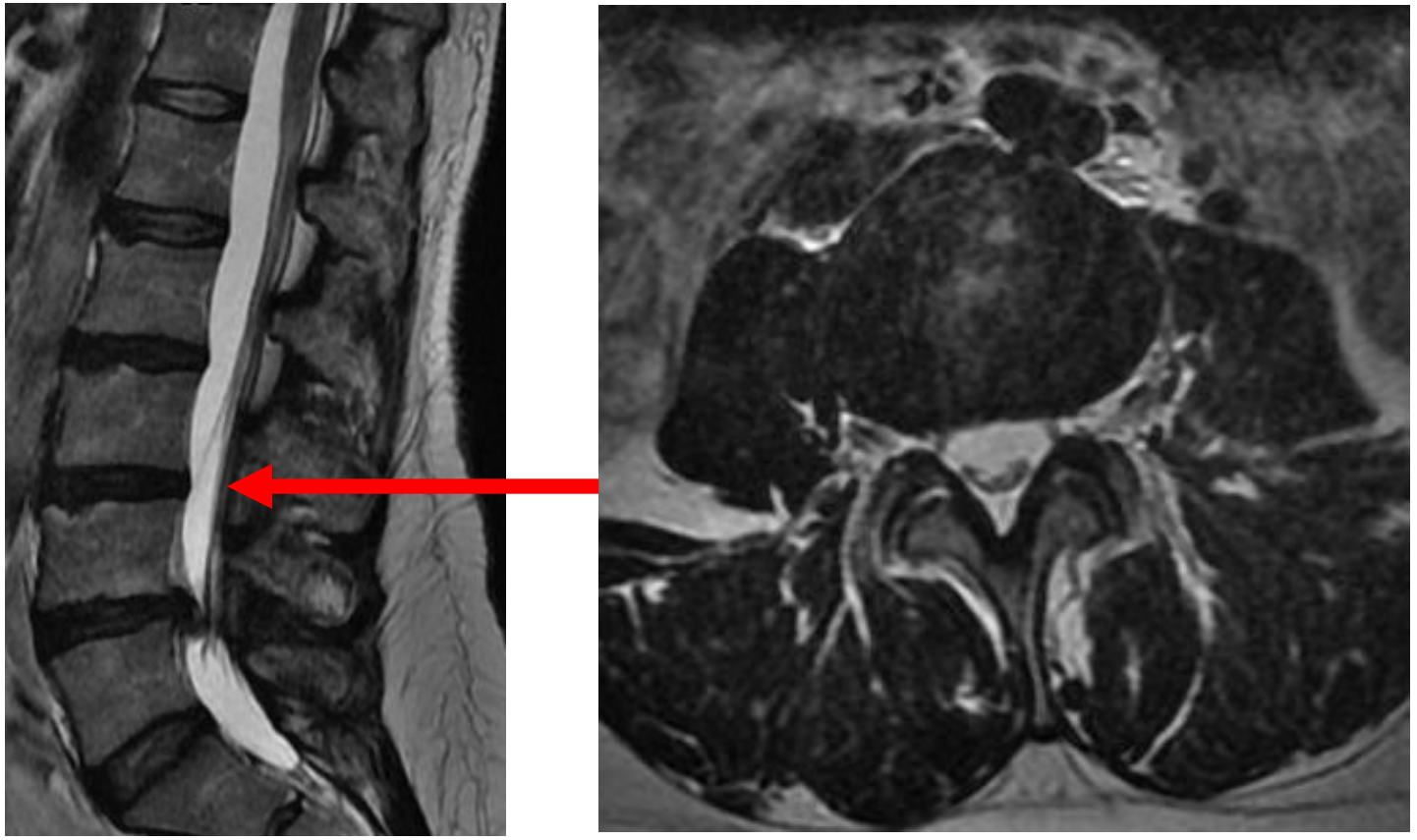

© 2020 OrthoACCESS

Lumbar Spine Case #1 (Disc Herniation/Radiculopathy)



© 2020 OrthoACCESS

Lumbar Spine Case #1 (Disc Herniation/Radiculopathy)

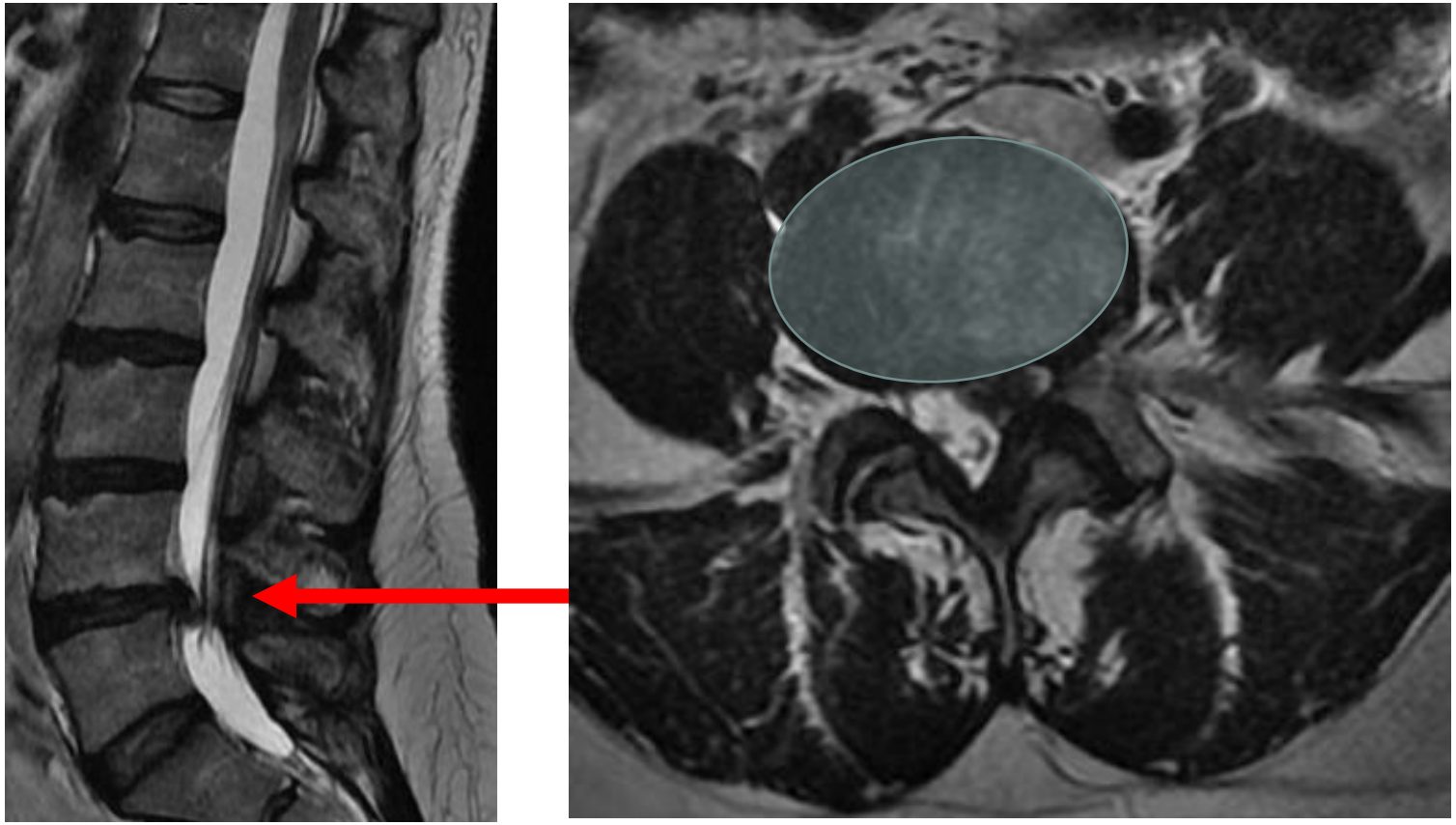

© 2020 OrthoACCESS

Lumbar Spine Case #1 (Disc Herniation/Radiculopathy)

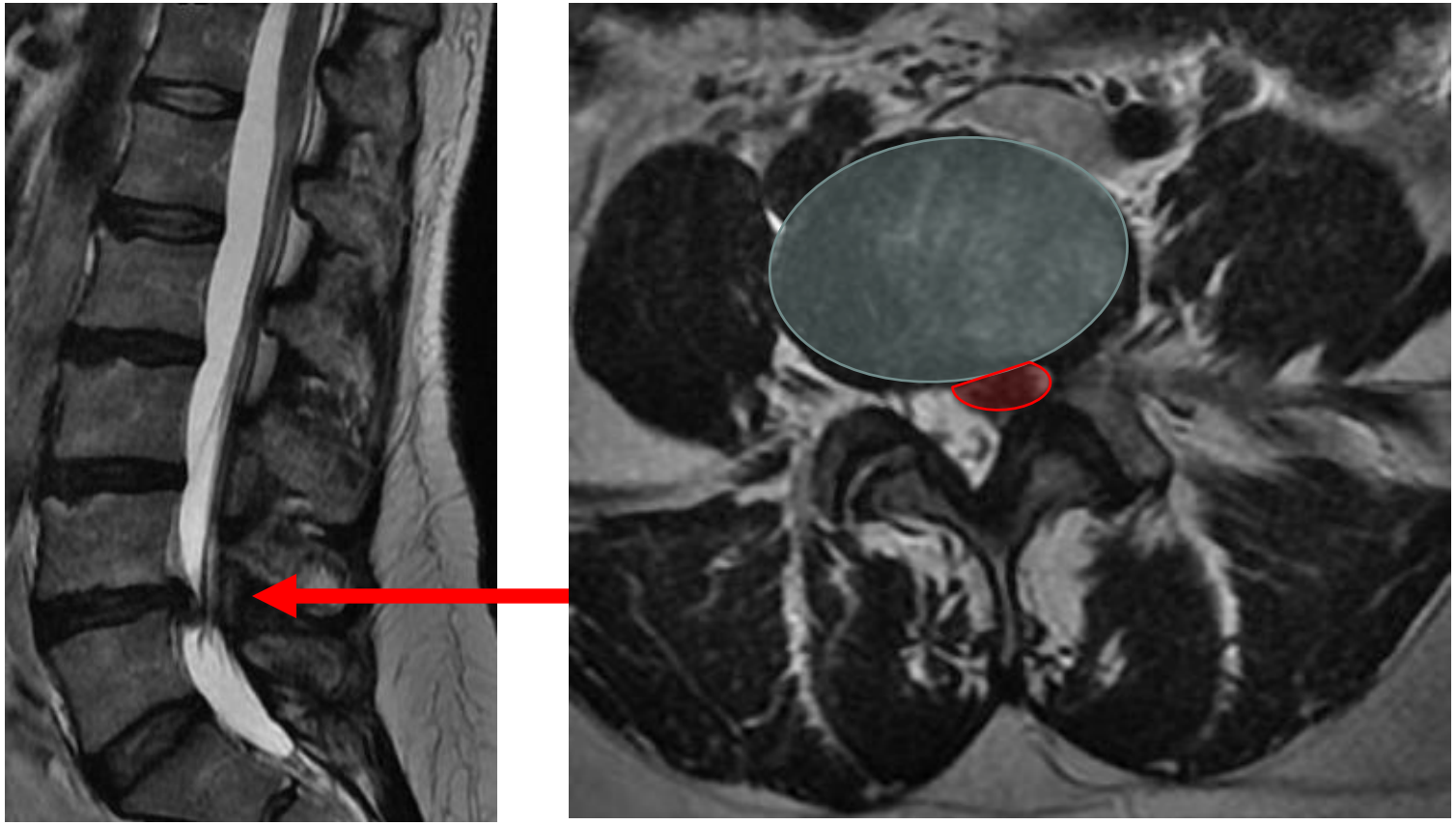

© 2020 OrthoACCESS

Lumbar Spine Case #1 (Disc Herniation/Radiculopathy)

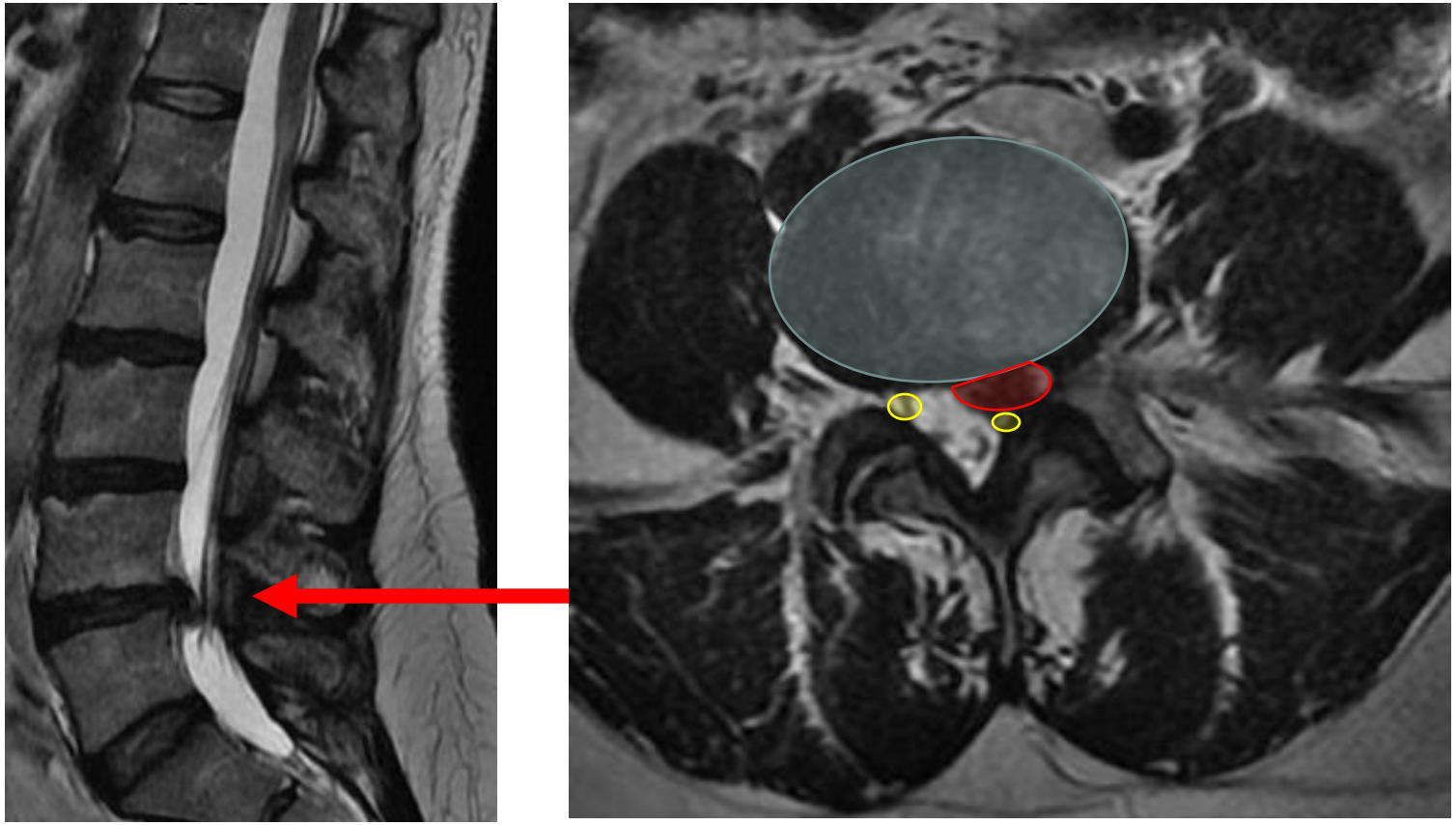

© 2020 OrthoACCESS

Lumbar Spine Case #1 (Disc Herniation/Radiculopathy)

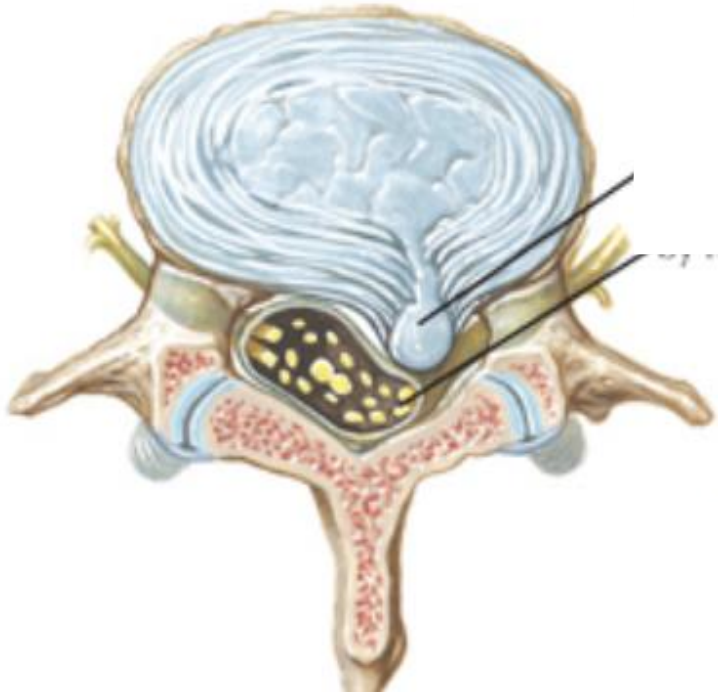

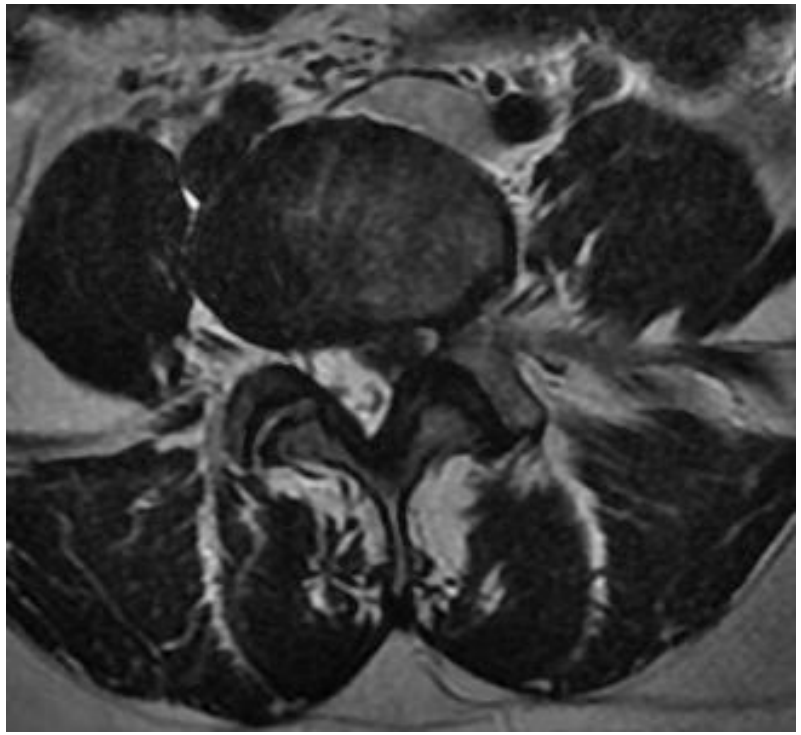

© 2020 OrthoACCESS

*Netter's Concise Orthopaedic Anatomy Second Edition, 2010 Saunders/Elsevier

Lumbar Spine Case #1 (Disc Herniation/Radiculopathy)

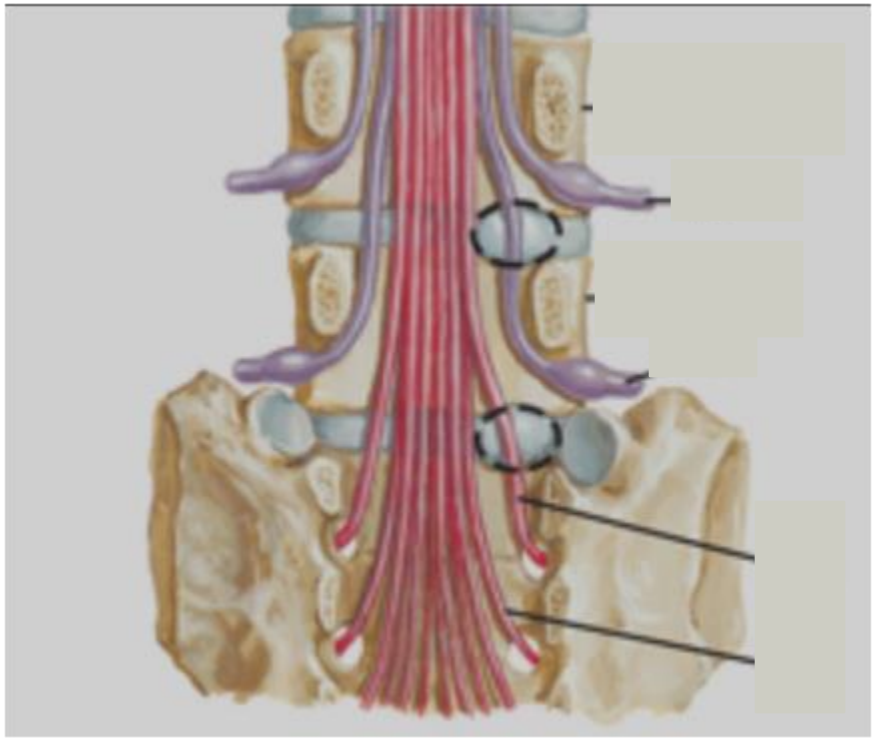

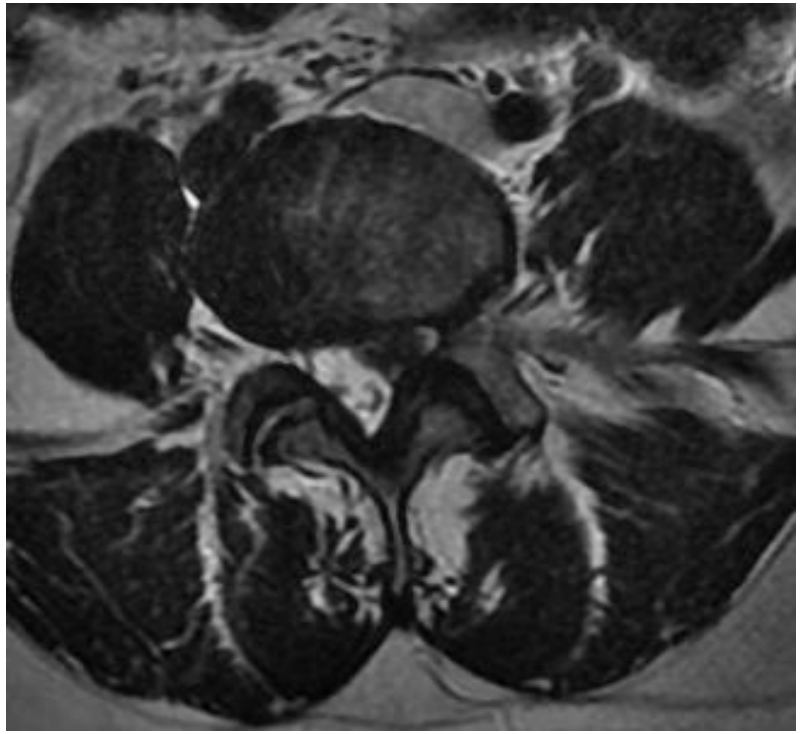

© 2020 OrthoACCESS

*Netter's Concise Orthopaedic Anatomy Second Edition, 2010 Saunders/Elsevier

Lumbar Spine Case #1 (Disc Herniation/Radiculopathy)

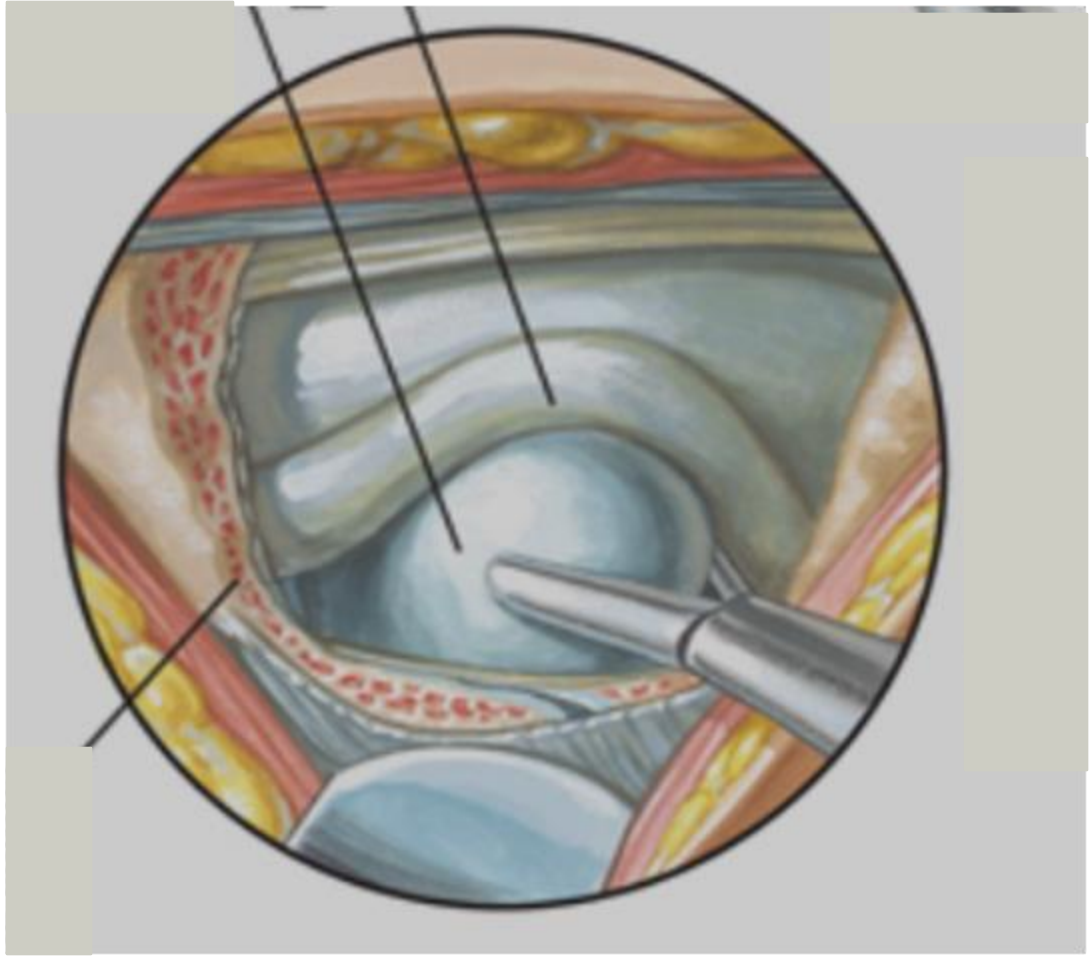

*Netter's Concise Orthopaedic Anatomy Second Edition, 2010 Saunders/Elsevier

© 2020 OrthoACCESS

Lumbar Spine Case #1 (Disc Herniation/Radiculopathy)

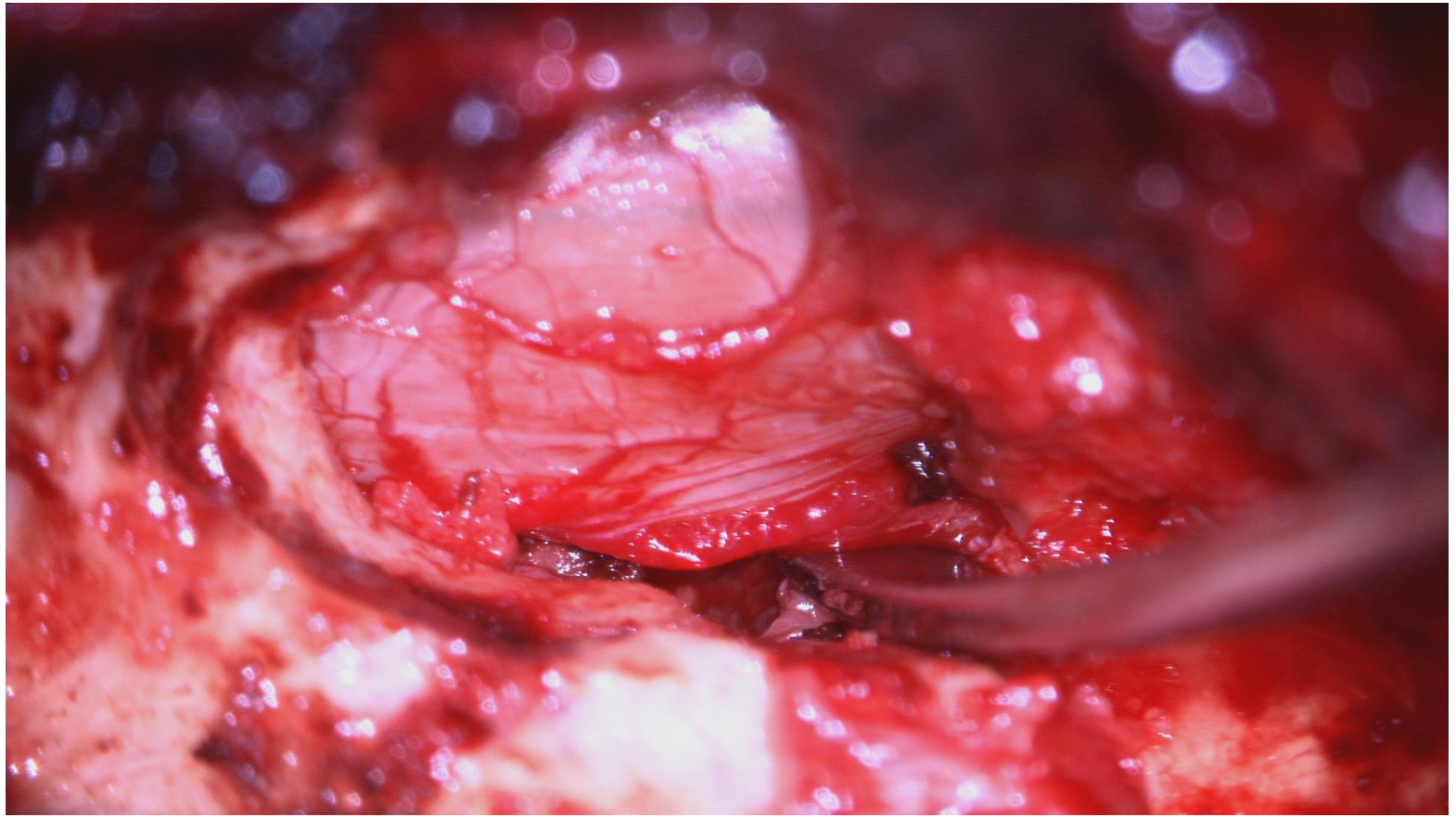

© 2020 OrthoACCESS

Lumbar Spine Case #1 (Disc Herniation/Radiculopathy)

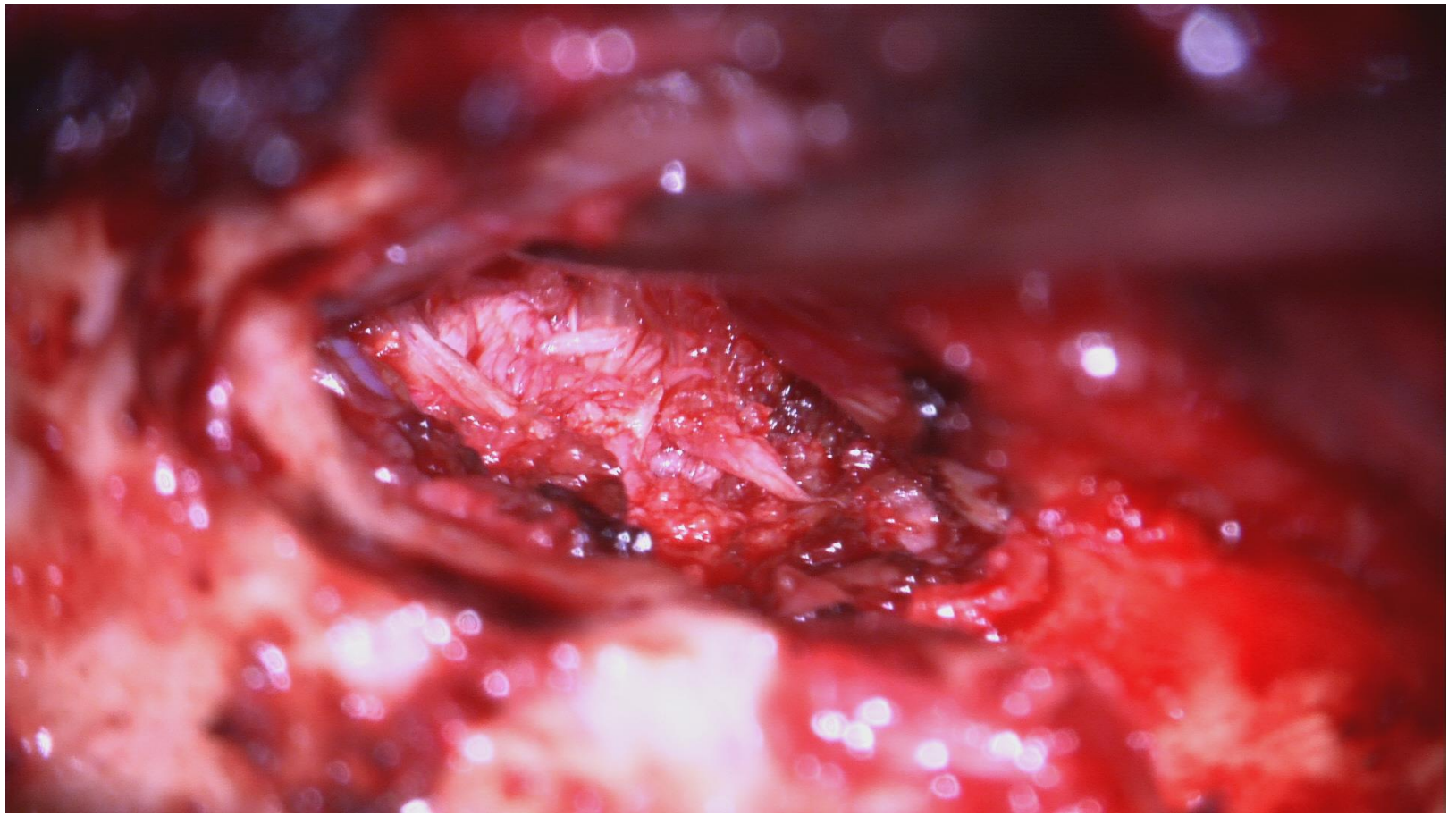

© 2020 OrthoACCESS

Lumbar Spine Case #2

- 57M presents with decreased walking tolerance & bilateral lower extremity “numbness and heaviness” with ambulation

© 2020 OrthoACCESS

Lumbar Spine Case #2

- **57M presents with decreased walking tolerance & bilateral lower extremity "numbness and heaviness" with ambulation**
- Legs feel "HEAVY" when walking > 1 city block
- STRENGTH: Seated strength examination is 5/5 and symmetric
- SENSATION: Seated examination is symmetric and without focal deficit ****BILATERAL LOWER EXTREMITY NUMBNESS AND TINGLING WHEN STANDING****
- REFLEXES: Globally Diminished
- SPECIAL TESTS: Unremarkable

© 2020 OrthoACCESS

Lumbar Spine Case #2





© 2020 OrthoACCESS

Lumbar Spine Case #2



OrthoACCESS
© 2020 OrthoACCESS

Lumbar Spine Case #2

(Lumbar Stenosis/Neurogenic Claudication)

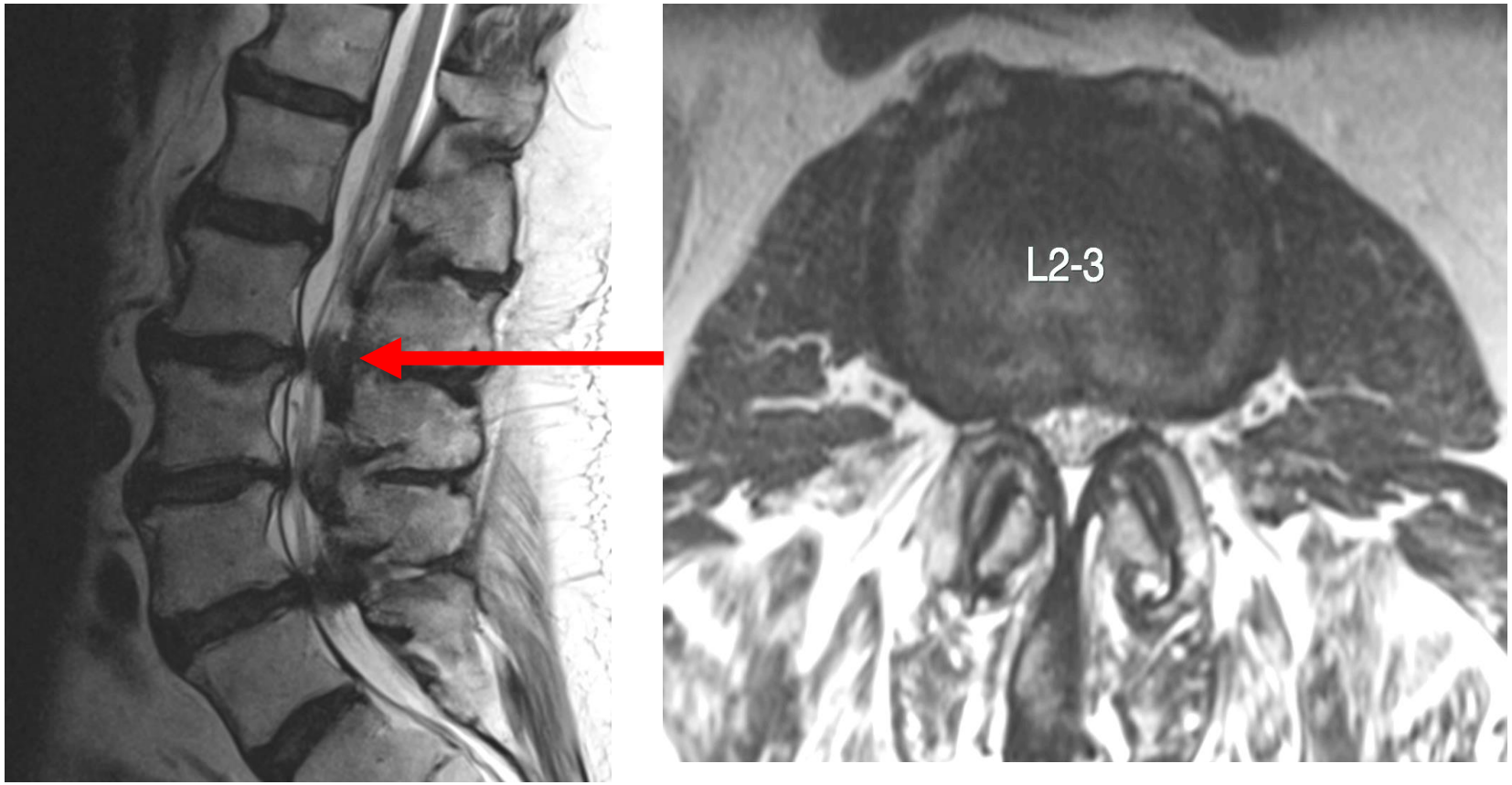

© 2020 OrthoACCESS

Lumbar Spine Case #2

(Lumbar Stenosis/Neurogenic Claudication)

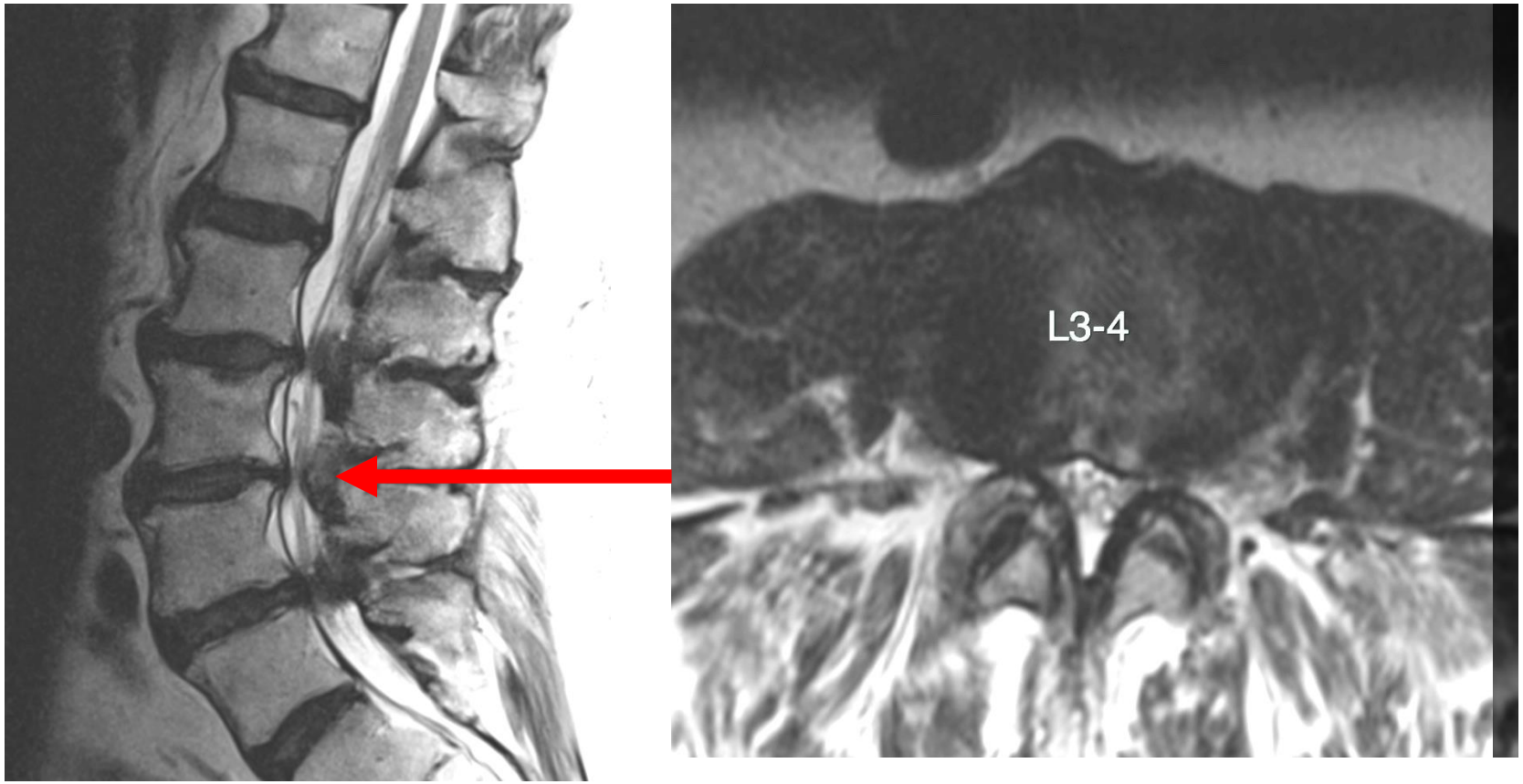

© 2020 OrthoACCESS

Lumbar Spine Case #2

(Lumbar Stenosis/Neurogenic Claudication)

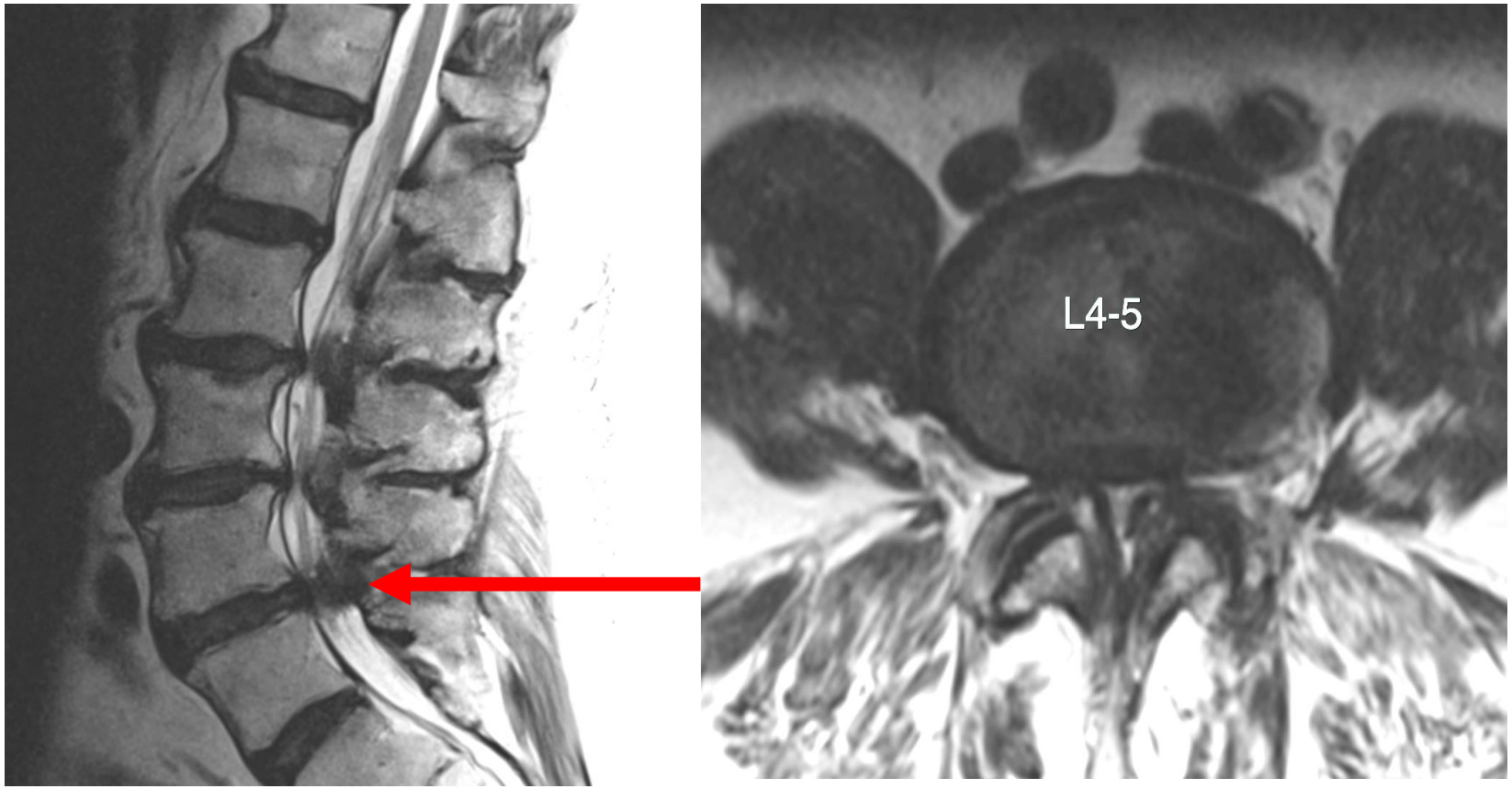

© 2020 OrthoACCESS

Lumbar Spine Case #2

(Lumbar Stenosis/Neurogenic Claudication)

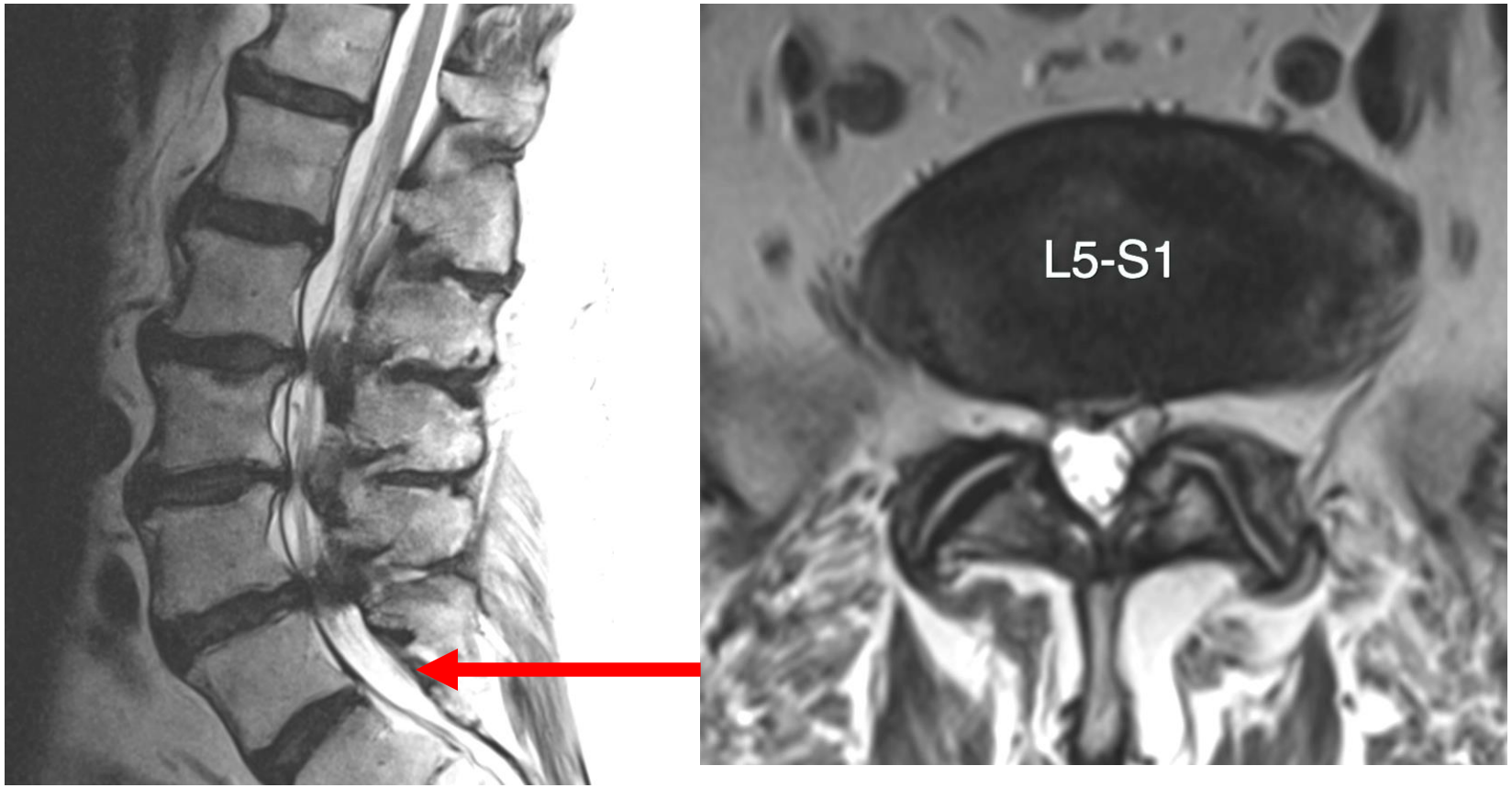

© 2020 OrthoACCESS

Lumbar Spine Case #2

(Lumbar Stenosis/Neurogenic Claudication)



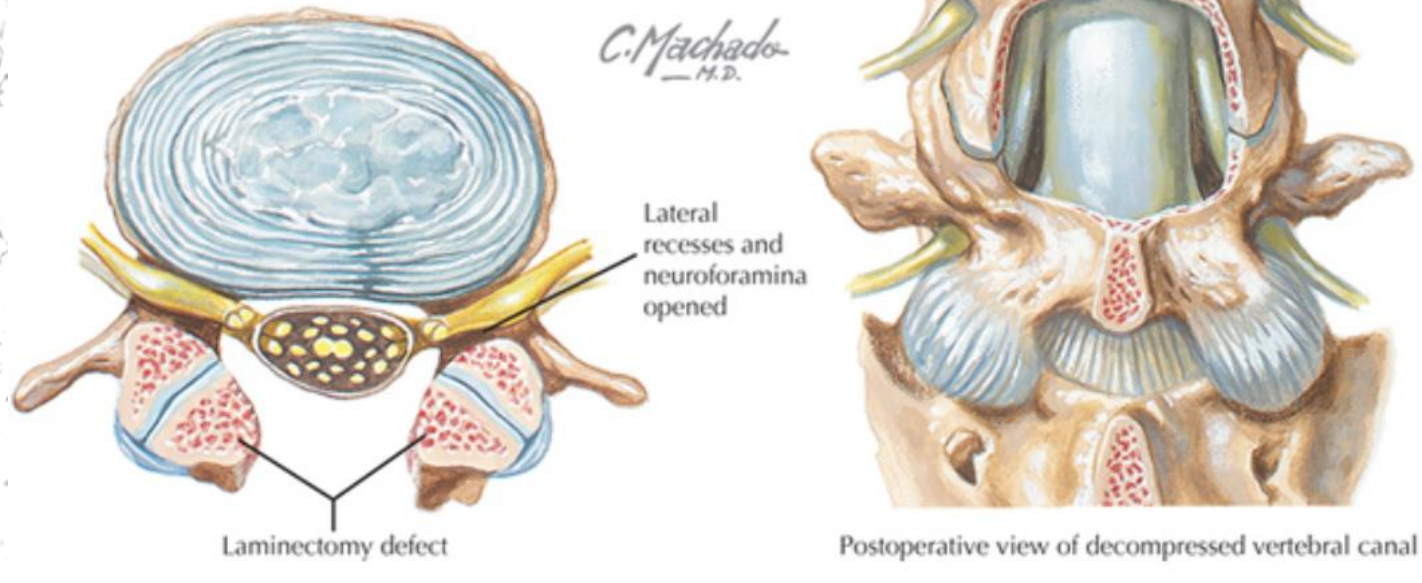

© 2020 OrthoACCESS

*Netter's Concise Orthopaedic Anatomy Second Edition, 2010 Saunders/Elsevier

Lumbar Spine Case #2

(Lumbar Stenosis/Neurogenic Claudication)

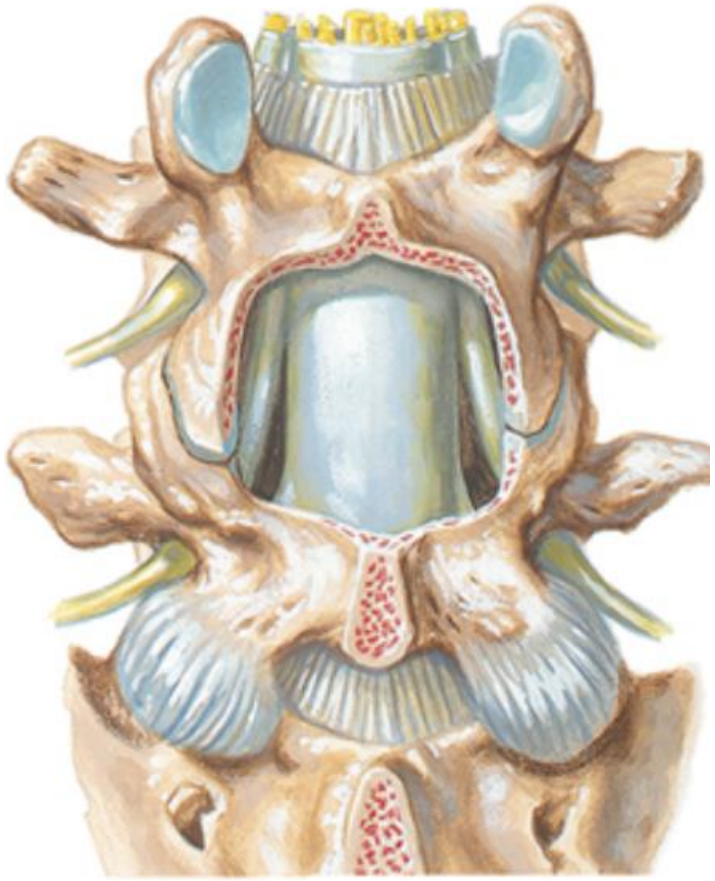

*Netter's Concise Orthopaedic Anatomy
Second Edition, 2010 Saunders/Elsevier

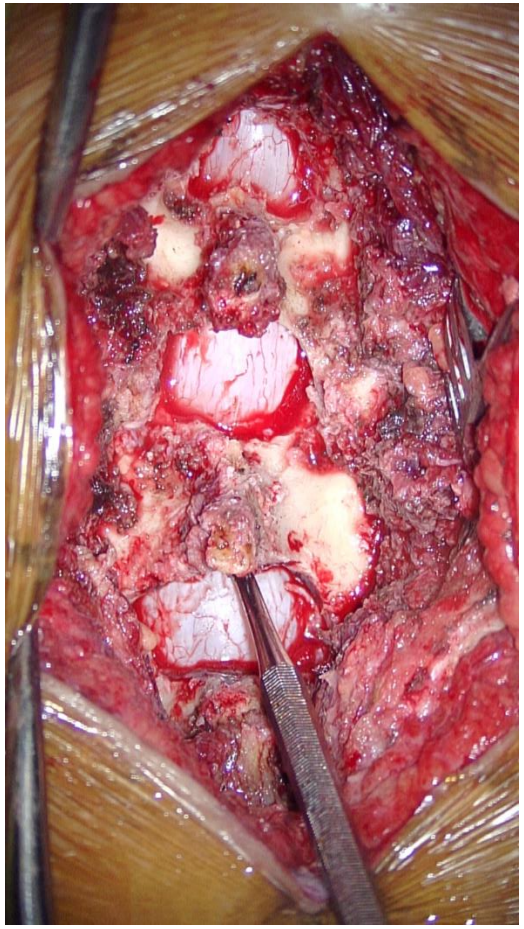

*Image provided by Dr. Mostafa El Dafrawy
(Lamina Sparing Decompression)

© 2020 OrthoACCESS

Low Back Pain

- Very Common Complaint
- Exam
  - Location
  - Provocative Positions
- 3 common etiologies (AMONG MANY!)

© 2020 OrthoACCESS

Low Back Pain (Mechanical)

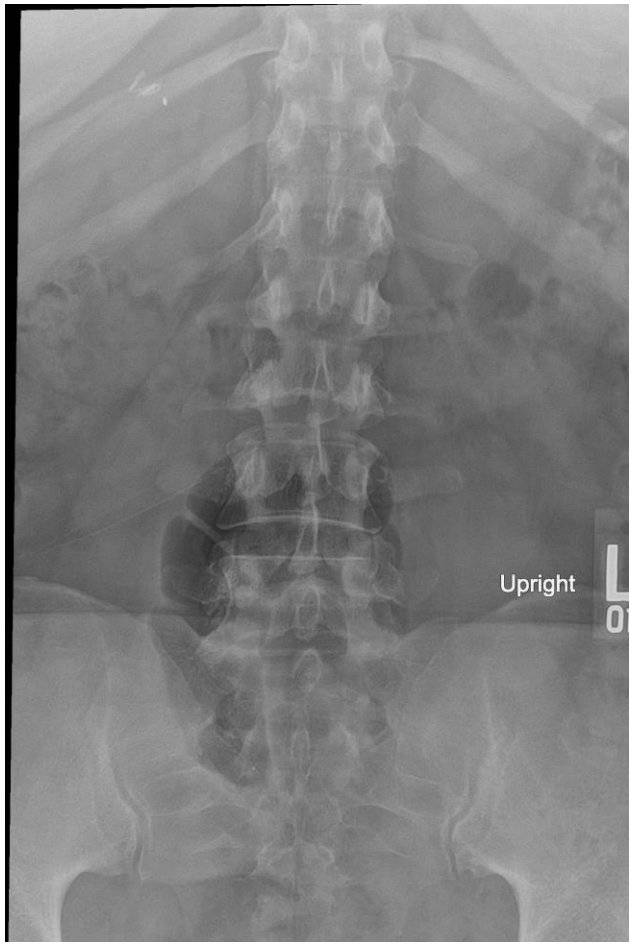

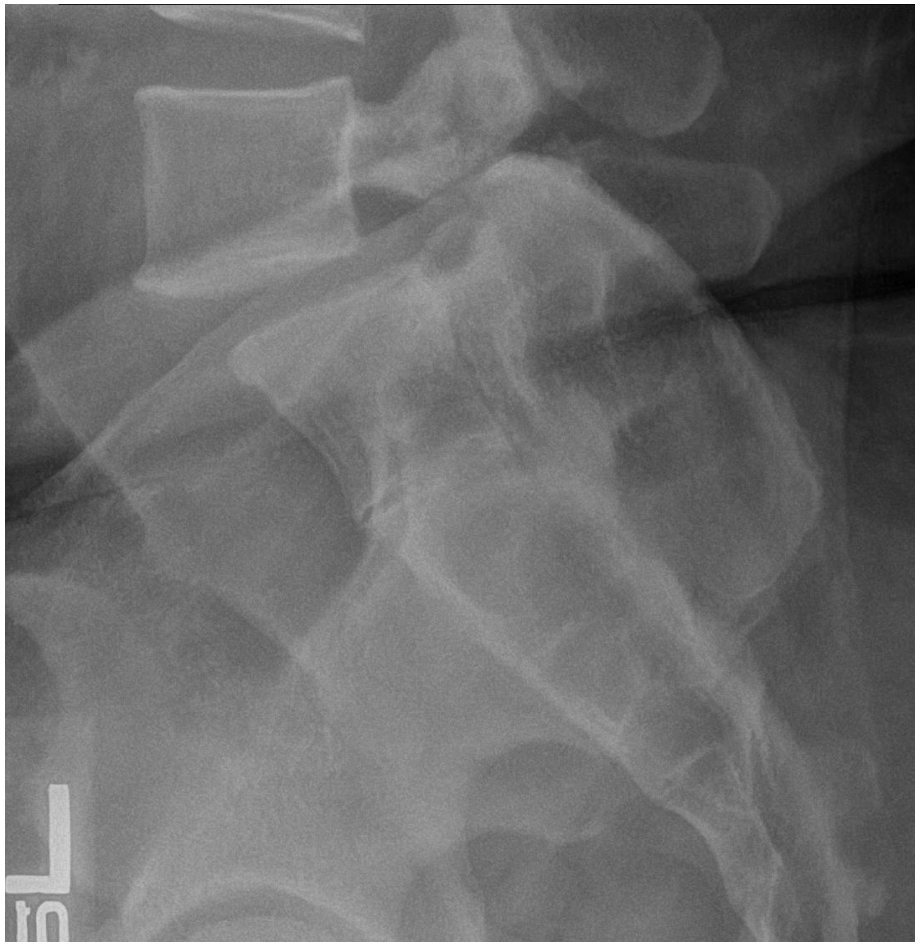

© 2020 OrthoACCESS

Low Back Pain (Mechanical)

UPRIGHT PLAIN FILMS



SUPINE CT

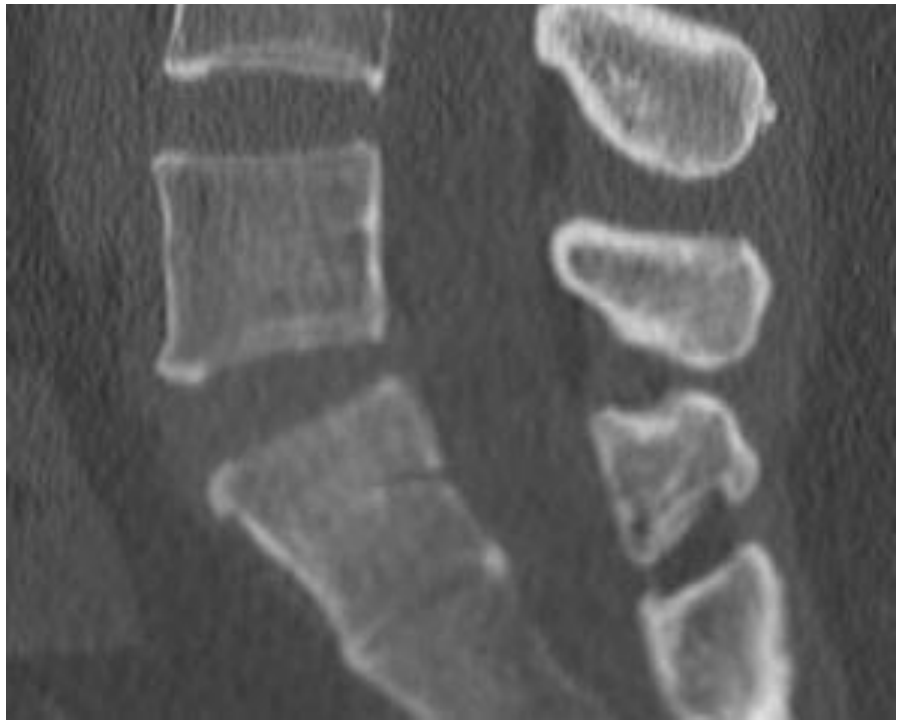

© 2020 OrthoACCESS

Low Back Pain (Mechanical)



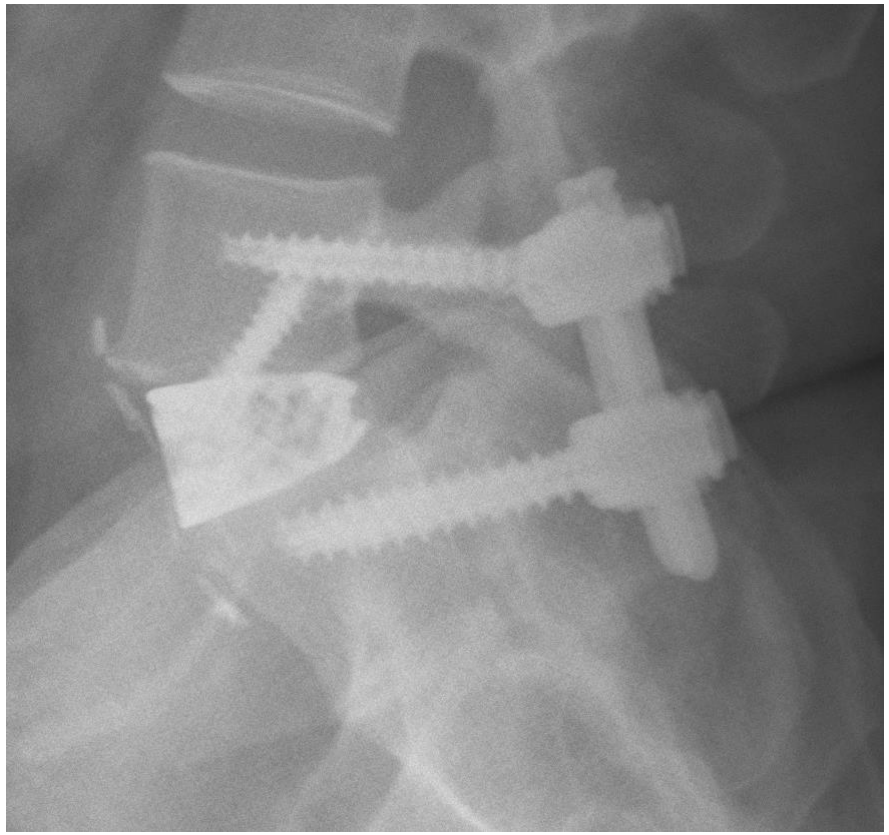

© 2020 OrthoACCESS

Low Back Pain (Facetogenic)

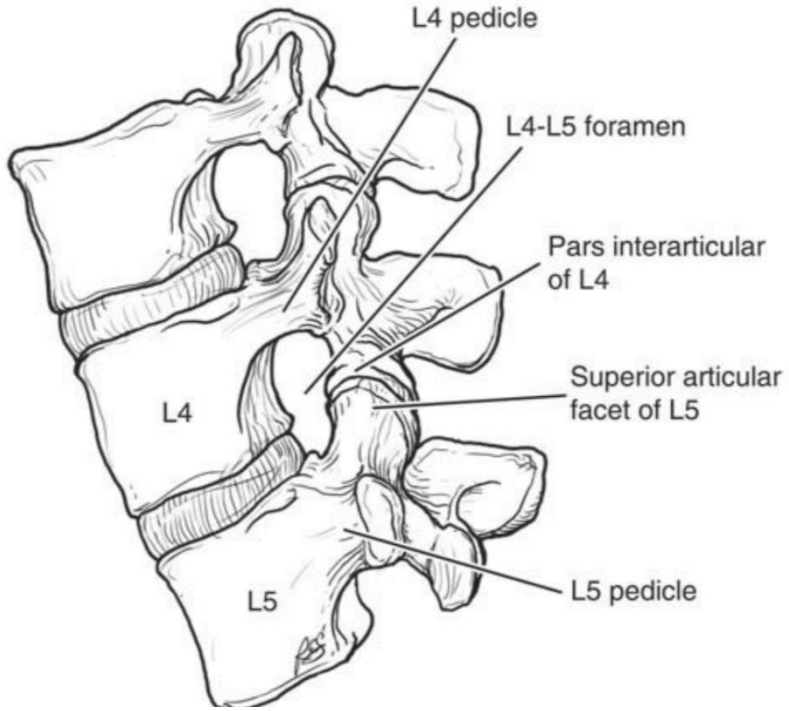

- Spinal Motion Unit

© 2020 OrthoACCESS

*AAOS Orthopaedic Knowledge Update: Spine 4
2012 American Academy of Orthopaedic Surgeons

Low Back Pain (Facetogenic)





OrthoACCESS
© 2020 OrthoACCESS

Low Back Pain (Facetogenic)

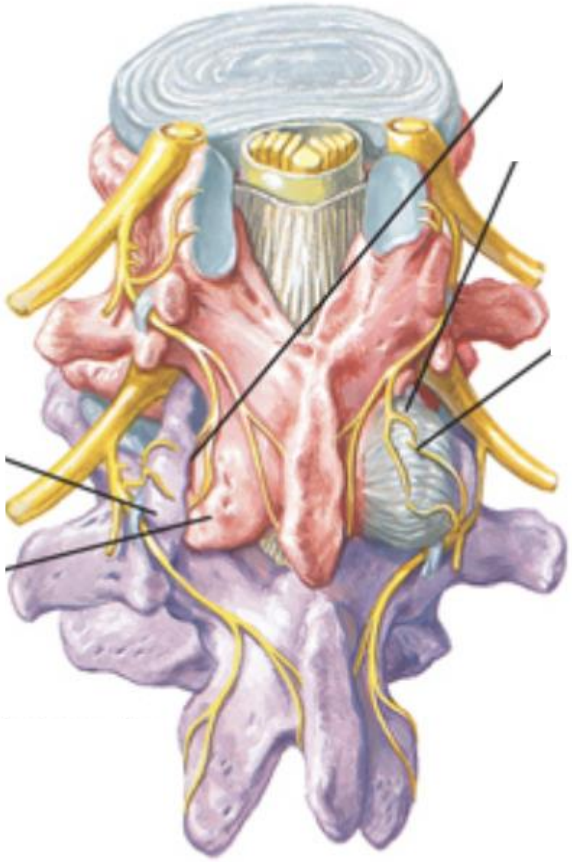

- Facet Injection
- Medial Branch Block
- Radiofrequency Ablation

OrthoACCESS
© 2020 OrthoACCESS

Low Back Pain (Sacroiliac)

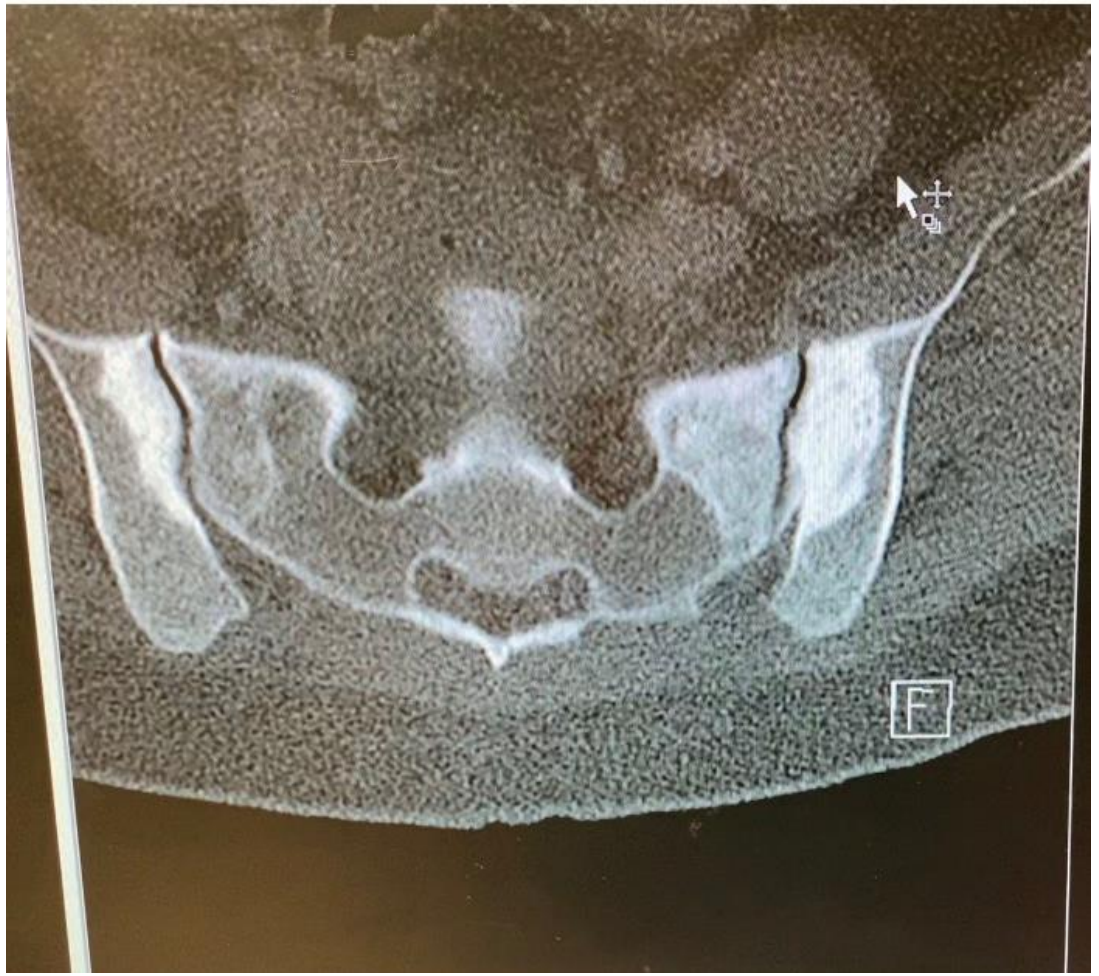

© 2020 OrthoACCESS

Additional Resources

- AAOS Orthopaedic Knowledge Update: Spine 5

  2018 American Academy of Orthopaedic Surgeons

- Surgical Management of Lumbar ***Degenerative*** Spondylolisthesis

  Journal of the AAOS: Apr 2014 - Vol 22 - Iss 4 - p 203-213

- Anterior Approach to the Subaxial Cervical ***Spine***: Pearls and Pitfalls

  Journal of the AAOS: Mar 2021 - Vol 29 - Iss 5 - p 189-195

- The Anatomic Relation Among the Nerve Roots, Intervertebral Foramina, and Intervertebral Discs of the Cervical Spine

  SPINE: Vol 25 (2000), Num 3, p 286–291

© 2020 OrthoACCESS