

# Preliminary Results of Interstitial Motexafin Lutetium-Mediated PDT for Prostate Cancer

K.L. Du, MD, PhD,<sup>1</sup> R. Mick, MS,<sup>2</sup> T.M. Busch, PhD,<sup>1</sup> T.C. Zhu, PhD,<sup>1</sup> J.C. Finlay, PhD,<sup>1</sup> G. Yu, PhD,<sup>4</sup> A.G. Yodh, PhD,<sup>4</sup> S.B. Malkowicz, MD,<sup>3</sup> D. Smith, BSN,<sup>1</sup> R. Whittington, MD,<sup>1</sup> D. Stripp, MD,<sup>1</sup> and S.M. Hahn, MD<sup>1\*</sup>

<sup>1</sup>Department of Radiation Oncology, Hospital of the University of Pennsylvania, University of Pennsylvania School of Medicine, Philadelphia, Pennsylvania 19104

<sup>2</sup>Department of Biostatistics and Epidemiology, University of Pennsylvania School of Medicine, Philadelphia, Pennsylvania 19104

<sup>3</sup>Department of Urology, Hospital of the University of Pennsylvania, University of Pennsylvania School of Medicine, Philadelphia, Pennsylvania 19104

<sup>4</sup>Department of Physics and Astronomy, University of Pennsylvania, Philadelphia, Pennsylvania 19104

**Background and Objectives:** Interstitial photodynamic therapy (PDT) is an emerging modality for the treatment of solid organ disease. Our group at the University of Pennsylvania has performed extensive studies that demonstrate the feasibility of interstitial PDT for prostate cancer. Our preclinical and clinical experience is herein detailed.

**Study Design/Materials and Methods:** We have treated 16 canines in preclinical studies, and 16 human subjects in a Phase I study, using motexafin lutetium-mediated PDT for recurrent prostate adenocarcinoma. Dosimetry of light fluence, drug level and oxygen distribution for these patients were performed.

**Results:** We demonstrate the safe and comprehensive treatment of the prostate using PDT. However, there is significant variability in the dose distribution and the subsequent tissue necrosis throughout the prostate.

**Conclusions:** PDT is an attractive option for the treatment of prostate adenocarcinoma. However, the observed variation in PDT dose distribution translates into uncertain therapeutic reproducibility. Our future focus will be on the development of an integrated system that is able to both detect and compensate for dose variations in real-time, in order to deliver a consistent overall PDT dose distribution. *Lasers Surg. Med.* 38:427–434, 2006.

© 2006 Wiley-Liss, Inc.

**Key words:** photodynamic therapy; prostate cancer; adenocarcinoma; motexafin lutetium

## PDT

Photodynamic therapy (PDT) is a promising modality of treatment for a variety of malignant and pre-malignant lesions [1,2], and is currently in use for patients with Barrett's esophagus with high grade dysplasia, obstructing esophageal cancers, and early and obstructing lung cancers. PDT activates a chemical photosensitizer by a specific light wavelength corresponding to the absorption characteristics of the photosensitizer, thereby leading to an oxygen-dependent photochemical reaction that leads to

singlet oxygen production and subsequent cellular damage. Since the radius of interaction for singlet oxygen is  $<0.2 \mu\text{m}$  and the half life is short,  $<0.04 \mu\text{seconds}$ , [3] only cells that are proximal to the area of activated photosensitizer are damaged. This allows for a laser-directed, highly localized area of tissue destruction. There are clear advantages of PDT over other therapies for localized disease, such as surgery or radiation therapy. PDT does not utilize ionizing radiation, appears not to target DNA, and has not been demonstrated to have the risk of secondary malignancies or late tissue side effects. Therefore, it is likely that repeated PDT sessions could be given for increased efficacy or for treatment of recurrent disease, with a lower likelihood of long-term morbidities as one might observe with radiation therapy. PDT, if appropriately applied, also appears to specifically damage the glandular epithelium of target tissues, and therefore maintains the stromal architecture of the organ, again minimizing the risk of secondary morbidities [4,5]. With respect to cancer treatment, PDT is an attractive therapy as there is little cross-resistance with chemotherapy or radiation therapy mechanisms [6], and unlike chemotherapy or radiation therapy, the effects of PDT are not cell cycle dependent [7].

The use of PDT has primarily been restricted to diseases of superficial depths, due to the limited depth of laser light penetration. The development of photosensitizers activated by longer wavelengths of light and associated with deeper light penetration has facilitated the development of interstitial PDT. Extensive experience in the treatment of prostate cancer with interstitial brachytherapy makes this

Contract grant sponsor: NCI; Contract grant number: R21 CA-88064.

\*Correspondence to: S.M. Hahn, MD, Department of Radiation Oncology, University of Pennsylvania, 3400 Spruce Street, 2 Donner, Philadelphia, PA 19104. E-mail: hahn@xrt.upenn.edu

Accepted 9 March 2006

Published online 19 June 2006 in Wiley InterScience (www.interscience.wiley.com).

DOI 10.1002/lsm.20341

disease an excellent model for the study of interstitial light delivery using existing knowledge for placement of brachytherapy implants within solid organs. Additionally, the prostate is an attractive target for interstitial light PDT due to the small size of the organ, allowing comprehensive treatment of the entire organ; the tendency for patients to present with organ-contained prostate cancer, allowing treatment of localized disease [8,9]; and readily assessable morbidities of treatment that are directly related to preservation or destruction of the overall structure of the prostate gland.

Prostate cancer is the most common visceral cancer in men in the United States [10]. Current treatments for early stage prostate cancer are radical prostatectomy, external beam radiation therapy, or brachytherapy. Androgen deprivation therapy is also a treatment option. Morbidities from these therapies are significant, including urinary incontinence, bowel symptoms, and impotence [11,12]. For patients who have recurrence after radiation therapy, salvage options are limited and include radical prostatectomy [13], cryosurgery [14], or an additional course of radiation therapy. These salvage therapies carry an increased risk of morbidities [15–17], and therefore novel modalities for the treatment of recurrent prostate cancer would be of considerable benefit to expanding patient treatment options and increasing quality of life. Several principles are important to consider in the design and optimization of PDT for prostate cancer:

- (1) Prostate cancer is a multifocal disease [18,19] and current imaging techniques cannot detect microscopic disease in the entire gland. Therefore, it is essential that any interstitial PDT approach provide comprehensive coverage throughout the entire gland.
- (2) The PDT dose must be controlled so that there is dose delivery to the prostate epithelium but sparing of the underlying stroma, therefore maintaining the structural integrity of the prostate gland.
- (3) Normal tissues, particularly the bladder, rectum, and neurovascular bundle must be spared significant damage from the PDT dose.
- (4) A sole and minimally invasive approach for drug and light delivery must be established in order to consider repeated treatments.

The effectiveness of PDT depends on the spatial and temporal interactions between photosensitizer, light, and oxygen. These variables include photosensitizer type, concentration, and biodistribution [20–29]; the wavelength, total dose, fluence rate, fractionation, and drug-to-light interval of light delivered; tissue optical properties [30–34]; and the tumor oxygenation state [35,36]. We, and others, have shown substantial intra- and inter-patient heterogeneity in these variables in prostate glands from patients with prostate cancer [37,38], which points to the need for individual dosimetry. The optimization of these three variables is critical for the design of future PDT studies.

## PRE-CLINICAL EXPERIENCE IN PROSTATE PDT

Our group performed a pre-clinical study of interstitial prostate PDT in a canine model using the second generation photosensitizer, motexafin lutetium [24]. Motexafin lutetium is a pentadentate aromatic metallotexaphyrin that has an absorption peak at 732 nm [39–41]. This longer activating light wavelength, extending into the far-red range, allows more optimal interstitial delivery due to greater depth of penetration, and less interference by hemoglobin. In this pre-clinical study, a laparotomy was performed for full exposure of the prostate gland. Placement of brachytherapy catheters was guided by a plexiglass template, and optical fibers were inserted into the catheters for light delivery to the gland. Fluence measurements taken with isotropic detectors demonstrated that the presence of the brachytherapy catheters did not interfere with light delivery to the tissues. The light fluence was prescribed by the power emitted from the fiber and not from the actual measured light dose detected in the prostate gland. A 3-hour drug-light interval was chosen because pre-clinical studies in other model systems demonstrated the greatest anti-tumor efficacy with this timing [40,42]. The primary endpoints of these studies were: (1) to determine the feasibility and toxicity of PDT to the prostate in this model, (2) to compare PDT delivered through an interstitial approach versus a transurethral approach, and (3) to develop a method to comprehensively treat the entire prostate gland.

In the initial study, four beagles were treated with motexafin lutetium 6 mg/kg IV followed 3 hours later by a light dose of 75 J/cm at 150 mW/cm. The goal of these initial experiments was to identify the tolerability of this dose of drug and light within a 2–3 week time frame and to evaluate the acute necrosis around both interstitial and transurethral treatment fibers. This study showed that the zone of tissue damage surrounding the interstitial fibers was irregular but approximately 1.2-cm in diameter. It was concluded that transurethral light delivery would not achieve the goal of comprehensive treatment of the prostate gland with PDT but might be an effective therapy for the treatment of periurethral glandular tissue. The diameter of the zone of necrosis, however, suggested that interstitial fiber spacing of 1 cm would allow for comprehensive treatment of the gland at this dose level of light.

Based on these results, fibers were placed at 1-cm apart, the dose of light was escalated to 150 J/cm, 150 mW/cm, and the acute necrosis within the prostate was again evaluated. Three dogs were treated with a combination of interstitial and transurethral light delivery. Immediately after motexafin lutetium administration, all dogs experienced facial and paw edema, two dogs became hypotensive, however this resolved well with saline boluses. Immediately after treatment, the prostate was noted to be dark and necrotic, and several weeks after PDT, histological analysis of the prostate demonstrated comprehensive treatment of the entire gland.

Subsequently, long-term (3 months) clinical and histological effects of the combined interstitial and transurethral light delivery approach were evaluated using a motexafin lutetium dose of 6 mg/kg. Four dogs were treated with 1-cm fiber spacing, 150 J/cm. Two dogs received a light fluence rate of 75 mW/cm and two dogs received a rate of 150 mW/cm. As before, immediately after treatment, the prostate gland appeared dark and dusky. All four dogs developed peritonitis and either died or were euthanized 3–21 days after PDT. Complete, diffuse necrosis of the prostate was observed, in several cases with complete destruction of the urethra. Importantly, this dose of PDT was associated with destruction of stroma and epithelium and therefore, a loss of selectivity. It was concluded that motexafin lutetium at 6 mg/kg, 150 J/cm, was intolerable. Furthermore, as the first group of beagles demonstrated that transurethral light delivery alone allowed urethral recovery at these dose levels, combined transurethral and interstitial light delivery may have contributed to excessive urethral damage.

In order to reduce toxicity levels, a decreased dose of PDT, with motexafin lutetium at 2 mg/kg, light of 732 nm, 100 J/cm at 150 mW/cm was evaluated. One dog was treated with transurethral light delivery alone, two dogs were treated with interstitial light delivery alone, and two dogs were treated with a combination of interstitial and transurethral light. All dogs were euthanized at 3 months. No acute toxicities were observed. All dogs had evidence of inflammation to the prostatic urethra, as followed by endoscopy. All urethral abnormalities resolved except in two dogs; one dog had received interstitial light delivery alone and had mild residual urethral abnormalities, the other dog had received combination transurethral and interstitial light delivery and developed a urethral stricture. No gross damage was observed in the surrounding normal tissues. Histopathologic analysis revealed necrosis surrounding fiber implantation sites. However, skip lesions with areas of prostate sparing were observed, emphasizing the need for careful needle spacing. These data demonstrate that it is technically feasible and safe to deliver light via an interstitial approach to the prostate.

### Light Dosimetry

Light deposition in tissues is a necessary component of PDT tissue destruction. Using spherical light detectors placed at fixed distances from the light source in our pre-clinical canine studies, significant heterogeneity in deposited light dose for any given prescribed laser output was found, which supports the need for in situ dosimetry system. We have shown that there is also significant heterogeneity of optical properties and light penetration depth in the human prostate [37,38]. Therefore, significant heterogeneity of light dose is likely to be present when treating prostate cancer patients with interstitial PDT. Given this heterogeneity, the measurement of actual light deposited is likely to be critical for the determination of tissue response and treatment toxicities in clinical trials of interstitial prostate PDT. Light measurements are required to determine the actual light dose deposited within the prostate gland, which includes both incident as

well as scattered light. The accurate measurement of light fluence allows for the deposition of a consistent light dose in the prostate.

### CLINICAL EXPERIENCE WITH PDT FOR RECURRENT PROSTATE CANCER

The pre-clinical experiments provided the data necessary to perform a Phase I trial of motexafin lutetium-mediated PDT in patients with locally recurrent prostate adenocarcinoma who have previously been treated with definitive radiotherapy. This protocol was approved by the Institutional Review Board and Cancer Center Clinical Trials and Scientific Monitoring Committee of the University of Pennsylvania, as well as the Cancer Therapy Evaluation Program of the National Cancer Institute. The primary endpoint of this ongoing trial is to determine the maximally tolerated dose and dose-limiting toxicities of PDT using 732-nm light and motexafin lutetium in patients with locally recurrent prostate adenocarcinoma who have failed previous definitive radiotherapy. Secondary endpoints are: (1) to measure motexafin lutetium levels in needle biopsies of the prostate pre- and post-PDT; (2) to use optical methods to measure motexafin lutetium fluorescence in situ in the prostate pre- and post-PDT and to correlate these results with the direct tissue measurements made in biopsies with HPLC and tissue fluorescence. Optical methods will also be used to measure the optical properties and the absorption spectrum of the prostate pre- and post-PDT; (3) to calculate the percent change in motexafin lutetium after treatment; (4) to measure clinical outcome from time of PDT salvage therapy; including clinical response, progression-free survival, time to complete response, time to biochemical relapse, time to local progression, time to distant failure, overall survival, and disease specific survival after motexafin lutetium-mediated PDT in patients with recurrent prostate cancer; (5) to use a multimodality optical instrument to determine in vivo tissue optical properties, photosensitizer concentration, tissue blood oxygenation, and blood flow before, during, and after PDT.

### Patient Information

Between October 2000 and January 2005, 17 patients have been enrolled in this Phase I trial. Each person gave informed consent and was given an evaluation that included an MRI of the prostate, bone scan, serum lab studies, PSA level, and a urological evaluation. The median age was 69 (range of 57–79 years). Patients included in this study had localized recurrent prostate adenocarcinoma. Nine patients had been previously treated with interstitial brachytherapy, and eight had been treated with external beam irradiation. At the time of recurrence, the median PSA was 7.4 ng/ml (range of >0.2–13.6 ng/ml) with Gleason scores of 6 in three patients, 7 in eight patients, 8 in two patients, 9 in three patients, and one patient whose biopsy specimen was too small to score. Patients with primary T3 or T4 tumors, a prostate gland volume > 50 cc, or PSA > 20 mg/ml were excluded from this study. One patient who was enrolled in this study was subsequently

excluded, prior to beginning treatment, based on extracapsular extension.

### Prostate PDT

Two weeks prior to treatment with PDT, a transrectal ultrasound was obtained for treatment planning. Ultrasound slices were scanned 0.5-cm apart, with the same scanner to be used for treatment. An integrated plexiglass template, with a 0.5-cm grid, projected the placement of light source insertion relative to the prostate gland. A urologist (SBM) drew the total volume of the prostate on each section of ultrasound image. A treatment plan was created, using Multimedia Medical System software, to guide placement of illumination and detector fibers, with the goal of comprehensively covering the entire prostate gland with light delivery. Cylindrical diffusing fibers of varying lengths were used as light sources, spaced 1-cm apart, using uniform J/cm in all fibers, with planned placement to cover the entire length of the prostate at a particular position.

Within 24 hours prior to light delivery, 0.5–2 mg/kg motexafin lutetium (dose escalation according to Table 1) was administered intravenously, over 5–10 minutes, as a sterile, pyrogen-free 2 mM (2.3 mg/ml) solution in 5% mannitol/water. While a 3-hour drug-light interval was demonstrated in pre-clinical studies to be safe, a conservative 24-hour drug-light interval was selected to ensure safety in the initial human PDT subjects. We used an

accelerated titration design in order to minimize the number of patients treated at these lower light doses.

Light delivery was performed in a surgical suite with precautions to prevent unplanned photosensitizer activation, including filtered OR lighting and covering the patient's exposed skin. The patient was placed under general anesthesia to minimize patient movement during the procedure. An endorectal ultrasound probe was introduced and the base of the prostate identified. A standard brachytherapy transperineal implant template was fixed to the operating table and the ultrasound probe. Using sonographic guidance, with the same equipment used to perform pre-treatment planning, and a perineal template matched to the treatment plan 0.5-cm grid, 17-gauge plastic brachytherapy catheters were placed into the prostate with trochars at 1-cm intervals throughout the prostate gland, following the treatment plan. After removal of the trochars, illumination and detector fibers were placed into the brachytherapy catheters. Isotropic detectors, composed of optical fibers with a spherical TiO<sub>2</sub> scattering tip [43], were placed with brachytherapy catheters and trochars, via the perineal template. Four isotropic light detectors were placed in the catheters for measurement of light fluence, one in each equal prostate quadrant, and one detector was placed in the urethra. The detectors were placed approximately 0.5 cm from the light emitting fibers and connected to photodiodes. A 12-channel light dosimetry system [44] was utilized, consisting of three

**TABLE 1. Dose Escalation of motexafin lutetium and Prostate Tissue Drug Dosimetry**

Patient	Motexafin lutetium prescribed (mg/kg)	Light fluence prescribed (J/cm <sup>2</sup> )	Drug-light interval (hours)	Pre-PDT motexafin lutetium level (ng/mg)	Post-PDT motexafin lutetium level (ng/mg)	Post/Pre-PDT ratio	
1	0.5	25	24	0.279	0.164	0.587	
2	0.5	25	24	0.341	0.222	0.651	
3	0.5	25	24	0.423	0.339	0.800	
4	1.0	25	24	0.767	0.400	0.522	
5	1.0	25	24	0.649	0.346	0.533	
6	1.0	25	24	0.522	0.934	1.791	
7	1.0	25	6	0.466	0.520	1.115	
8	2.0	25	6	3.028	1.937	0.640	
9	2.0	50	6	2.323	3.249	1.398	
10	2.0	100	6	4.645	2.476	0.533	Apex base
				4.948	2.947	0.596	
11	2.0	25	3	3.264	5.717	1.752	Apex base
				6.027	3.361	0.558	
12	2.0	50	3	3.589	4.171	1.162	Apex base
				3.508	3.778	1.077	
13	2.0	100	3	Inadequate sam- ple	7.783		
15	2.0	100	3	6.734	1.892	0.281	
17	2.0	100	3	7.828	7.457	0.953	
16	2.0	150	3	1.713	2.666	1.556	

Due to small sample size all four intra-prostate quadrant samples were combined for pre- and post-PDT drug quantification. In cases where sample sizes permitted, apical and base of prostate quadrants were analyzed separately. In one case (Patient 13), the pre-PDT sample size was inadequate for analysis.

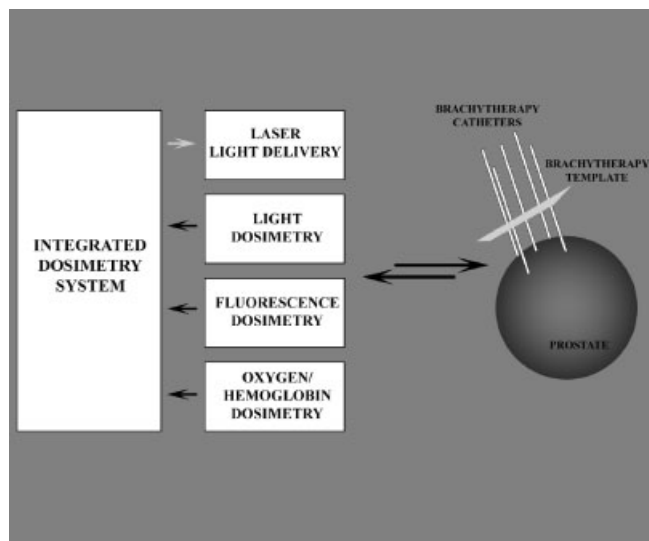


Fig. 1. Schematic of a real-time PDT delivery system. Diagram of a real-time PDT delivery system that utilizes information derived from light, photosensitizer, and oxygen/hemoglobin dosimetry, in order to deliver an optimized dose of light to the prostate gland. Here, translucent brachytherapy catheters are inserted into the gland using a brachytherapy template to guide placement. Cylindrical diffuser-tipped fibers transmit laser light to illuminate the gland, while detectors measure light fluence, photosensitizer fluorescence, oxygen and hemoglobin levels at point of care. Future studies will be directed at utilizing this data to dynamically control light delivery, compensating for real-time measurements of heterogeneity within the gland.

major components: (1) isotropic detectors, photodiodes, and pre-amplifiers, (2) an analog-to-digital converter, and (3) computer control software. This system monitored real-time fluence rates and integrated fluence measurements (Fig. 1). The isotropic light detectors allowed measurement of both incident and scattered light. Optical properties and absorption spectra of each of the four quadrants of the prostate tissue (scattering and absorption coefficients) were determined pre- and post-light delivery; fluorescence measurements were made through the detector in each quadrant using a single optical fiber acting as both a light source and detector. The fiber emitted 460-nm light and collected fluorescence light above 700 nm at right angles from the optical axis of a beveled fiber tip. These values were used to determine light delivery time for each quadrant, as well as to determine oxygenation and hemoglobin content in the prostate. One course of 732-nm light was administered (Laser Model 730, 15-W diode, Diomed, Ltd., Cambridge, UK) at a fluence rate of 150 mW/cm, with light fluence from 25 to 200 J/cm<sup>2</sup>, and drug-light interval of 3–24 hours, again following a careful dose escalation plan (Table 1). The light source and detectors were controlled using two-step motors driven by control software developed to integrate the movement of the step motor with data acquisition of the light detectors. Each prostate quadrant was treated sequentially until the entire

prostate volume was comprehensively treated. The light fluence rate distributions were measured along the length of each catheter.

Pre- and post-light administration, two tissue samples were obtained by transrectal ultrasound guided transperineal biopsy from each of four locations within the prostate, for motexafin lutetium tissue level determination. Concentrations of motexafin lutetium, extracted from homogenized biopsy tissue from each quadrant, were determined by fluorescence measurements against standards of known drug concentrations.

Following PDT, patients had a Foley catheter inserted and all patients were observed overnight as inpatients. The following day the catheter was removed—if the patient was unable to void, the catheter was replaced for as long as clinically indicated. In most cases the catheter was removed the day after PDT. Patients were discharged with additional instructions to avoid direct sun exposure for 2 days following drug administration. Patients were seen 2 weeks after discharge to assess and treat any PDT-related toxicities, and then followed routinely 1, 2, and 3 months after discharge, then every 3 months for 2 years. Only mild, Grade I, urinary PDT-related toxicities have been observed, with four patients experiencing temporary urinary retention after the procedure. The most common urinary toxicity to date has been mild urgency which typically lasts several days after the procedure. There were no rectal or gastrointestinal toxicities reported. Four patients experienced photosensitivity—typically a tingling sensation associated with sun-exposed areas of skin.

PSA levels were followed at each patient visit. In patients at the lowest PDT dose levels, there was no apparent impact on PSA levels. However, at higher dose levels, PSA levels transiently increased immediately following treatment (Fig. 2). This was typically followed by a rapid return of elevated PSA to pre-PDT levels within 1–2 months, followed by a maintenance phase of stable PSA measurements or very gradually increasing PSA values. To date, at all PDT dose levels, patients experienced biochemical failure within 2 years of PDT.

### Optical Properties

Optical properties have been measured in 14 of the patients treated [37,38,45]. Light delivery to one quadrant of the prostate was found to result in delivery of a measurable fluence to other quadrants as well. The dominant absorbers in the wavelength range of measurements are oxygenated and deoxygenated hemoglobin, motexafin lutetium, and water. At 732 nm, the absorption coefficient ( $\mu_a$ ) varied from 0.07 to 1.62 per cm (mean  $0.37 \pm 0.24$  per cm) and the reduced scattering coefficient ( $\mu_s$ ) varied from 1.1 to 44 per cm (mean  $14 \pm 11$  per cm).  $\mu_{\text{eff}}$  varied between 0.91 and 6.7 per cm (mean  $2.9 \pm 0.7$  per cm), corresponding to an optical penetration depth of 0.1–1.1 cm (mean  $0.4 \pm 0.1$  cm). The maximum variation of optical properties within the same patient was larger than the standard variation of the mean in all patients. The variations within a single patient were as large as 300% for  $\mu_a$  and 1,000% for  $\mu_s$ . Therefore, the optical penetration

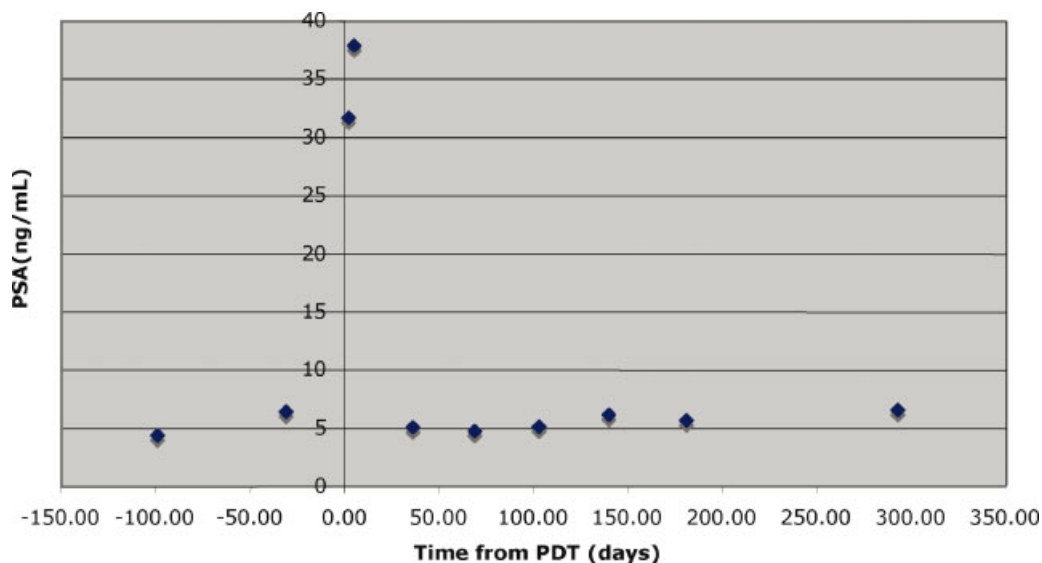


Fig. 2. PSA response to photodynamic therapy (PDT) in these studies. This represents a typical PDT response for a patient receiving 2 mg/kg motexafin lutetium, 3 hours before light administration at 100 J/cm<sup>2</sup>. There is a transient elevation in PSA levels immediately after PDT, followed by a return to approximately pre-PDT levels. This particular patient was taken off-study at 295 days post-PDT due to biochemical progression of disease.

depth varied by 290% within a single patient's prostate. Clearly, there is a significant heterogeneity of optical properties through the prostate gland, at this wavelength which can contribute to variable fluence rates at any given location. Modeling systems for treatment planning should take this variation into account and, in theory, should correct for it in real-time.

#### Photosensitizer Biodistribution

Motexafin lutetium levels in prostate biopsies were measured by fluorescence spectroscopy. In general, drug levels increased with increasing injected drug dose or decreasing drug/light interval (Table 1). Again, variability was apparent between patients at the same drug dose level, and between biopsy locations in the same prostate. There was an overall decrease in post-PDT drug levels, perhaps due to treatment-related photobleaching. When comparing *in situ* optical measurements of motexafin lutetium with direct tissue spectroscopy measurements, a linear relationship was noted between the absorption coefficient and the drug concentration in the prostate [38].

Another interesting feature is that motexafin lutetium levels varied by as much as fivefold within a single prostate. The degree of intra-prostate variation may be, at least in part, as a result of the heterogeneity of tissue sampling, which does not distinguish between normal prostate and foci of cancer. There is also possibly a vascular component, with variations in vascular density or perfusion that may limit the delivery of blood and photosensitizer to regions of the gland.

#### Tumor Oxygenation and Blood Flow

Tissue oxygen concentrations during PDT are influenced by blood flow, blood oxygenation, and photobleaching. The

destruction of tumor vasculature by PDT leads to oxygen and nutrient deprivation of tumor cells. However, vascular occlusion during PDT may also lead to tumor hypoxia during treatment, resulting in decreased efficacy [46]. In a murine fibrosarcoma explant model, both blood flow and oxygen saturation have demonstrated prognostic significance for PDT [47,48]. Monitoring of blood flow and oxygenation status during PDT is therefore of interest in our clinical trial. Our group has developed a near-infrared diffuse optical instrument combining Diffuse Reflectance Spectroscopy (DRS), for the measurement of blood flow oxygenation, with Diffuse Correlation Spectroscopy, for measurement of tissue blood flow [48–53]. We used this instrument to measure hemodynamic responses to PDT in three of our Phase I patients [54]. A fiber-optic probe containing a source and detector was placed into a brachytherapy catheter in the center of each quadrant of the prostate gland, and remained in place throughout the treatment. All three patients demonstrated similar blood flow responses. Average post-PDT blood flow and total hemoglobin both decreased, and blood oxygen saturation remained relatively constant. The decrease in blood flow and total hemoglobin concentration indicates a perfusion decrease, likely due to vascular destruction mediated by PDT. Intriguingly, the relatively unchanged hemoglobin oxygen saturation suggests that either PDT oxygen utilization was minimal or that tissue oxygen consumption, due to PDT-mediated cell death, had decreased. Further study will be done to relate hemodynamic responses to clinical outcome.

#### CONCLUSIONS

Interstitial PDT holds an enormous potential for treating locally confined prostate cancer. Especially attractive is the

potential to treat repeatedly with only mild additional morbidities. Our initial clinical studies with motexafin lutetium demonstrate the potential to safely deliver PDT to the prostate gland.

Overall, the results from the pre-clinical and the ongoing clinical Phase I study presented herein have been encouraging. While the human clinical trial is ongoing, it is clear that photosensitizer and light are successfully delivered, with only mild and transient toxicities. The transient rise in PSA, immediately following PDT, suggests that levels of photosensitizer and light are at sufficient doses to induce cell death within the prostate. It remains to be seen, however, whether comprehensive treatment of the gland is clinically achievable and, of course, whether long-term biochemical (PSA) responses are possible.

A significant finding of these studies is the intra-patient and inter-patient heterogeneity in light, photosensitizer, oxygen, and tissue optical properties within the prostate. This heterogeneity is not surprising and has been observed in other human studies of PDT that we have performed [37,38,55,56]. The heterogeneity underscores the need for continued detailed study of the parameters that affect PDT response. Ideally, PDT will be administered via a real-time system (Fig. 1) that accounts for variations in intra-prostate conditions and optimizes light delivery to specific areas of the gland.

Furthermore, there are significant concerns that needle placement in any one individual may not be optimal and may lead to "skip" areas within the prostate gland. Given the set-up error associated with any interstitial approach, it may be necessary to deliver more than one application of PDT to the gland. Further studies will be needed to address the conditions necessary to optimally treat the entire prostate volume.

## REFERENCES

- Dougherty TJ. An update on photodynamic therapy applications. *J Clin Laser Med Surg* 2002;20(1):3-7.
- Dougherty TJ, Gomer CJ, Henderson BW, Jori G, Kessel D, Korbek M, Moan J, Peng Q. Photodynamic therapy. *J Natl Cancer Inst* 1998;90(12):889-905.
- Moan J, Berg K. The photodegradation of porphyrins in cells can be used to estimate the lifetime of singlet oxygen. *Photochem Photobiol* 1991;53(4):549-553.
- Barr H, Tralau CJ, Boulos PB, MacRobert AJ, Tilly R, Bown SG. The contrasting mechanisms of colonic collagen damage between photodynamic therapy and thermal injury. *Photochem Photobiol* 1987;46(5):795-800.
- Fielding DI, Buonaccorsi G, Cowley G, Johnston AM, Hughes /SNM> G, Hetzel MR, Bown SG. Interstitial laser photocoagulation and interstitial photodynamic therapy of normal lung parenchyma in the pig. *Lasers Med Sci* 2001;16(1):26-33.
- Hsi RA, Rosenthal DI, Glatstein E. Photodynamic therapy in the treatment of cancer: Current state of the art. *Drugs* 1999;57(5):725-734.
- Gomer CJ, Smith DM. Photoinactivation of Chinese hamster cells by hematoporphyrin derivative and red light. *Photochem Photobiol* 1980;32(3):341-348.
- Miller DC, Hafez KS, Stewart A, Montie JE, Wei JT. Prostate carcinoma presentation, diagnosis, and staging: An update from the National Cancer Data Base. *Cancer* 2003;98(6):1169-1178.
- Cooperberg MR, Lubeck DP, Meng MV, Mehta SS, Carroll PR. The changing face of low-risk prostate cancer: Trends in clinical presentation and primary management. *J Clin Oncol* 2004;22(11):2141-2149.
- Jemal A, Murray T, Ward E, Samuels A, Tiwari RC, Ghafoor A, Feuer EJ, Thun MJ. Cancer statistics, 2005. *CA Cancer J Clin* 2005;55(1):10-30.
- Benoit RM, Naslund MJ, Cohen JK. Complications after radical retropubic prostatectomy in the medicare population. *Urology* 2000;56(1):116-120.
- Stanford JL, Feng Z, Hamilton AS, Gilliland FD, Stephenson RA, Eley JW, Albertsen PC, Harlan LC, Potosky AL. Urinary and sexual function after radical prostatectomy for clinically localized prostate cancer: The Prostate Cancer Outcomes Study. *Jama* 2000;283(3):354-360.
- Tefilli MV, Gheiler EL, Tiguert R, Banerjee M, Forman J, Pontes JE, Wood DP, Jr. Salvage surgery or salvage radiotherapy for locally recurrent prostate cancer. *Urology* 1998;52(2):224-229.
- Pisters LL, von Eschenbach AC, Scott SM, Swanson DA, Dinney CP, Pettaway CA, Babaian RJ. The efficacy and complications of salvage cryotherapy of the prostate. *J Urol* 1997;157(3):921-925.
- Grado GL, Collins JM, Kriegshauser JS, Balch CS, Grado MM, Swanson GP, Larson TR, Wilkes MM, Navickis RJ. Salvage brachytherapy for localized prostate cancer after radiotherapy failure. *Urology* 1999;53(1):2-10.
- Perrotte P, Litwin MS, McGuire EJ, Scott SM, von Eschenbach AC, Pisters LL. Quality of life after salvage cryotherapy: The impact of treatment parameters. *J Urol* 1999;162(2):398-402.
- Vaidya A, Soloway MS. Salvage radical prostatectomy for radiorecurrent prostate cancer: Morbidity revisited. *J Urol* 2000;164(6):1998-2001.
- Djavan B, Susani M, Bursa B, Basharkhah A, Simak R, Marberger M. Predictability and significance of multifocal prostate cancer in the radical prostatectomy specimen. *Tech Urol* 1999;5(3):139-142.
- Lee F, Bahn DK, Siders DB, Greene C. The role of TRUS-guided biopsies for determination of internal and external spread of prostate cancer. *Semin Urol Oncol* 1998;16(3):129-136.
- Chang SC, Buonaccorsi G, MacRobert A, Bown SG. Interstitial and transurethral photodynamic therapy of the canine prostate using meso-tetra-(m-hydroxyphenyl) chlorin. *Int J Cancer* 1996;67(4):555-562.
- Chang SC, Buonaccorsi GA, MacRobert AJ, Bown SG. Interstitial photodynamic therapy in the canine prostate with disulfonated aluminum phthalocyanine and 5-aminolevulinic acid-induced protoporphyrin IX. *Prostate* 1997;32(2):89-98.
- Chang SC, Chern IF, Hsu YH. Biological responses of dog prostate and adjacent structures after meso-tetra-(m-hydroxyphenyl) chlorin and aluminum disulfonated phthalocyanine based photodynamic therapy. *Proc Natl Sci Council Repub China B* 1999;23(4):158-166.
- Chen Q, Huang Z, Luck D, Beckers J, Brun PH, Wilson BC, Scherz A, Salomon Y, Hetzel FW. Preclinical studies in normal canine prostate of a novel palladium-bacteriopheophorbide (WST09) photosensitizer for photodynamic therapy of prostate cancers. *Photochem Photobiol* 2002;76(4):438-445.
- Hsi RA, Kapatkin A, Strandberg J, Zhu T, Vulcan T, Solonenko M, Rodriguez C, Chang J, Saunders M, Mason N, Hahn S. Photodynamic therapy in the canine prostate using motexafin lutetium. *Clin Cancer Res* 2001;7(3):651-660.
- Lee LK, Whitehurst C, Chen Q, Pantelides ML, Hetzel FW, Moore JV. Interstitial photodynamic therapy in the canine prostate. *Br J Urol* 1997;80(6):898-902.
- Selman SH, Albrecht D, Keck RW, Brennan P, Kondo S. Studies of tin ethyl etiopurpurin photodynamic therapy of the canine prostate. *J Urol* 2001;165(5):1795-1801.
- Selman SH, Keck RW. The effect of transurethral light on the canine prostate after sensitization with the photosensitizer tin (II) etiopurpurin dichloride: A pilot study. *J Urol* 1994;152(6 Pt 1):2129-2132.

28. Selman SH, Keck RW, Hampton JA. Transperineal photodynamic ablation of the canine prostate. *J Urol* 1996;156(1):258–260.
29. Zaak D, Sroka R, Stocker S, Bise K, Lein M, Hoppner M, Frimberger D, Schneede P, Reich O, Kriegmair M, Knuchel R, Baumgartner R, Hofstetter A. Photodynamic therapy of prostate cancer by means of 5-aminolevulinic acid-induced protoporphyrin IX—In vivo experiments on the dunning rat tumor model. *Urol Int* 2004;72(3):196–202.
30. Chen Q, Hetzel FW. Laser dosimetry studies in the prostate. *J Clin Laser Med Surg* 1998;16(1):9–12.
31. Chen Q, Wilson BC, Shetty SD, Patterson MS, Cerny JC, Hetzel FW. Changes in in vivo optical properties and light distributions in normal canine prostate during photodynamic therapy. *Radiat Res* 1997;147(1):86–91.
32. Lee LK, Whitehurst C, Pantelides ML, Moore JV. In situ comparison of 665 nm and 633 nm wavelength light penetration in the human prostate gland. *Photochem Photobiol* 1995;62(5):882–886.
33. Arnfield MR, Tulip J, Chetner M, McPhee MS. Optical dosimetry for interstitial photodynamic therapy. *Med Phys* 1989;16(4):602–608.
34. Fenning MC, Brown DQ, Chapman JD. Photodosimetry of interstitial light delivery to solid tumors. *Med Phys* 1994;21(7):1149–1156.
35. Busch TM, Wileyto EP, Emanuele MJ, Del Piero F, Marconato L, Glatstein E, Koch CJ. Photodynamic therapy creates fluence rate-dependent gradients in the intratumoral spatial distribution of oxygen. *Cancer Res* 2002;62(24):7273–7279.
36. Solonenko M, Cheung R, Busch TM, Kachur A, Griffin GM, Vulcan T, Zhu TC, Wang HW, Hahn SM, Yodh AG. In vivo reflectance measurement of optical properties, blood oxygenation and motexafin lutetium uptake in canine large bowels, kidneys and prostates. *Phys Med Biol* 2002;47(6):857–873.
37. Zhu TC, Dimofte A, Finlay JC, Stripp D, Busch T, Miles J, Whittington R, Malkowicz SB, Tochner Z, Glatstein E, Hahn / SNM> SM. Optical properties of human prostate at 732 nm measured in mediated photodynamic therapy. *Photochem Photobiol* 2005;81(1):96–105.
38. Zhu TC, Finlay JC, Hahn SM. Determination of the distribution of light, optical properties, drug concentration, and tissue oxygenation in-vivo in human prostate during motexafin lutetium-mediated photodynamic therapy. *J Photochem Photobiol B* 2005;79(3):231–241.
39. Sessler JL, Miller RA. Texaphyrins: New drugs with diverse clinical applications in radiation and photodynamic therapy. *Biochem Pharmacol* 2000;59(7):733–739.
40. Young SW, Woodburn KW, Wright M, Mody TD, Fan Q, Sessler JL, Dow WC, Miller RA. Lutetium texaphyrin (PCI-0123): A near-infrared, water-soluble photosensitizer. *Photochem Photobiol* 1996;63(6):892–897.
41. Mody TD, Fu L, Sessler JL. Texaphyrins: Synthesis and development of a novel class of therapeutic agents. In: Karlin KD, editor. *Progress in inorganic chemistry*. Chichester: John Wiley & Sons, Ltd. 2001: pp 551–598.
42. Woodburn KW, Fan Q, Kessel D, Luo Y, Young SW. Photodynamic therapy of B16F10 murine melanoma with lutetium texaphyrin. *J Invest Dermatol* 1998;110(5):746–751.
43. Marijnissen JP, Star WM. Calibration of isotropic light dosimetry probes based on scattering bulbs in clear media. *Phys Med Biol* 1996;41(7):1191–1208.
44. Baas P, Murrer L, Zoetmulder FA, Stewart FA, Ris HB, van Zandwijk N, Peterse JL, Rutgers EJ. Photodynamic therapy as adjuvant therapy in surgically treated pleural malignancies. *Br J Cancer* 1997;76(6):819–826.
45. Zhu TC, Hahn SM, Kapatkin AS, Dimofte A, Rodriguez CE, Vulcan TG, Glatstein E, Hsi RA. In vivo optical properties of normal canine prostate at 732 nm using motexafin lutetium-mediated photodynamic therapy. *Photochem Photobiol* 2003;77(1):81–88.
46. Busch TM, Hahn SM, Evans SM, Koch CJ. Depletion of tumor oxygenation during photodynamic therapy: Detection by the hypoxia marker EF3 [2-(2-nitroimidazol-1[H]-yl)-N-(3,3,3-trifluoropropyl)acetamide]. *Cancer Res* 2000;60(10):2636–2642.
47. Wang HW, Putt ME, Emanuele MJ, Shin DB, Glatstein E, Yodh AG, Busch TM. Treatment-induced changes in tumor oxygenation predict photodynamic therapy outcome. *Cancer Res* 2004;64(20):7553–7561.
48. Yu G, Durduran T, Zhou C, Wang HW, Putt ME, Saunders HM, Sehgal CM, Glatstein E, Yodh AG, Busch TM. Noninvasive monitoring of murine tumor blood flow during and after photodynamic therapy provides early assessment of therapeutic efficacy. *Clin Cancer Res* 2005;11(9):3543–3552.
49. Cheung C, Culver JP, Takahashi K, Greenberg JH, Yodh AG. In vivo cerebrovascular measurement combining diffuse near-infrared absorption and correlation spectroscopies. *Phys Med Biol* 2001;46(8):2053–2065.
50. Culver JP, Durduran T, Cheung C, Furuya D, Greenberg JH, Yodh AG. Diffuse optical measurement of hemoglobin and cerebral blood flow in rat brain during hypercapnia, hypoxia and cardiac arrest. *Adv Exp Med Biol* 2003;510:293–297.
51. Durduran T, Yu G, Burnett MG, Detre JA, Greenberg JH, Wang J, Zhou C, Yodh AG. Diffuse optical measurement of blood flow, blood oxygenation, and metabolism in a human brain during sensorimotor cortex activation. *Opt Lett* 2004;29(15):1766–1768.
52. Menon C, Polin GM, Prabakaran I, Hsi A, Cheung C, Culver JP, Pingpank JF, Sehgal CS, Yodh AG, Buerk DG, Fraker DL. An integrated approach to measuring tumor oxygen status using human melanoma xenografts as a model. *Cancer Res* 2003;63(21):7232–7240.
53. Yu G, Durduran T, Lech G, Zhou C, Chance B, Mohler ER, III, Yodh AG. Time-dependent blood flow and oxygenation in human skeletal muscles measured with noninvasive near-infrared diffuse optical spectroscopies. *J Biomed Opt* 2005;10(2):024027.
54. Yu G, Durduran T, Zhou C, Zhu TC, Finlay JC, Busch TM, Malkowicz SB, Hahn SM, Yodh AG. Real-time insitu monitoring of human prostate photodynamic therapy with diffuse light. *Photochem Photobiol* 2006: Oct 1: [E Pub].
55. Friedberg JS, Mick R, Stevenson JP, Zhu T, Busch TM, Shin D, Smith D, Culligan M, Dimofte A, Glatstein E, Hahn SM. Phase II trial of pleural photodynamic therapy and surgery for patients with non-small-cell lung cancer with pleural spread. *J Clin Oncol* 2004;22(11):2192–2201.
56. Vulcan TG, Zhu TC, Rodriguez CE, Hsi A, Fraker DL, Baas P, Murrer LH, Star WM, Glatstein E, Yodh AG, Hahn SM. Comparison between isotropic and nonisotropic dosimetry systems during intraperitoneal photodynamic therapy. *Lasers Surg Med* 2000;26(3):292–301.