

Photodynamic Therapy with Motexafin Lutetium for Rectal Cancer: A Preclinical Model in the Dog

H.M. Ross,^{*,1} J.A. Smelstoys,[§] G.J. Davis,^{||} A.S. Kapatkin,[§] F. Del Piero,[¶] E. Reineke,[§] H. Wang,^{¶||} T.C. Zhu,[¶]
T.M. Busch,[†] A.G. Yodh,^{†‡} and S.M. Hahn[†]

^{*}Department of Surgery, Division of Colon and Rectal Surgery, [†]Department of Radiation Oncology & Division of Hematology Oncology,
[‡]Department of Physics & Astronomy, [§]Department of Clinical Studies, [¶]Department of Pathobiology, ^{||}Department of Clinical Studies,
School of Veterinary, University of Pennsylvania, School of Medicine, Philadelphia, Pennsylvania

Submitted for publication January 2, 2006

Purpose. Local recurrence of rectal cancer remains a significant clinical problem despite multi-modality therapy. Photodynamic Therapy (PDT) is a cancer treatment which generates tumor kill through the production of singlet oxygen in cells containing a photosensitizing drug when exposed to laser light of a specific wavelength. PDT is a promising modality for prevention of local recurrence of rectal cancer for several reasons: tumor cells may selectively retain photosensitizer at higher levels than normal tissues, the pelvis after mesorectal excision is a fixed space amenable to intraoperative illumination, and PDT can generate toxicity in tissues up to 1 cm thick. This study evaluated the safety, tissue penetration of 730 nm light, normal tissue toxicity and surgical outcome in a dog model of rectal resection after motexafin lutetium-mediated photodynamic therapy.

Methods. Ten mixed breed dogs were used. Eight dogs underwent proctectomy and low rectal end to end stapled anastomosis. Six dogs received the photosensitizing agent motexafin lutetium (MLu, Pharmacyclics, Inc., Sunnyvale, CA) of 2 mg/kg preoperatively and underwent subsequent pelvic illumination of the transected distal rectum of 730 nm light with light doses ranging from 0.5 J/cm² to 10 J/cm² three hours after drug delivery. Two dogs received light, but no drug, and underwent proctectomy and low-rectal stapled anastomosis. Two dogs underwent midline laparotomy and pelvic illumination. Light penetration in tissues was determined for small bowel, rectum, pelvic sidewall, and

skin. Clinical outcomes were recorded. Animals were sacrificed at 14 days and histological evaluation was performed.

Results. All dogs recovered uneventfully. No dog suffered an anastomotic leak. Severe tissue toxicity was not seen. Histological findings at necropsy revealed mild enteritis in all dogs. The excitation light penetration depths were 0.46 ± 0.18, 0.46 ± 0.15, and 0.69 ± 0.39 cm, respectively, for rectum, small bowel, and peritoneum in dogs that had received MLu. For control dogs without photosensitizer MLu, the optical penetration depths were longer: 0.92 ± 0.63, 0.67 ± 0.10, and 1.1 ± 0.80 cm for rectum, small bowel, and peritoneum, respectively.

Conclusion. Low rectal stapled anastomosis is safe when performed with MLu-mediated pelvic PDT in a dog model. Significant tissue penetration of 730 nm light into the rectum and pelvic sidewall was revealed without generation of significant toxicity or histological sequelae. Penetration depths of 730 nm light in pelvic tissue suggest that microscopic residual disease of less than 5 mm are likely to be treated adequately with MLu-mediated PDT. This approach merits further investigation as an adjuvant to total mesorectal excision and chemoradiation for rectal cancer. © 2006 Elsevier Inc. All rights reserved.

Key Words: photodynamic therapy; rectal cancer; surgery; adjuvant therapy; recurrent rectal cancer; experimental surgery.

INTRODUCTION

Current optimal therapy of rectal cancer involves chemoradiotherapy and proctectomy. Local recurrence after surgical resection remains a significant clinical problem, even with early stage lesions [1–3]. Recur-

¹ To whom correspondence and reprint requests should be addressed at Department of Surgery, University of Pennsylvania, School of Medicine, 3400 Spruce Street, Philadelphia, PA 19096. E-mail: howard.ross@uphs.upenn.edu.

rence may occur as a result of tumor cells that have spread to the mesorectum before excision or from secondary tumor cells spilled during surgical resection. Photodynamic therapy (PDT) is an emerging cancer treatment modality that generates tumor cell kill through the intracellular production of singlet oxygen [4]. Photosensitizing drugs used for photodynamic therapy may be selectively retained in tumor cells in higher concentrations than in the cells of non-malignant tissues. When light of specific wavelength illuminates tissues containing photosensitizer, singlet oxygen is produced and leads to cytotoxicity. Currently PDT is used experimentally and clinically for peritoneal carcinomatosis, non-small cell lung cancer, cancers and premalignant conditions of the upper aerodigestive tract, and prostate cancer [5–9].

Photodynamic therapy may be uniquely suited to prevent local recurrence in the pelvis after the excision of a rectal cancer. The pelvis after mesorectal excision is a fixed space amenable to illumination. It is likely that PDT can be applied even after radiation therapy without causing additional toxicity [10]. Peritoneal PDT is known to be tolerated in patients with peritoneal carcinomatosis [11]. The ability of light to penetrate tissues to a depth of several millimeters allows residual disease located on or just below surfaces to be treated. As local recurrence can be assumed to be because of either the direct spread of tumor cells into tissues surrounding the primary tumor or to tumor cells shed during operative resection, a local modality with capability to superficially treat pelvic structures may be efficacious.

Photofrin was the first FDA-approved photosensitizer. Photofrin is known to produce tumor kill but has a number of drawbacks limiting clinical utility. Photofrin generates prolonged sun sensitivity in patients post-injection, ranging from 4–6 weeks. Photofrin is activated by 630 nm laser light, a wavelength associated with limited penetration into tissues. Hemoglobin will absorb light in this region of the spectrum, causing interference where there is bleeding. The second generation photosensitizer motexafin lutetium (MLu) has several characteristics which may make it better suited to clinical cancer treatment. It has been reported that MLu has excellent preferential uptake in tumor cells compared with normal tissues [12–14]. Photosensitivity is limited to 24 to 48 h. MLu is activated by 730 nm light that penetrates tissues more deeply than 630 nm light and there is less interference of light penetration from hemoglobin.

Anastomotic leaks are a concern after low anterior resection and remains in the 6% range even without adjuvant therapy. An ideal adjuvant intra-operative therapy should therefore, not significantly increase this risk. We evaluated the safety of rectal PDT in a model of low anterior resection in the dog, because we

envision that PDT for rectal cancer will require illumination of the top of transected distal rectum before anastomosis with the proximal left colon. Tissue penetration of excitation light, induced tissue toxicity and surgical outcome were also explored in this study.

MATERIALS AND METHODS

Motexafin Lutetium

MLu was supplied by Pharmacyclics, Inc. (Sunnyvale, CA) as an aqueous solution 2 mg/ml. The compound was stored in a refrigerator and protected from light. The solution was drawn into a syringe and injected undiluted into the cephalic vein of the dogs over a period of 5 to 10 min via a 20 gauge intravenous catheter. The volume administered to each animal was dependent upon the total dose to be delivered.

Experimental Animals

Ten mixed breed dogs, all approximately 1.5 years of age and weighing from 14 to 20 kg were used in this study. The animals were housed in indoor runs and fed Purina lab canine chow and water *ad libitum*. All animals were vaccinated, treated for intestinal parasites and quarantined for 2 weeks before starting the study. Each animal had a complete blood count and serum chemistry drawn before treatment. Animals were cared for under the supervision of veterinarians from the University Of Pennsylvania School Of Veterinary Medicine. The University of Pennsylvania Institutional Animal Care and Use Committee approved this experimental protocol.

Experimental Design

Eight dogs underwent proctectomy and low rectal stapled anastomosis. Six of these dogs received MLu and 730 nm light. Two dogs received a light dose of 0.5 J/cm², two received a light dose of 2 J/cm² and two 10 J/cm². Two dogs served as light-only controls, undergoing proctectomy and low rectal stapled anastomosis receiving 730 nm light at 10 J/cm², but not receiving MLu. Two dogs received light at 10 J/cm² but neither MLu nor rectal resection. The details of treatment are shown in Table 1.

Surgical Procedure

Dogs were not permitted to eat for 12 h before surgery. They were pre-medicated with 0.05 mg/kg acepromazine maleate and 0.5 mg morphine by IM injection given 20 min before induction of general anesthesia. The dogs were anesthetized with 10 mg/kg thiopental sodium IV and intubated with an endotracheal tube. General anesthesia was maintained with an inhaled mixture of oxygen and isoflurane 1 to 3%. During surgery, the dogs received a constant IV infusion of Normosol-R at a rate of 20 ml/kg/h. Cefazolin sodium 20 mg/kg was administered i.v. every 2 h during the surgical procedure. While under anesthesia, ECG tracings, indirect blood pressure, and oxygen saturation were monitored continuously. A heating pad was used to maintain body temperature during the surgical procedure.

After the induction of anesthesia, the animals were placed into left lateral recumbence for epidural analgesia purposes. Hair was clipped from dorsum at the level of L4 to the tail base with a number 40 clipper blade and prepared with a dilute chlorhexiderm scrub solution. 0.1 mg/kg Morphine and 0.1 mg/kg Buprinorphine was administered into the epidural space via a 22 gauge 1.5 inch spinal needle. The animals were then placed in dorsal recumbence. Hair was clipped from the ventral abdomen with a number 40 clipper blade and prepared with a dilute chlorhexiderm scrub solution.

The surgical field was four-quarter draped, and a ventral midline incision was made from the xyphoid to the pubis. The abdominal

TABLE 1
Acute and Delayed Clinical Effects after Photodynamic Therapy

Dog number	Drug dose	PDT level	Bowel resection	Acute clinical effects	Late clinical effects
1	None	10 J/cm ²	Yes	Mild abdominal distention	None
2	2 mg/kg	10 J/cm ²	Yes	Loose stool-4 days	None
3	2 mg/kg	2 J/cm ²	Yes	None	None
4	2 mg/kg	0.5 J/cm ²	Yes	Decreased appetite-3 days	None
5	None	10 J/cm ²	No	None	None
6	None	10 J/cm ²	Yes	None	None
7	2 mg/k	10 J/cm ²	Yes	None	None
8	None	10 J/cm ²	No	None	None
9	2 mg/kg	2 J/cm ²	Yes	Bloody stool-1 day	None
10	2 mg/kg	0.5 J/cm ²	Yes	None	None

organs were examined for abnormalities. In animals undergoing rectal resection and anastomosis, the proximal rectum was divided with a GIA 60 stapler (United States Surgical Corp., Norwalk, CT). The cranial rectal (superior hemorrhoidal) artery, a branch of the caudal mesenteric (inferior mesenteric) artery, was double ligated with 3-0 chromic gut and transected. This was performed to assure that the blood supply to the anastomosis site would be solely from the caudal rectal artery (analogous to the inferior hemorrhoidal artery in humans). The distal rectum was divided using a TA-30 stapling device (United States Surgical Corp.). Optical properties of the tissues were measured. The 730 nm light was then delivered as described above. Optical properties were measured again after treatment with light. The proximal staple line was excised, the anvil of the 28 mm EEA stapler placed in the proximal colon, and appropriately secured with a purse string suture. The EEA stapling device was inserted per rectum and used to facilitate an end to end stapled rectal anastomosis. Biopsies collected before light exposure of the liver, skin, and rectum were frozen on dry ice, transferred to a -80°C freezer and subsequently analyzed for MLu drug levels. The abdomen was irrigated with sterile saline and then closed in three layers using polydioxanone sutures for the abdominal wall and subcutaneous tissues and monofilament nylon for the skin. The dogs were monitored closely until they recovered from anesthesia.

Post-operatively, dogs were monitored for signs of pain, distress, abdominal discomfort, fever, diarrhea, melena, and hematochezia by a veterinarian. They were examined twice daily for the first 5 days post-operatively and once daily after that. Dogs were monitored for 14 days post-surgically and were humanely euthanized using 190 mg/kg pentobarbital sodium by i.v. injection. All dogs underwent a full necropsy to evaluate presence of PDT and laser light-related tissue damage. Samples were taken of skin, liver, lung, heart, small bowel, kidney, bladder, pelvic sidewall, stomach, lymph node, and rectal resection site.

Light Delivery and Measurement

MLu was administered intravenously over 20 min, 3 h before planned light delivery in 6 of 10 dogs. Dogs underwent a midline abdominal incision with exposure of the entire abdominal contents. Room lights were not dimmed or filtered during the surgical procedure. Light was not used directly over the surgical table during procedures on animals that received the photosensitizer.

After opening the abdominal cavity, optical properties of the skin, liver, small bowel, pelvis, and rectum were measured. Spherical light detectors were placed within the abdomen for monitoring of light fluence rate and total light dose. The detectors were placed in sterile intravenous tubing and filled with saline to match the refractive index of surrounding media before being sutured in place in the posterior pelvis and to the top of the rectum. A 12-channel light dosimetry system developed at University of Pennsylvania was used for real

time light dosimetry. Isotropic detectors with 1-mm scattering bulbs from Rare Earth Medical (now CardioFocus, Norton, MA) were used. The detectors have an isotropy of better than $\pm 30\%$ from any direction except for angles within 30 degrees of the optical fiber attachment point. Each detector fiber was connected to a photodiode via an SMA connector. In all dogs, delivery of the prescribed light fluence to each site within the abdomen was confirmed via this light dosimetry system. *In vivo* reflectance measurements of tissue optical properties and MLu uptake was performed by methods previously described by our group [15, 16]. In brief, a broadband reflectance spectroscopy system was used to measure tissue optical properties, including absorption (μ_a) and reduced scattering coefficients (μ_s'), in the spectral range 600 to 800 nm. A hand-held surface contact fiber-optic probe, to deliver white light from a 250 W quartz tungsten halogen lamp (Cuda Fiberoptics, Jacksonville, FL) and collect tissue reflectance, consisted of a 400 μm -diameter source fiber and 10 co-linear 400 μm -diameter detection fibers at various source-detector separation distances. A spectrograph (Model# SpectraPro-150, Acton Research, Acton, MA), and a liquid nitrogen cooled CCD camera (Model# LN/CCD-1100-PF/UV, Roper Scientific, Trenton, NJ) imaged the reflectance spectra from multiple detection fibers simultaneously. Source-detector separation distances ranged between 1.2 mm and 5 mm. The tissue sampling depth was approximately one-third to one-half of the source-detector separation distance, i.e., ~ 0.4 to 2.5 mm, for tissue samples in these studies. One measurement was taken from each organ of each animal at one time point (before or after PDT). Measurements were taken from normal organs including small bowel, rectum, peritoneum, and skin.

Data inversion used a multi-wavelength algorithm based on the diffusion equation with the constraint that the reduced scattering coefficient, $\mu_s' = A\lambda^{-B}$, and the tissue absorption coefficient, $\mu_a = \sum c_i \epsilon_i(\lambda)$. Here λ is the wavelength; A and B are related to the scattering agent size, index of refraction, and concentration; c_i and ϵ_i are the concentration and extinction coefficient of the i^{th} chromophore, respectively. Primary tissue chromophores were oxyhemoglobin (HbO₂), deoxyhemoglobin (Hb), and water. The extinction coefficients of HbO₂, Hb, and water were obtained from the literature. Optical properties spectra. Internet address: <http://omlc.ogi.edu/spectra/index.html>. The extinction coefficient of MLu was measured by us using an absorption spectrometer (Ocean Optics, Dunedin, FL).

The diffuse reflectance algorithm fit data from all wavelengths simultaneously to well studied analytical solutions for semi-infinite turbid media. From these fits it was possible to extract A, B, c_{MLu} , c_{water} , c_{HbO_2} , and c_{Hb} . The tissue optical properties, $\mu_s'(\lambda)$, $\mu_a(\lambda)$, and the effective attenuation coefficient, μ_{eff} (or light penetration depth $\delta = 1/\mu_{\text{eff}}$), were calculated from the former parameters using the mathematical relationships described above at the treatment wavelength of 730 nm.

The peritoneal surface of the pelvis and top of the rectal stump

TABLE 2

The Mean and Standard Deviation of Tissue Optical Properties Including Reduced Scattering (μ_s'), Absorption (μ_a) Coefficients and Penetration Depth (δ) of 730 nm Light Before and After Photodynamic Therapy

	Before PDT ($n = 4$)			After PDT ($n = 4$)		
Treatment dogs	μ_s' (cm^{-1}) @730 nm	μ_a (cm^{-1}) @730 nm	δ (cm) @730 nm	μ_s' (cm^{-1}) @730 nm	μ_a (cm^{-1}) @730 nm	δ (cm) @730 nm
Small bowel	10.64 \pm 3.64	0.22 \pm 0.09	0.415 \pm 0.139	10.02 \pm 2.62	0.14 \pm 0.04	0.510 \pm 0.120
Rectum	8.29 \pm 3.60	0.20 \pm 0.05	0.485 \pm 0.125	12.58 \pm 4.51	0.16 \pm 0.02	0.428 \pm 0.082
Peritoneum	14.63 \pm 6.02	0.09 \pm 0.09	0.717 \pm 0.360	9.51 \pm 2.26	0.09 \pm 0.02	0.657 \pm 0.149
Skin	25.36 \pm 10.46	0.15 \pm 0.04	0.313 \pm 0.036	16.74 \pm 7.01	0.14 \pm 0.02	0.417 \pm 0.175
	Before PDT ($n = 3$)			After PDT ($n = 3$)		
Control dogs						
Small bowel	8.85 \pm 1.95	0.07 \pm 0.02	0.732 \pm 0.069	8.32 \pm 1.73	0.11 \pm 0.02	0.613 \pm 0.068
Rectum	12.37 \pm 11.6	0.07 \pm 0.03	0.860 \pm 0.452	6.29 \pm 1.91	0.08 \pm 0.03	0.974 \pm 0.441
Peritoneum	9.43 \pm 5.47	0.04 \pm 0.03	1.194 \pm 0.601	8.46 \pm 0.74	0.09 \pm 0.03	0.983 \pm 0.530 cm
Skin	9.20 \pm 2.28	0.04 \pm 0.02	1.111 \pm 0.525	25.62 \pm 6.77	0.07 \pm 0.03	0.525 \pm 0.142 cm

was illuminated with 732 nm light. The rectal resection site and surrounding pelvis was treated with a flat cut optical fiber emitting a circular beam of light.

Eye protection in the form of goggles was worn by all operating room personnel. After the administration of light, the detectors were removed from the abdomen and passed from the surgical table before completing the surgical anastomosis and abdominal closure. Optical properties of the tissues were measured again after treatment.

Preparation of Pathology Samples

The tissue samples obtained at necropsy were fixed and stored in a 10% buffered formalin solution until processing. Trimmed tissues were embedded in paraffin, sectioned and stained.

Review of Pathology Specimens

All specimens were examined with light microscopy by a board-certified veterinary pathologist who was blinded to the treatment groups. MLu was extracted from the biopsies using a procedure based on a previous report [12]. Frozen tissue samples were thawed to room temperature, weighed and, depending on the amount available, divided into 2 to 3 replicates of ~10 or 50 mg each. Specimens of 10 or 50 mg were homogenized (Polytron 1200) in 400 or 1000 μl of phosphate buffer (24 mM, pH 7.5), respectively. Homogenates were mixed with an equal volume of chloroform, then 400 μl (10 mg samples) or 1000 μl (50 mg samples) of methanol was added. Following centrifugation (3500 rpm, 15 min) the organic layer was collected and 200 μl (10 mg samples) or 600 μl (50 mg samples) was transferred to a cuvette. The fluorescence of the homogenized sample was measured by a spectrofluorometer (FluoroMax-3, Jobin Yvon, Inc., Edison, NJ) with λ_{ex} of 474 nm and λ_{em} of 740 nm (emission scan range from 650 to 850 nm). MLu concentration in the tissue was calculated based on the increase in fluorescence resulting from the addition of a known amount of MLu to each sample after its initial reading. Data are presented as ng of MLu per mg of tissue.

RESULTS

Clinical Findings

All of the dogs tolerated surgery and PDT treatment without major acute or late clinical effects (Table 1). The post-operative course was similar for both control and PDT-treated animals. Nine of the 10 dogs were eating 1 d post-operatively with a normal appetite; one dog

had a decreased appetite for 3 days post-operatively. No dog suffered an anastomotic leak. One dog suffered a self-induced small abdominal dehiscence. The dehiscence was repaired by resecting the protruding omentum and closing the skin with surgical staples. This dog healed without complication.

Tissue Penetration and Physiological Properties

The tissue penetration depth of 730 nm light for small bowel, rectum, pelvic peritoneum, and skin was determined (Table 2) both before and after PDT by calculating μ_{eff} from the reduced scattering (μ_s') and absorption coefficients (μ_a), measured as described in the Materials and Methods Section. The optical properties were similar before and after PDT. In MLu-treated dogs, the average tissue penetration depths at 730 nm before and after PDT were 0.46 \pm 0.18 cm for rectum, 0.46 \pm 0.15 cm for small bowel, 0.69 \pm 0.39 cm for peritoneum, and 0.31 \pm 0.04 cm for skin. For control animals without photosensitizer injection, the optical penetration depths were longer: 0.92 \pm 0.63, 0.67 \pm 0.10, 1.1 \pm 0.80, and 0.82 \pm 0.54 cm for rectum, small bowel, peritoneum, and skin, respectively. These data suggest that the presence of MLu within tissues affects light penetration.

We were also able to obtain tissue physiological properties of MLu-treated and control animals including total hemoglobin concentration ($\text{THC} = c_{\text{HbO}_2} + c_{\text{Hb}}$) and oxygen saturation ($\text{SO}_2 = c_{\text{HbO}_2}/\text{THC}$) from diffuse reflectance spectroscopy (Table 3). There was no significant difference in tissue physiological properties before *versus* after PDT and MLu treated *versus* control animals. There was a broad range of THC and SO_2 among various organs (small bowel, rectum, peritoneum, and skin) from animal to animal in the treated and control groups, before or after PDT. For example, before PDT in treated animals, SO_2 and THC ranged between 62 to 85% and 101 to 303 μM in small bowel, 37 to 88% and

TABLE 3

The Mean and Standard Deviation of Tissue Physiological Properties, Total Hemoglobin Concentration (THC) and Oxygen Saturation (SO₂), Before and After Photodynamic Therapy by Diffuse Reflectance Spectroscopy

	Before PDT		After PDT	
Treatment dogs	THC (μM) ($n = 4$)	SO ₂ (%) ($n = 4$)	THC (μM) ($n = 4$)	SO ₂ (%) ($n = 4$)
Small bowel	177.3 \pm 87.7	72.5 \pm 9.7	106.8 \pm 34.2	43.3 \pm 23.4
Rectum	100.2 \pm 35.4	68.5 \pm 24.0	123.4 \pm 63.7	78.4 \pm 4.7
Peritoneum	116.2 \pm 131.0	88.3 \pm 10.7	123.0 \pm 92.6	83.6 \pm 15.6
Skin	118.2 \pm 75.1	50.1 \pm 26.2	102.3 \pm 79.4	62.5 \pm 32.5
Control dogs	THC (μM) ($n = 3$)	SO ₂ (%) ($n = 3$)	THC (μM) ($n = 3$)	SO ₂ (%) ($n = 3$)
Small bowel	108.4 \pm 22.3	60.2 \pm 5.4	157.9 \pm 89.7	66.6 \pm 19.3
Rectum	145.0 \pm 50.9	93.9 \pm 8.7	177.8 \pm 114.9	99.2 \pm 1.4
Peritoneum	70.5 \pm 72.2	97.4 \pm 3.7	120.7 \pm 158.8	74.7 \pm 22.3
Skin	81.6 \pm 63.5	89.1 \pm 15.3	136.5 \pm 144.8	97.6 \pm 3.4

61 to 138 μM in rectum, 75 to 97% and 36 to 311 μM in peritoneum, and 21 to 75% and 44 to 217 μM in skin, respectively. Because we only sampled one site in each organ of each animal before or after PDT, this broad range of tissue physiological properties was possibly because of tissue heterogeneity that we also have found in human intraperitoneal tissues [16].

Histological Findings

All of the anastomotic sites healed normally. No animal revealed any gross organ damage, regardless of their treatment. Mild lymphocytic enteritis was revealed for all animals undergoing laparotomy.

MLu Tissue Concentration

Non-invasive, optical measurements of MLu tissue concentrations shown in Table 4, demonstrate that the skin had an uptake of 1.89 ± 1.51 ng/mg of MLu and the rectum had an uptake of 4.45 ± 1.35 ng/mg of MLu before light delivery in PDT-treated animals. Small bowel had similar drug uptake to rectum, 3.97 ± 2.20 ng/mg. Peritoneum has the least uptake, 0.93 ± 1.01 ng/mg.

TABLE 4

The Mean and Standard Deviation of MLu Concentration (ng/mg) Before and After Photodynamic Therapy by Reflectance Spectroscopy

	Before PDT	After PDT
Treatment dogs	MLu (ng/mg) ($n = 4$)	MLu (ng/mg) ($n = 4$)
Small bowel	3.97 \pm 2.20	2.15 \pm 1.69
Rectum	4.45 \pm 1.35	2.55 \pm 0.58
Peritoneum	0.93 \pm 1.01	0.88 \pm 1.03
Skin	1.89 \pm 1.51	2.46 \pm 1.71
Control dogs	MLu (ng/mg) ($n = 3$)	MLu (ng/mg) ($n = 3$)
Small bowel	0.00 \pm 0.00	0.03 \pm 0.06
Rectum	0.00 \pm 0.00	0.00 \pm 0.00
Peritoneum	0.00 \pm 0.00	0.75 \pm 1.30
Skin	0.00 \pm 0.00	0.00 \pm 0.00

Table 5 shows the concentration of MLu measured by spectrofluorometric assay after tissue homogenization of biopsies of skin, liver, and rectum from control and photosensitized animals. Control animals demonstrated no significant levels of drug uptake, as was expected. Photosensitized animals demonstrated the highest levels of drug uptake in the liver (6.55 ± 1.95 ng/mg). Lower levels were found in skin and rectum, with skin exhibiting approximately twice (1.87 ± 0.38 ng/mg) the level of drug as found in the rectum (0.72 ± 0.23 ng/mg).

MLu uptake from optical measurements performed by reflectance spectroscopy was compared to the results obtained in *ex vivo* histological samples by spectrofluorometric assay. Figure 1 shows the results of this comparison in the same animals for both skin and rectum. The data show a close to one-to-one correlation between two methods in skin (slope = 1.06, $R^2 = 0.44$), but a seven-to-one correlation in rectum (slope = 7.28, $R^2 = 0.69$) with the optical methods detecting higher levels of drug uptake.

DISCUSSION

This study revealed low anterior rectal resection and anastomosis to be safe in a canine model in which

TABLE 5

Spectrofluorometric Assessment of MLu Concentration (ng/mg) in Biopsy Samples

	Control Dogs		Treatment Dogs	
	Range (ng/mg)	Avg. \pm SD (ng/mg)	Range (ng/mg)	Avg. \pm SD (ng/mg)
Rectum	ND*–0.02	0.01 \pm 0.01	0.42–1.01	0.72 \pm 0.23
Liver	ND	—	4.33–10.05	6.55 \pm 1.95
Skin	ND–0.11	0.04 \pm 0.06	1.70–2.39	1.87 \pm 0.38

* ND = not detectable, average includes only those samples in which drug was detected.

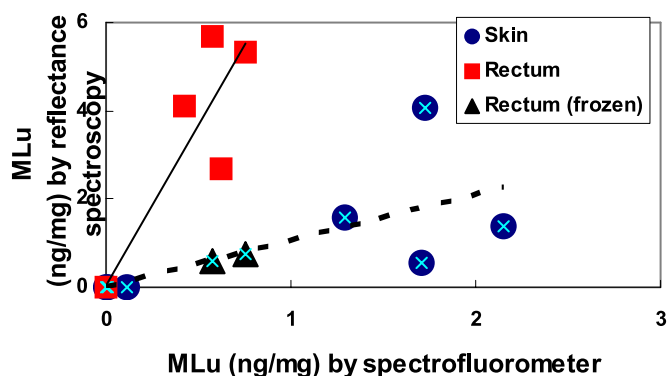


FIG. 1. In seven dogs, MLu concentration (ng/mg) in skin (●, $n = 7$) and rectum (■, $n = 5$) measured by broadband diffuse reflectance spectroscopy versus the concentration measured by spectrofluorometer is plotted. The measurements by reflectance spectroscopy in rectum show higher MLu uptake (slope = 7.28, $R^2 = 0.69$) than those by spectrofluorometer in part because of different sampling depths and MLu content inside blood vessels. Two frozen rectum tissues from two animals were measured by reflectance spectroscopy and plotted (▲). The results from both skin and frozen rectum tissues show one-to-one correlation measured by two methods with slope = 1.06 and $R^2 = 0.43$. (Color version of figure is available online.)

MLu-mediated PDT was administered after resection. We attempted to create a model which would approximate, as closely as possible, low anterior resection in the human clinical situation. Such a safety study was required, because we envision using photodynamic therapy in conjunction with neoadjuvant chemoradiation and total mesorectal resection in an effort to minimize local recurrence. Our study revealed that canines have the ability to heal a rectal anastomosis after MLu-mediated PDT of the pelvis and the proximal end of the transected distal rectum.

One of the major toxicities reported for Photofrin-mediated intraperitoneal PDT has been bowel toxicity including perforation [10]. Given the disadvantages of Photofrin as a sensitizer for PDT, an investigation of other drugs was warranted. MLu is activated by 730 nm light that has substantially greater tissue penetration compared to the 630 nm light used for Photofrin activation. We raised the question, therefore, whether the greater light penetration at 730 nm would increase the risk of bowel toxicity from abdominal or pelvic PDT especially in the setting of a bowel resection. Histological tissue damage was not evident in our experiment. This finding is similar to a previous report by our group of MLu-mediated intraperitoneal PDT in a canine model [17].

There is increasing experimental and clinical evidence that PDT may prove effective in the treatment of colon and rectal cancer. Animal experimentation has revealed the ability to eradicate induced colon cancers as well as human colon cancers grown in the nude mouse. Barr *et al.* used an induced colon cancer in a rat model and found photosensitizer concentrations to be twice as high in colon tumor tissue as in surrounding

normal colon [18]. Tumors were treated by creating a colotomy adjacent to palpable tumor and then illuminating the tumor and normal tissue with laser light. Histological evaluation at various post-operative time points revealed necrosis and often complete eradication of tumor. The maximum depth of necrosis was a few millimeters.

Haddad *et al.* impacted the effect of PDT on CT26 colon carcinoma cells *in vitro* and *in vivo* [19]. Flank tumors were created by subcutaneous injection of CT26 cells in Balb/C mice that underwent PDT 24 h later. Photodynamic therapy induced tumor necrosis and prolonged animal survival. Similarly, Whitacre *et al.* were able to induce tumor regression of SW480 colon cancer xenografts in athymic nude mice using PDT based on the silicon phthalocyanine photosensitizer Pc4 [20].

There has also been clinical application of photodynamic therapy to colon and rectal cancer. In 1995 a prospective feasibility study using Photofrin II (Quadra Logic Inc., Vancouver, Canada) based PDT with intra-operative illumination of the pelvis was performed on seven patients undergoing resection of recurrent rectal cancer. Patients tolerated pelvic illumination without major morbidity. Direct impact on tumor was not evaluated [21].

In 1996, Kashtan *et al.* treated a 70 years old woman with locally recurrent rectal cancer with Photofrin II based PDT [22]. Forty-eight and 96 h after i.v. injection of 2 mg/kg of Photofrin II, the patient was subjected to direct photo radiation with a light dose of 200 Joules/cm². After the first light session, complete macroscopic disappearance of tumor was observed with a necrotic area at the tumor site. Biopsies taken from margins of the tumor site up to 10 weeks after treatment showed no evidence of malignancy and a healed wound. Sixteen weeks later, random biopsy from the previous tumor site showed carcinoma cells.

In 1997, Milkvy *et al.* treated five patients with colonic adenocarcinoma and three with adenomas [23]. Each patient was deemed unsuitable for surgery because of co-morbid disease. Illumination of tumor was facilitated through fibers introduced through the biopsy channel of an endoscope. Although different photosensitizers were used and the tumor characteristics were not clearly defined, histological evidence of necrosis of 8 mm in depth was noted. Patients tolerated therapy well.

Nakamura *et al.* in 2003 described the complete resolution of rectal cancer in two patients with hematoporphyrin derivative photosensitizer based PDT after polypectomy [24].

Specifically, each patient had a rectal cancer at 5 cm from the anal verge that invaded into the muscularis propria. The volume of each tumor was reduced by endoscopic polypectomy. One week later hematoporphyrin derivative was administered (2.5 mg/kg). At 48 and 72 h

later, the remaining portions of the cancerous lesion were treated with 627.8 nm light by means of a single quartz fiber passed through an endoscope. One patient died of renal failure 25 months after treatment without any recurrence. The second patient remains disease free 6 years after treatment.

If photodynamic therapy is to be applied as an adjunct to curative resection and primary anastomosis, then it is incumbent to prove the safety of rectal anastomosis after illumination of the proximal portion of the residual distal rectum. It is well known that the anastomotic leak rate after low anterior resection is higher than anastomoses created proximal to the rectum. Even in the most experienced hands, the anastomotic leak rate after total mesorectal excision approaches 11% [25]. Although colonic anastomosis bursting strength in mice was found not to be altered by PDT [26], we believed a more clinically relevant model was needed before human application.

An additional issue we investigated was the depth of tissue penetration. Clinical application will demand knowledge of the effective depth of penetration of laser light in a clinically relevant model. The depth of induced tissue necrosis in a patient treated with PDT is determined by a number of factors including the delivered light dose, the concentration of photosensitizer in the illuminated tissues, tissue oxygen levels, and the optical properties of the tissue. The light penetration measurements that we performed in this study show that 730 nm light penetration after PDT was 7 mm into the rectal side wall and 4 mm into the top of the transected distal rectum. Measurement of tissue penetration of 730 nm light before PDT represents the most conservative depth estimate that would be delivered in the clinical setting. Our study reveals that it may be possible to generate tumor kill of malignant cells located within 5 mm of the illuminated pelvic surfaces.

Penetration depth of light in the tissues of the treatment group before PDT was decreased compared to the control dogs because of light absorption by the photosensitizer. Post-PDT this penetration depth increased most likely because of photobleaching of the photosensitizer during treatment. There was a decrease in light absorption in bowel but not peritoneum or skin potentially because of the preferential treatment of this area with light. Photobleaching was present even when light doses were low, 0.5 J/cm^2 .

MLu concentrations in the tissues were measured both by measuring the optical properties and by spectrofluorometric evaluation of the tissue samples. The resulting values for levels in the skin were consistent from dog to dog and by both methods, showing an MLu uptake of 1.87 ± 0.38 by *ex vivo* spectrofluorometer versus 1.89 ± 1.51 ng/mg by *in vivo* reflectance spectroscopy. Levels of MLu in the colon measured by spec-

trofluorometric methods showed that the colon had drug levels of 0.72 ng/mg, where as by measuring the optical properties of the tissues, drug levels were 4.45 ± 1.35 ng/mg. The same trend that rectum shows higher uptake *in vivo* than *ex vivo* is shown in the correlation plot of *in vivo* reflectance spectroscopy versus *ex vivo* spectrofluorometer measurements performed on the same animal in Fig. 1. The slope of the correlation between measurements by these two methods is higher in rectum (slope = 7.28, $R^2 = 0.69$) than the slope of the correlation in skin (slope = 1.06, $R^2 = 0.44$). The difference may be a result of the fact that the sample depths were different. In measuring the optical properties of the tissues, the data were obtained from detection fibers with source-detection separation distances of up to 5 mm from the surface indicating that the sample depth was approximately 1.7 to 2.5 mm accounting for muscle, submucosa, mucosal layers of the colon, and possibly the partial food contents containing MLu inside the lumen. In obtaining the fluorometric measurements, only the muscle layer was used. The other possible cause may be because of sampling of MLu from the circulating blood by reflectance spectroscopy measurement *in vivo*. To distinguish between these possibilities, we performed the reflectance spectroscopy measurements on the frozen rectum tissue from two animals. The results were plotted in Fig. 1. The two data points do not alter the slope nor the R^2 value of the correlation line including data from skin tissue only (slope = 1.06, $R^2 = 0.43$).

This study, in conjunction with the clinical results of intraperitoneal PDT, establishes the groundwork for further study of PDT for rectal cancer in humans. Light delivery in the treatment of carcinomatosis with intraperitoneal PDT is challenging because of the large, irregular surface that is required to be treated [27]. The fixed, well-defined structure of the pelvis lends itself well to the application of PDT. Based upon this work, we plan to pursue a human trial to decrease local recurrence in the pelvis after neoadjuvant therapy and total mesorectal excision in patients at high risk for local failure. Further, we envision a role for endoluminal PDT as an adjunct to local excision of superficial distal rectal tumors treated by trans-anal excision.

REFERENCES

1. Mellgren A, Sirivongs P, Rothenberger DA, Madoff RD, Garcia-Aguilar J. Is local excision adequate therapy for early rectal cancer? *Dis Colon Rectum* 2000;43:1064.
2. Enker WE, Merchant N, Cohen AM, et al. Safety and efficacy of low anterior resection for rectal cancer: 681 consecutive cases from a specialty service. *Ann Surg* 1999;230:544.
3. Merchant NB, Guillem JG, Paty PB, et al. T3N0 rectal cancer: Results following sharp mesorectal excision and no adjuvant therapy. *J Gastrointestinal Surg* 1999;3:642.
4. Dougherty TJ, Gomer CJ, Henderson BW, et al. Photodynamic therapy. [Review]. *J Nat Cancer Instit* 1998;90:889.

5. Bauer TW, Hahn SM, Spitz FR, Kachur A, Glatstein E, Fraker DL. Preliminary report of photodynamic therapy for intraperitoneal sarcomatosis. *Ann Surg Oncol* 2001;8:254.
6. Friedberg JS, Mick R, Stevenson J, et al. A phase I study of Foscan-mediated photodynamic therapy and surgery in patients with mesothelioma. *Ann Thorac Surg* 2003;75:952.
7. Litle VR, Christie NA, Fernando HC, Buenaventura PO, Ferson PF, Luketich JD. Photodynamic therapy for endobronchial metastases from nonbronchogenic primaries. *Ann Thorac Surg* 2003;76:370.
8. Sanfilippo NJ, Hsi A, DeNittis AS, et al. Toxicity of photodynamic therapy after combined external beam radiotherapy and intraluminal brachytherapy for carcinoma of the upper aerodigestive tract. *Lasers Surg Med* 2001;28:278.
9. Nathan TR, Whitelaw DE, Chang SC, et al. Photodynamic therapy for prostate cancer recurrence after radiotherapy: A phase I study. *J Urol* 2002;168(Pt 1):1427.
10. Hahn S, Glatstein E. The emergence of photodynamic therapy as a major modality in cancer treatment. *Rev Contemp Pharmacother* 1999;10:69.
11. Delaney TF, Sindelar WF, Tochner Z, et al. Phase 1 study of debulking surgery and photodynamic therapy for disseminated intraperitoneal malignancies. *Int J Radiol Biol Physics* 1993;25:445.
12. Woodburn KW, Fan Q, Kessel D, Luo Y, Young SW. Photodynamic therapy of B16F10 murine melanoma with lutetium texaphyrin. *J Invest Dermatol* 1998;110:746.
13. Mody TD, Fu L, Sessler JL. Texaphyrins: Synthesis and development of a novel class of therapeutic agents. In: Karlin KD, ed. *Progress in Inorganic Chemistry*. Chichester: John Wiley & Sons, Ltd., 2001:551–598.
14. Young SW, Woodburn K, Wright M, et al. Lutetium texaphyrin (PCI-0123): A near-infrared water soluble photosensitizer. *Photochem Photobiol* 1996;63:892.
15. Solonenko M, Cheung R, Busch TM, et al. In vivo reflectance measurement of optical properties, blood oxygenation and motexafin lutetium uptake in canine large bowels, kidneys and prostates. *Phys Med Biol* 2002;47:857.
16. Wang HW, Zhu TC, Putt ME, et al. Broadband reflectance measurements of light penetration, blood oxygenation, hemoglobin concentration, and drug concentration in human intraperitoneal tissues before and after photodynamic therapy. *J Biomedical Optics* 2005;10:14004.
17. Griffin GM, Zhu T, Solonenko M, et al. Preclinical evaluation of Motexafin Lutetium-mediated intraperitoneal photodynamic therapy in a canine model. *Clin Cancer Res* 2001;7:374.
18. Barr H, Chatlani P, Tralau CJ, MacRobert AJ, Boulos PB, Bown SG. Local eradication of rat colon cancer with photodynamic therapy: Correlation of distribution of photosensitizer with biological effects in normal and tumour tissue. *Gut* 1991;32:517.
19. Haddad R, Kaplan O, Greenberg R, Siegal A, Skornick Y, Kashatan H. Photodynamic therapy of murine colon cancer and melanoma using systemic aminolevulinic acid as a photosensitizer. I. *J Surg Invest* 2000;2:171.
20. Whitacre CM, Feyes DK, Satoh T, et al. Photodynamic therapy with the phthalocyanine photosensitizer Pc 4 of SW480 Human Colon Cancer xenografts in athymic mice. *Clin Cancer Res* 2000;6:2021.
21. Harlow SP, Rodriguez-Bigas M, Mang T, Petrelli N. Intraoperative photodynamic therapy as an adjunct to surgery for recurrent rectal cancer. *Ann Surg Oncol* 1995;2:228.
22. Kashtan H, Haddad R, Yossiphov Y, Bar-on S, Skornick Y. Photodynamic therapy of colorectal cancer using a new light source. *Dis Colon Rectum* 1996;39:379.
23. Mlkvy P, Messmann H, Regula J, et al. Photodynamic therapy for gastrointestinal tumors using three photosensitizers-ALA induced PPIX, Photofrin and MTHPC. A pilot study. *Neoplasms* 1998;45:157.
24. Nakamura T, Fukui H, Ishii Y, Ejiri K, Ejiri M. Photodynamic therapy with polypectomy for rectal cancer. *Gastrointest Endosc* 2003;57:266.
25. Heald RJ, Moran BJ, Ryall RDH, Sexton R, MacFarlane JK. Rectal cancer. The Basingstoke Experience of total mesorectal excision, 1978–1997. *Arch Surg* 1998;133:894.
26. Haddad R, Kaplan O, Brazowski E, et al. Effect of photodynamic therapy on normal fibroblasts and colon anastomotic healing in mice. *J Gastrointest Surg* 1999;3:602.
27. Wilson JJ, Jones H, Burock M, et al. Patterns of recurrence in patients treated with photodynamic therapy for intraperitoneal carcinomatosis and sarcomatosis. *Int J Oncol* 2004;24:711.